

Closure of residual leakage after the use of hybrid umbrella in umbrella technique: A case report

 Mingxian Chen,  Jianjun Tang,  Zhenfei Fang,  Xiangqian Shen,  Shenghua Zhou
Department of Cardiology, The Second Xiangya Hospital of Central South University; Changsha-*China*

Introduction

Patent ductus arteriosus (PDA) is a common congenital heart defect. Some adults with PDA are often associated with severe pulmonary hypertension and frequently have to forgo their chance of surgery because the lung conditions progress to Eisenmenger syndrome (1). Therefore, early treatment should be performed as soon as a diagnosis of PDA is established. Several methods, including surgical ligation and transcatheter occlusion, have been currently employed for the treatment of PDA. However, surgical ligation has major disadvantages, such as significant trauma and other complications associated with thoracotomy. Transcatheter occlusion must be carried out under fluoroscopy and angiography, which causes inevitable radiation injury. Furthermore, closure of a large-sized PDA defect is technically challenging and carries a risk of device embolization (2, 3).

The hybrid technique combines the advantages of open heart surgery and interventional cardiac catheterization. It is carried out by performing intraoperative transesophageal echocardiography-guided transthoracic occlusion via a small incision in the left portion of the chest close to the ductus arteriosus (4, 5). However, despite the high accuracy of the technique, residual PDA leakage remains a common complication after hybrid flap closure. This leakage may be the result of malposition of the occluding device or improper choice of device under the guidance of transesophageal echocardiography. Previous reports have documented the successful application of coil-type occlusion to manage residual leakage after the transcatheter occlusion of PDA (6). However, reports on the effectiveness of the umbrella-type occlusion are scanty. Herein, we present our successful closure of residual PDA leakage with a second umbrella, called the “umbrella in umbrella” technique.

Case Report

A 48-year-old female had been diagnosed with PDA and had undergone hybrid closure of PDA with HeartR™ Amplatzer septal occluder (38 mm) 2 years ago. She presented to our hospital with a complaint of progressive dyspnea on exertion. Transthoracic

echocardiography examination revealed an occluding device in the large PDA with left to right residual leakage (diameter of the defect=6 mm) and device-related stenosis of the descending aortic artery (the gradient formed by the descending aorta diameter and the stenosis diameter=11–20 mm). The diameter of the ascending aorta was 32 mm. The values obtained from transthoracic echocardiography were: left atrial (LA)=46 mm, left ventricular (LV)=63 mm, right atrial (RA)=53 mm, right ventricular (RV)=50 mm, and mean pulmonary artery pressure (PAP)=47 mm Hg.

On admission, her vital stats were as follows: blood pressure=95/53 mm Hg, heart rate=90 beats/minute, respiratory rate=normal, and body temperature=37 °C. She did not complain of productive or dry cough, fever, and nocturnal dyspnea or orthopnea. Atrial fibrillation and left ventricular hypertrophy were documented by resting electrocardiography. The chest X-ray showed cardiomegaly (cardiothoracic ratio=0.78), a prominent pulmonary artery, and a double border along the right heart.

Significant hyperactive precordium was documented and the apex beat was displaced to the 6th intercostal space extending to the anterior axillary line. Heart sounds were recorded as S₁S₂S₃ with a gallop rhythm, and a grade 3/6 continuous murmur was heard most prominently at the 2nd intercostal space. There were no pulmonary rales or wheezing in both lungs. There was no sign of feet edema.

Procedure

The case was thoroughly discussed within the cardiac team and it was decided that it would be challenging for the surgeon to withdraw the primary device by opening the chest. Therefore, a second percutaneous closure of the leakage was planned after the application of the HeartR™ Amplatzer septal occluder as part of the initial PDA closure. The procedure was performed under local anesthesia. Access to the right femoral vein was established by the placement of a 6-F sheath, and the same was done for the right femoral artery. A dose of heparin (100 U/kg) was administered.

To facilitate a more accurate evaluation, the patient was recommended to undergo right cardiac catheterization before the leakage was occluded. Aortic pressure was measured with a 5-F pigtail catheter from the ascending to the descending aorta. An angiogram with the 5-F pigtail catheter in the proximal descending aorta was performed to calcify the PDA leakage and classify its shape (Fig. 1). An Amplatzer septal occluder and an obvious PDA (the diameter of smallest stenosis=17 mm) connecting the proximal portion of the descending aorta to the left portion of the pulmonary artery were visualized. The diameter gradient between the normal distal descending aorta and the smallest device-related stenosis of the descending aorta ranged from 12 to 25 mm (Video 1). After short discussion within the interventional team, the “umbrella in umbrella” technique was decided upon as the treatment plan for leakage closure.

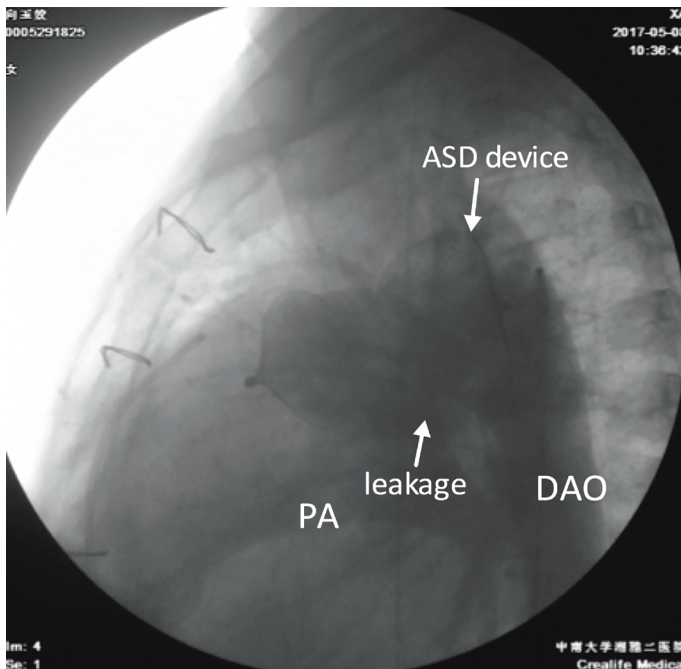


Figure 1. Descending aortic angiogram. It shows the descending aortic angiogram demonstrating a 17 mm diameter of the ductus arteriosus, a gourd-shaped Amplatzer septal occluder, and a residual leakage

A 6-F JR 4.0 catheter was delivered through the right femoral artery sheath to the descending aortic side of the Amplatzer septal occluder. The soft tip of the ultra-smooth guide wire was successfully placed on the aortic side and the waist of the Amplatzer septal occluder, but could not cross over to the pulmonary side of the occluder. A 5-F Cobra catheter was passed over the guide wire into the occluder waist. Following the withdrawal of the guide wire and placement of the hard tip of the guiding catheter into the occluder waist, the hard tip was successfully passed over to the pulmonary side of the Amplatzer septal occluder (Video 2). Then, following the withdrawal of the guide wire, the soft tip of

the guiding catheter was introduced to the pulmonary artery. A 6-F MP catheter was delivered into the pulmonary artery with the catcher inside. The catcher successfully caught the soft tip of the guide wire and retracted it out of the femoral vein. The JR4.0 guide catheter was then placed with its tip inside the pulmonary artery. A 7-F long sheath was passed over the wire from the right femoral vein into the occluder waist. The long sheath was retracted and an 8-F long sheath was placed into the occluder waist (Fig. 2).

The selection of the implant device was based on the morphology and diameter of the PDA. The appropriate-sized device (diameter=16–18 mm) was then screwed onto the delivery cable and pulled into the loader under water to prevent air entry into the device or the sheath. The device was then advanced toward the tip of the sheath in the descending aorta without rotating the cable. The sheath and device were then pulled back into a position just distal to the ampulla (Video 3). The position of the device was confirmed with repeated angiograms in the descending aorta and adjusted until the retention skirt was well-seated in the ampulla (Video 4).

When a satisfactory position was achieved, the sheath was retracted and the tubular part of the device was opened within the PDA (Fig. 3). Aortic angiography was performed at the end of the procedure and no leakage was visible. The patient was discharged on the second day following the procedure. Physical examination and echocardiography were performed at 24 hours, 1 month, 3 months, 1 year, and 2 years after the placement of the device (Video 5). No residual leakage was found during the follow-up period. The whole procedure of catheter closure is shown in a schematic depiction (Fig. 4).

Discussion

PDA can easily develop into pulmonary hypertension and gradually progress to Eisenmenger syndrome. Therefore, early

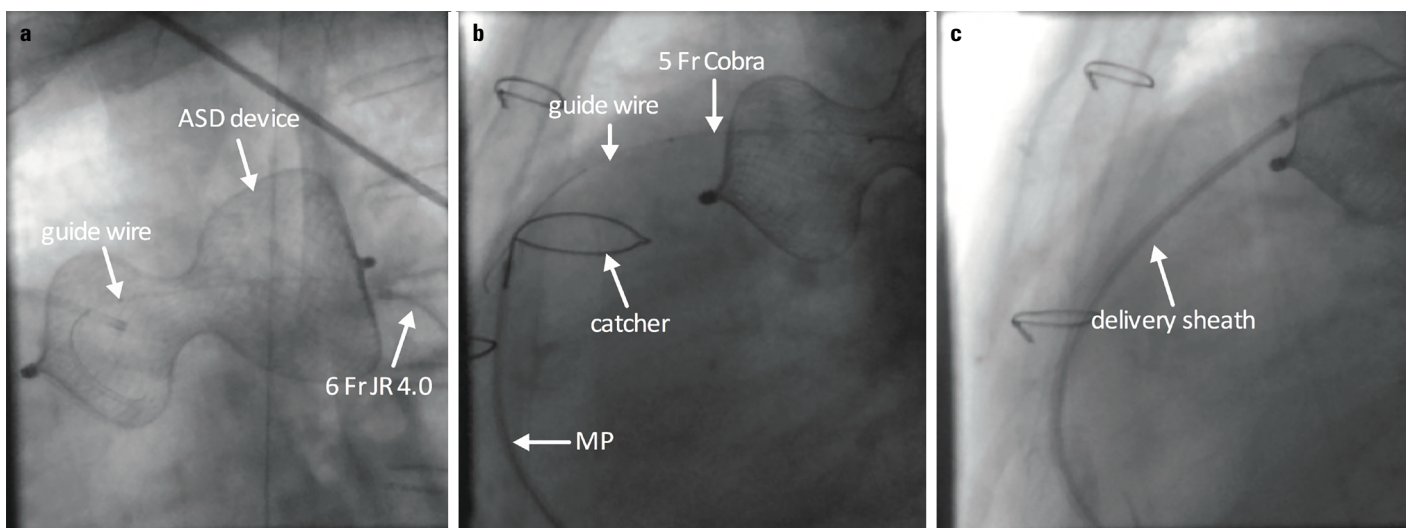


Figure 2. The procedure of interventional catheter closure. (a) It shows the Cobra catheter arranged in a JR4.0 guide wire and the penetration of the guide wire in the occlude waist. (b) It shows the process of venoarterial loop construction. (c) It represents the expansion of different sheath size

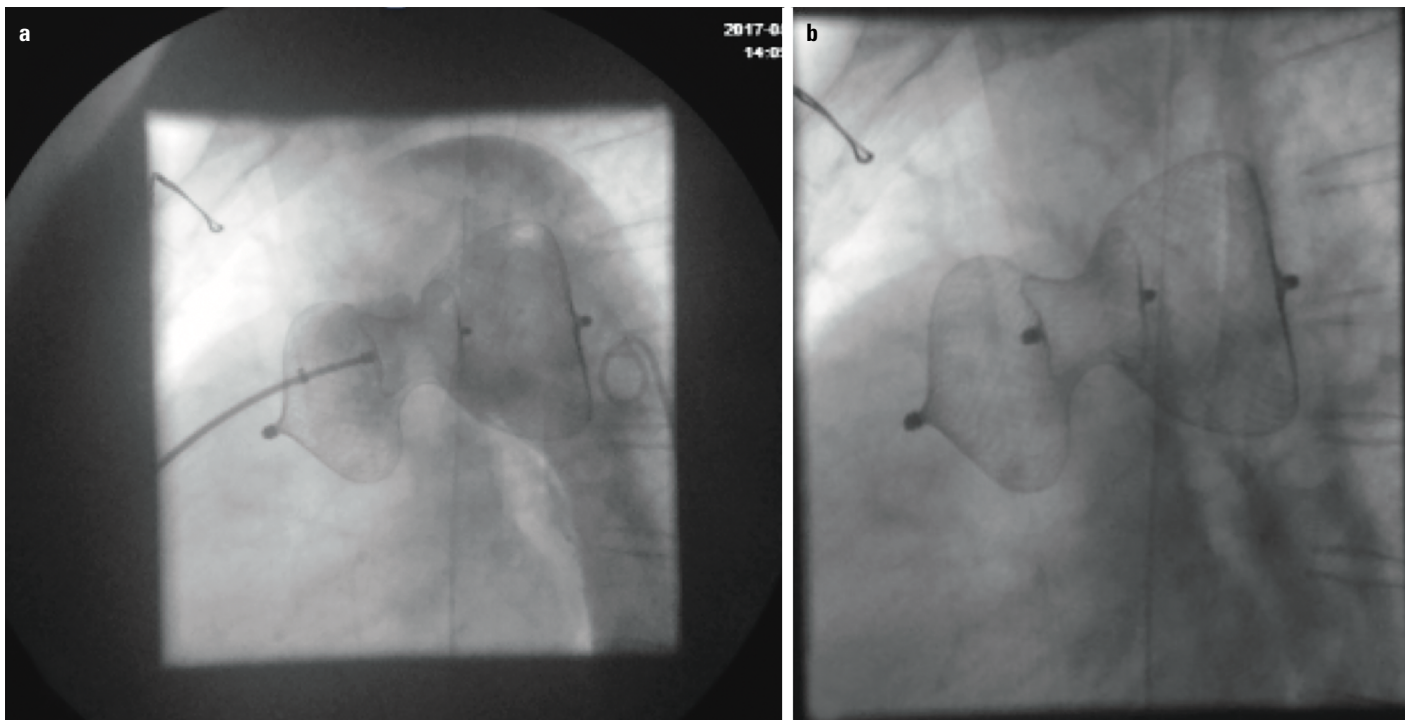


Figure 3. Aortic angiogram and the release of the PDA device. (a) Aortic angiogram shows no residual flow. (b) It represents an “umbrella in umbrella” shape

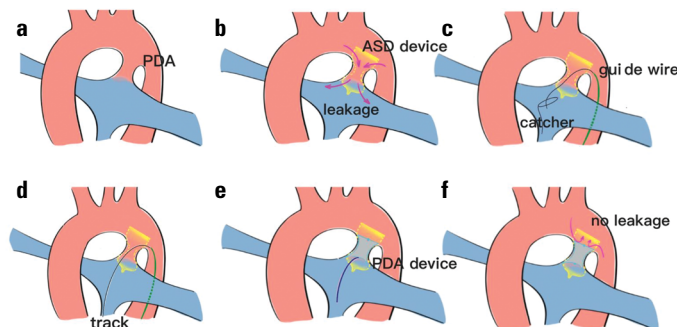


Figure 4. Schematic interventional catheter closure in umbrella in umbrella technique. (a) A normal fetal artery connecting the aorta and pulmonary artery. The ductus allows blood to flow freely from the aorta to the pulmonary artery. (b) It shows an occluder in the large PDA with left to right residual leakage and device-related stenosis of the descending aortic artery. The pink arrows represent the direction of residual leakages. The primary large occluder is shown in yellow. (c) Catheter is delivered into the pulmonary artery with a catcher inside. The soft side tip of ultra-smooth guide wire crosses through the aortic side, along the waist of the Amplatzer septal occluder, and over to the pulmonary side of the septal occluder. (d) The catcher successfully catches the soft tip of the guide wire. The track is successfully built up. (e) The appropriate-sized device is embedded into the waist of the occluder. Another PDA device shown in gray is embedded in the waist of the occluder. (f) Repeated angiograms in the descending aorta show no residual leakage

surgical treatment should be considered as soon as possible, when there is a definite diagnosis of PDA. The main surgical treatments include open surgery and international cardiac catheterization. Surgeries by opening the chest usually result in massive trauma, numerous complications, esthetic problems,

and slow recovery (7). To some extent, open-chest surgery restricts the clinical application of surgery for the ligation of PDA. Recently, interventional cardiac catheterization has evolved into a quick and mature method (8). It has the advantages of minimal invasiveness and quick recovery. However, radiation exposure to surgeons and patients is inevitable. Moreover, the procedure is complicated and the equipment is expensive. In addition, as soon as complications such as displacement of the occluder and/or bleeding occur, the patient has to be transferred from the cardiac catheterization laboratory to the operating room.

Recently, the hybrid technique combines the advantages of both surgery and catheterization (9). It is performed under the guidance of transesophageal echocardiography. It avoids excessive radiation exposure and massive trauma. However, it can also cause residual leakage because of malposition of occluder or improper choice of device under the guidance of transesophageal echocardiography.

Residual leakage has been associated with higher long-term mortality in adults post PDA closure using the Amplatzer device (10). Residual PDA flow has a great clinical impact on patients and contributes to hemodynamic disturbances, obstructive pulmonary artery hypertension, paradoxical emboli, and endocarditis etc. Residual PDA shunt through a previously occluded ductus arteriosus by using device is a result of an improper choice of the closure-device. In this case, previous PDA was closed with a 38 mm HeartR™ Amplatzer septal occluder. Two years after the hybrid technique, residual leakage and descending aortic stenosis were documented in this patient. Descending aortic narrowing was not

related to a significant pressure gradient, however, the residual shunt resulted in pulmonary hypertension (mean PAP=47 mm Hg) and the patient complained of progressive dyspnea on exertion. The usual method of the closing of the residual shunt includes involves either surgery or the deployment of an appropriate device. It is a challenge for traditional surgeons to achieve a similar result without using the Amplatzer septal device. Since the narrowing of the descending aortic lumen did not result in a significant pressure gradient, we chose the international cardiac catheterization to occlude the PDA leakage. It is technically feasible to occlude residual leaks using an additional umbrella device and this has been reported previously (11). However, this technique was described alongside the first device and not inside the primary device.

In this patient, we first reported the “umbrella in umbrella” technique, which was successfully applied with no residual shunt after the procedure. The experiences that followed were valuable in increasing the successful rate of re-catheterization for closure of residual PDA flow using the described “umbrella in umbrella” technique. There were a few keys steps in this process. Firstly, a successful establishment of the venoarterial loop construction was important and a retrograde approach was used in this case. The size of the disk mesh was gradually increased and radially arranged from the center to its periphery. The penetration through the disk was as peripheral as possible. Secondly, the selection of the appropriate guide wires helped to increase the operation security and manual handling. In this case, a Pilot-150 guide wire was used to pass into the disk mesh. Meanwhile, the hard tip of smooth guide wire was used to penetrate into the polyethylene (Dacron) layers. Thirdly, the use of the micro-catheter contributed to correcting the direction of the guide wires. Last, the metal disk mesh was expanded by the use of the sheath.

Conclusion

The “umbrella in umbrella” technique is a safe and feasible method for residual PDA leakage closure using a second device. The major factors for the success of this technique include loop construction, determination of the morphology of the ductus, and selection of the device.

Informed consent: Written informed consent was obtained from this patient.

Video 1. Angiography before closure. Angiogram with the 5-F pigtail catheter in the proximal descending aorta was performed to calcify the PDA leakage and classify its shape. An Amplatzer septal occluder and an obvious PDA (the diameter of the smallest stenosis=17 mm) connecting the proximal portion of the descending aorta to the left portion of the pulmonary artery were visualized.

Video 2. Building up the track. Following the withdrawal of the guide wire and placement of the hard tip of the Cobra guiding catheter into the occluder waist, the hard tip of guide wire was

successfully passed from the pulmonary side of the Amplatzer septal occluder into the pulmonary artery, under the guidance of the Cobra catheter.

Video 3. Releasing the occluder. The sheath and device were then pulled back into a position just distal to the ampulla.

Video 4. Angiography before releasing the occluder. The position of the device was confirmed with repeated angiograms in the descending aorta. No residual leakage was observed.

Video 5. Angiography after releasing the occluder during the 3-month follow-up. Aortic angiography was performed at the descending aorta and no leakage was visible.

References

- Vettukattil JJ. Pathophysiology of Patent Ductus Arteriosus in the Preterm Infant. *Curr Pediatr Rev* 2016; 12: 120-2. [CrossRef]
- Agrawal H, Waller BR 3rd, Surendan S, Sathanandam S. New Patent Ductus Arteriosus Closure Devices and Techniques. *Interv Cardiol Clin* 2019; 8: 23-32. [CrossRef]
- Sinha SK, Razi M, Pandey RN, Kumar P, Krishna V, Jha MJ, et al. Prospective evaluation of the feasibility, safety, and efficacy of Cocoon Duct Occluder for transcatheter closure of large patent ductus arteriosus: A single-center study with short- and medium-term follow-up results. *Anatol J Cardiol* 2017; 18: 321-7. [CrossRef]
- Gu Q, Ma L, Gu H, Meng Y, Shen C, Kong X, et al. A hybrid approach for patent ductus arteriosus closure using the Amplatzer Duct Occluder. *J Card Surg* 2018; 33: 684-7. [CrossRef]
- Agrawal H, Alkashkari W, Kenny D. Evolution of hybrid interventions for congenital heart disease. *Expert Rev Cardiovasc Ther* 2017; 15: 257-66. [CrossRef]
- Baspinar O, Kilinc M, Kervancioglu M, Irdem A. Transcatheter closure of a residual patent ductus arteriosus after surgical ligation in children. *Korean Circ J* 2011; 41: 654-7. [CrossRef]
- Cao H, Chen Q, Zhang GC, Chen LW, Xu F, Zhang JX. Clinical study of stand-alone transthoracic echocardiography-guided percutaneous occlusion of patent ductus arteriosus. *Anatol J Cardiol* 2018; 20: 30-4.
- Narin N, Pamukcu O, Baykan A, Argun M, Özyurt A, Bayram A, et al. Transcatheter closure of PDA in premature babies less than 2 kg. *Anatol J Cardiol* 2017; 17: 147-53. [CrossRef]
- He J. History and current status of mini-invasive thoracic surgery. *J Thorac Dis* 2011; 3: 115-21.
- Pass RH, Hijazi Z, Hsu DT, Lewis V, Hellenbrand WE. Multicenter USA Amplatzer patent ductus arteriosus occlusion device trial: initial and one-year results. *J Am Coll Cardiol* 2004; 44: 513-9. [CrossRef]
- Abbag F, Galal O, Fadley F, Oufi S. Re-occlusion of residual leaks after transcatheter occlusion of patent ductus arteriosus. *Eur J Pediatr* 1995; 154: 518-21. [CrossRef]

Address for Correspondence: Shenghua Zhou, MD,
Department of Cardiology,
The Second Xiangya Hospital of Central South University,
139 Middle Renmin Road, Furong District,
Changsha City, Hunan Province 410011,
Changsha - China

Phone: +86 731 85292013

E-mail: zhoushenghua@csu.edu.cn

©Copyright 2020 by Turkish Society of Cardiology - Available online at www.anatoljcardiol.com

DOI:10.14744/AnatolJCardiol.2019.77782

