

ment of serious HSR. Indeed, comorbidities have been reported to increase the risk of HSR by at least 2.8 times, regardless of the type of IV-iron formulations (6).

Conclusion

It should be kept in mind that fatal AR related to FCM administration may develop, although rare. Therefore, FCM should be administered in centers where emergency treatment can be delivered by healthcare personnel who can evaluate and manage AR. It should be known that every administration bears AR risk, even if the previous treatment was well tolerated.

References

1. Friedrisch JR, Cançado RD. Intravenous ferric carboxymaltose for the treatment of iron deficiency anemia. *Rev Bras Hematol Hemoter* 2015; 37: 400-5.
2. Gafter-Gvili A, Schechter A, Rozen-Zvi B. Iron deficiency anemia in chronic kidney disease. *Acta Haematol* 2019; 142: 44-50.
3. EMA-CHMP. Assessment report for: iron containing intravenous (IV) medicinal products EMA/549569/2013,2013 (last accessed 10 February 2020). Available at; URL: http://www.ema.europa.eu/docs/en_GB/document_library/Referrals-document/IV_iron_31/WC500150771.pdf
4. Scott LJ. Ferric Carboxymaltose: A Review in Iron Deficiency. *Drugs* 2018; 78: 479-93.
5. Ehlken B, Nathell L, Gohlke A, Bocuk D, Toussi M, Wohlfeil S. Evaluation of the reported rates of severe hypersensitivity reactions associated with ferric carboxymaltose and iron (III) isomaltoside 1000 in Europe based on data from EudraVigilance and VigiBase™ between 2014 and 2017. *Drug Saf* 2019; 42: 463-71.
6. Mulder MB, van den Hoek HL, Birnie E, van Tilburg AJP, Westerman EM. Comparison of hypersensitivity reactions of intravenous iron: iron isomaltoside-1000 (Monofer®) versus ferric carboxymaltose (Ferinject®). A single center, cohort study. *Br J Clin Pharmacol* 2019; 85: 385-92.
7. Ferinject (ferric carboxymaltose). Uptating 13 November 2019. (last accessed 10 February 2020). Available at; URL: <https://www.medicines.org.uk/emc/product/5910/smpc>
8. FDA-CDER. Injectafer (VIT-45, ferric carboxymaltose injection; FCM) for the treatment of iron deficiency anemia. Updated clinical safety information (last accessed 10 February 2020). Available at; URL: https://www.accessdata.fda.gov/drugsatfda_docs/nda/2013/2035650rig1s000MedR.pdf
9. Ponikowski P, Voors AA, Anker SD, Bueno H, Cleland JG, Coats AJ, et al.; Authors/Task Force Members; Document Reviewers. 2016 ESC Guidelines for the diagnosis and treatment of acute and chronic heart failure: The Task Force for the diagnosis and treatment of acute and chronic heart failure of the European Society of Cardiology (ESC). Developed with the special contribution of the Heart Failure Association (HFA) of the ESC. *Eur J Heart Fail* 2016; 18: 891-975.
10. LiverTox: Clinical and Research Information on Drug-Induced Liver Injury [Internet]. Adverse Drug Reaction Probability Scale (Naranjo) in Drug Induced Liver Injury (last accessed 10 February 2020). Available at; URL: <https://www.ncbi.nlm.nih.gov/books/NBK548069/>

Address for Correspondence: Dr. Ayşe Gelal,

Dokuz Eylül Üniversitesi Tıp Fakültesi,

Tıbbi Farmakoloji Anabilim Dalı,

35340 İzmir-Türkiye

Phone: +90 232 412 39 04

E-mail: ayse.gelal@deu.edu.tr

©Copyright 2020 by Turkish Society of Cardiology - Available online at www.anatoljcardiol.com

DOI:10.14744/AnatolJCardiol.2020.38996



Misinterpretation of dual atrioventricular nodal non-reentrant tachycardia as ventricular tachycardia and implantation of implantable cardioverter-defibrillator followed by inappropriate shocks

Yusuf Türkmen

Department of Cardiology, Karolinska Institute, Karolinska University Hospital; Stockholm-Sweden

Introduction

A double ventricular response to a single atrial beat is defined as “double-fire,” and this forms the basis of dual atrioventricular (AV) nodal non-reentrant tachycardia (DAVNNT), which can mimic several other arrhythmias and lead the clinicians to misdiagnose and mismanage it. DAVNNT was first described in 1975 by Wu et al. (1). Until date, overall, 77 cases have been reported (2, 3) as DAVNNT, with tachycardia-induced cardiomyopathy developing in only few of these patients. To our knowledge, only few patients have been treated with implantable cardioverter-defibrillator (ICD) because of misinterpreting DAVNNT as VT.

Case Report

A 58-year-old female experienced her first palpitation 18 years ago, but it became persistent over the years. Physicians detected wide QRS tachycardia on her surface electrocardiography (ECG), which was recorded 8 years ago. An electrophysiological study was performed 5 years ago in sinus rhythm, but no tachycardia could be induced. Her coronary arteries were normal, but left ventricular ejection fraction (LVEF) was 35% on transthoracic echocardiography. Hence, ICD was implanted because of decreased left ventricular function and the previously documented wide QRS tachycardia. Nonetheless, the patient remained symptomatic despite antiarrhythmic medication and ICD. She was referred to our university's arrhythmia department because of her increased ongoing complaints. Notably, the patient informed that her symptoms disappeared during ex-

ercise. Her surface ECG showed “coupled-grouped beats” (Fig. 1) with a rate of approximately 134 beats per minute, but ICD recordings appeared to be ventricular tachycardia (VT). Atrial (A) and ventricular (V) signals seemed to be dissociated on the first look, but a constant relation existed between (V) and (A) signals, and the intervals between (V) signals were not equal. However, the next two R-R intervals were very close to each other, and an electrical alternans was also noticed by us (Fig. 2). VT and ventricular fibrillation zone cut-offs were 160 and 214 beats per minute, respectively. The patient was treated using anti-tachycardia pacing first and received biphasic shocks for the VT. Notably, supraventricular tachycardia (SVT) and VT discrimination criteria included electrogram morphology match, sudden onset, and interval stability. The interval stability was adjusted to 60 milliseconds (msec), and it was the most responsible parameter of false shocks despite a 3/3 match necessitating therapy.

The patient was referred for electrophysiological study. During sinus rhythm, the atrio-His₁ (AH₁), atrio-His₂ (AH₂), and His-ventricle intervals were 98, 420, and 45 msec, respectively, which demonstrated extremely elongated conduction of atrial signal over the slow pathway (Fig. 3).

Both atrioventricular re-entrant (AVRT) and atrioventricular nodal re-entrant (AVNRT) tachycardias were excluded through differential pacing maneuvers under isoproterenol infusion. Wenckebach AV conduction block developed at a drive train of 660 msec. Focal cryoenergy was delivered using Freezor XTRA™ (Medtronic Inc. Minneapolis, MN, USA) catheter to the bottom of coronary sinus ostium to eliminate conduction over the slow pathway. Atrial signals were conducted to the ventricle over the fast pathway during ablation, and cryoenergy was delivered

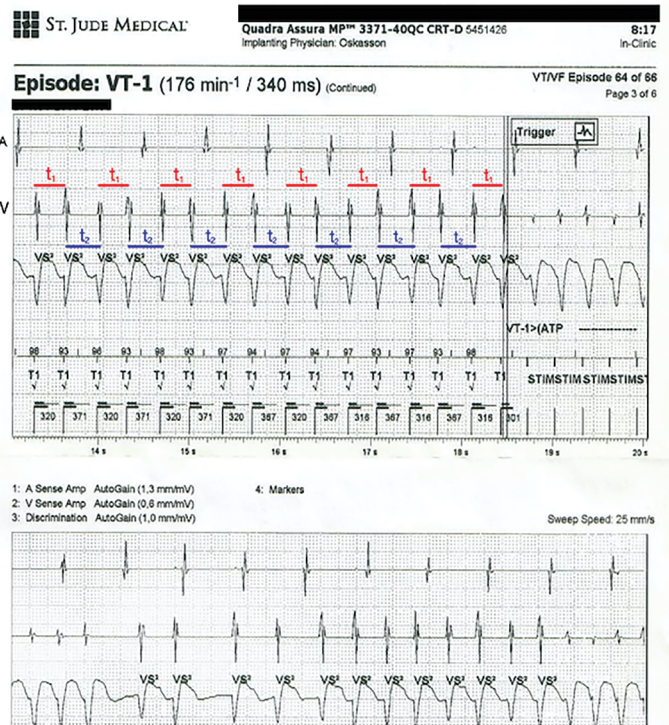


Figure 2. Intracardiac recording of ICD clearly reveals dissociation of atrial and ventricular signals and it mimics VT at the first look. The (t₁) interval was equal to 320 msec, whereas (t₂) interval measured 370 msec and revealed constant relation between each of the next two ventricular contraction and atrial signals. Furthermore, tachycardia was not successfully terminated by ATP and restarted to give double response to each atrial contraction
ICD - implantable cardioverter-defibrillator, msec - milliseconds, ATP - anti-tachycardia pacing

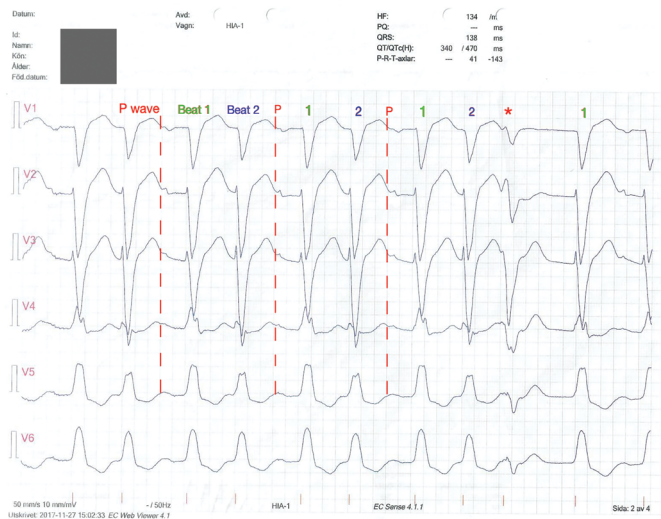


Figure 1. Each P wave was followed by double wide QRS complexes. Double responses with almost same morphology and axis was followed by another totally different (*) premature contraction of ventricle. P: P wave, 1: First beat of double response, 2: Second beat of double response, *: Premature ventricular contraction

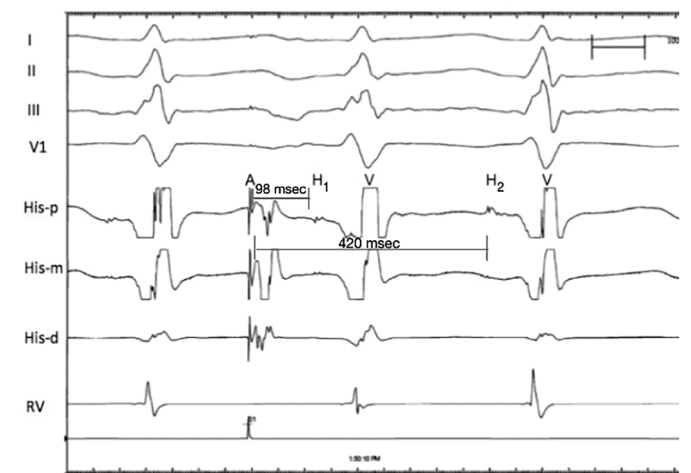


Figure 3. Real-time recording of four surface electrocardiogram leads and intracardiac electrograms from the His bundle proximal (His-p), His bundle medial (His-m), His bundle distal (His-d), and right ventricular apex. The conduction of atrial signal through the fast and slow pathways, as well as extremely prolonged conduction over the slow pathway are shown. H₁, His bundle activation through the fast pathway; H₂, His bundle activation through the slow pathway; AH₁=98 msec, AH₂=420 msec

seven times for overall 1683 seconds. Additional 13 stimulations were performed after 30 minutes of ablation, but no tachycardia or dual response could be detected, and the clinical tachycardia was accepted as non-inducible.

The patient was treated with slow pathway ablation and has experienced no further palpitations or ICD therapies at 38 months of follow-up. Her LVEF improved to 50%–55% after 3 years of ablation. Her ICD reached elective replacement interval time after 38 months of ablation therapy, but no arrhythmia was noted on ICD recordings. Because of improved LVEF, absence of any arrhythmia and symptoms, the ICD battery was removed and decided not to be replaced with a new one.

Discussion

DAVNNT is a rarely published arrhythmia type and can often be misdiagnosed as atrial tachycardia, atrial fibrillation, VT, or premature ventricular contractions (2). Although the treatment of this arrhythmia is easy, the diagnosis can be challenging because of its highly mimicking features. Until date, DAVNNT has been the cause of tachycardia-induced cardiomyopathy in only eight patients (4-8). Atrial conduction over both slow and fast AV nodes is an underlying cause of this arrhythmia, which explains the double ventricular response to a single atrial signal. However, the absence of re-entry between slow and fast pathways makes it different from AVNRT. The effective refractory period and retrograde conduction features of the fast pathway may explain the underlying mechanism of DAVNNT. However, the precise clinical reason for this condition is not fully understood. Presumably, bad retrograde conduction feature of fast pathway and occurrence of AV block during a high drive train of ventricular stimulations could be the cause of DAVNNT.

Notably, AVNRT has a relatively difficult start and terminates in a short time. In contrast, DAVNNT starts easily in the presence of appropriate electrophysiological conditions and persists for long periods in few patients. In addition, the lower ventricular rate in DAVNNT and the absence of sudden onset and termination features of tachycardia, and nonexistence of well-defined surface ECG makes it challenging to detect it in daily practice. Unlike AVNRT, it increases the risk for tachycardia-induced cardiomyopathy because of its prolonged duration and similarities to sustained AT, AFL, and other incessant SVT.

The symptoms of our patient had started 15 years ago, and we believe that both tachycardiomyopathy and LBBB developed during this period. Based on the presence of LBBB, DAVNNT was misdiagnosed as VT and treated using ICD implantation. Per the literature, only few patients have been treated with ICD because of DAVNNT until now, and with one of them being diagnosed with sarcoidosis before, the exact reason for ICD implantation was unclear (9). However, our patient did not have any known cardiovascular diseases earlier, and the only cardiological problem was long-term, misdiagnosed, and untreated DAVNNT. Even

though treatment guidelines have not considered ablation as the gold standard, it has been accepted as the most effective approach for treating DAVNNT. Moreover, this arrhythmia was alternatively treated using medication, and only one patient could be effectively treated, as noted on long-term follow-up (10). Furthermore, less information is available regarding the short-term, effective management of DAVNNT by using medication. One patient was deemed unsuitable for ablation and was successfully treated using propafenone for one day; however, the patient was lost to follow-up (11). The current patient was initially treated effectively with amiodarone, which could not be continued because of its side effects (12).

On the other hand, every second beat after P wave in our ECG could be evaluated as a premature ventricular contraction; however, the presence of almost the same morphology and axis of both consecutive QRS complexes excluded this probability. Furthermore, compensatory delay period in the sinus node activation and A-A intervals were not equal on the intracardiac electrogram recordings.

Conclusion

In summary, DAVNNT may be easily misdiagnosed as other complicated arrhythmias and lead to the unnecessary implantation of ICD. Furthermore, it can cause tachycardia-induced cardiomyopathy in certain patients, and the treatment of this arrhythmia plays a crucial role in the restoration of systolic functions. Therefore, we recommend that clinicians consider the possibility of DAVNNT in the presence of longstanding, mild cardiac symptoms, especially in cases where the number of QRS is more than P waves on surface ECG.

Informed consent: The informed written consent of the patient has taken by the clinician as a routine approach of our institution.

References

1. Wu D, Denes P, Dhingra R, Pietras RJ, Rosen KM. New manifestations of dual A-V nodal pathways. *Eur J Cardiol* 1975; 2: 459–66.
2. Peiker C, Pott C, Eckardt L, Kelm M, Shin DI, Willems S, et al. Dual atrioventricular nodal non-re-entrant tachycardia. *Europace* 2016; 18: 332–9. [\[CrossRef\]](#)
3. Karimli E, Kara M, Korkmaz A, Cay S, Ozeke O, Ozcan F, et al. Dual 1: 2 tachycardia: What is the mechanism? *J Cardiovasc Electro-physiol* 2020; 31: 733-5. [\[CrossRef\]](#)
4. Barbato G, Carinci V, Badhwar N. Tachycardia-Induced Cardiomyopathy. *Card Electrophysiol Clin* 2010; 2: 209–12. [\[CrossRef\]](#)
5. Li VH, Mallick A, Concannon C, Li VY. Wide complex tachycardia causing congestive heart failure. *Pacing Clin Electrophysiol* 2011; 34: 1154-7. [\[CrossRef\]](#)
6. Anselme F, Frederiks J, Boyle NG, Papageorgiou P, Josephson ME. An unusual cause of tachycardia-induced myopathy. *Pacing Clin Electrophysiol* 1996; 19: 115–9. [\[CrossRef\]](#)

7. Gaba D, Pavri BB, Greenspon AJ, Ho RT. Dual antegrade response tachycardia induced cardiomyopathy. *Pacing Clin Electrophysiol* 2004; 27: 533–6. [[CrossRef](#)]
8. Clementy N, Casset-Senon D, Giraudeau C, Cosnay P. Tachycardiomyopathy secondary to nonreentrant atrioventricular nodal tachycardia: recovery after slow pathway ablation. *Pacing Clin Electrophysiol* 2007; 30: 925–8. [[CrossRef](#)]
9. Karnik AA, Hematpour K, Bhatt AG, Mazzini MJ. Dual AV Nodal Nonreentrant Tachycardia Resulting in Inappropriate ICD Therapy in a Patient with Cardiac Sarcoidosis. *Indian Pacing Electrophysiol J* 2014; 14: 44–8. [[CrossRef](#)]
10. Kim SS, Lal R, Ruffy R. Paroxysmal nonreentrant supraventricular tachycardia due to simultaneous fast and slow pathway conduction in dual atrioventricular node pathways. *J Am Coll Cardiol* 1987; 10: 456–61. [[CrossRef](#)]
11. Kaczmarek K, Ruta J, Wranicz J, Ptaszynski P. A new type of dual atrioventricular nodal nonreentrant tachycardia. *Ann Noninvasive Electrocardiol* 2014; 19: 501–3. [[CrossRef](#)]
12. Mádle A. A nonreentrant arrhythmia due to a dual atrioventricular nodal pathway. *Int J Cardiol* 1990; 26: 217–9. [[CrossRef](#)]

Address for Correspondence: Yusuf Türkmen, MD,

Department of Cardiology,
Karolinska Institute,
Karolinska University Hospital;
Stockholm-Sweden

Phone: +90 432 215 04 70

E-mail: josephatayev@yahoo.com

©Copyright 2020 by Turkish Society of Cardiology - Available online
at www.anatoljcardiol.com

DOI:10.14744/AnatolJCardiol.2020.73709

