

Correlation between serum matrix metalloproteinase and myocardial fibrosis in heart failure patients with reduced ejection fraction: A retrospective analysis

Ömer Çelik, Ahmet Anıl Şahin, Serdar Sarıkaya, Begüm Uygur

Department of Cardiology, University of Health Sciences, İstanbul Mehmet Akif Ersoy Thoracic and Cardiovascular Surgery Training and Research Hospital; İstanbul-Turkey

ABSTRACT

Objective: A strong correlation exists between myocardial fibrosis and heart failure (HF). Myocardial fibrosis can be detected by cardiac magnetic resonance (CMR), which is a crucial noninvasive imaging method with high specificity and sensitivity. Matrix metalloproteinases (MMPs) are primary proteases responsible for the degradation of extracellular matrix (ECM) components, and they play a vital role in maintaining the balance between anabolism and catabolism of ECM. This study aims to investigate the correlation between cardiac fibrosis detected on CMR and serum MMP-9 levels in patients with HF.

Methods: We enrolled 53 patients (age: ≥ 18 years) with left ventricular ejection fraction (LVEF) $\leq 40\%$, who received CMR because of various indications. All patients were divided into two groups-with cardiac fibrosis (n=32) and without cardiac fibrosis (n=21)-detected by CMR with late-Gadolinium. Both groups were then compared according to MMP-9 levels.

Results: MMP-9 levels were significantly higher in patients with cardiac fibrosis than those without fibrosis ($p < 0.01$). A correlation was determined between the diffusiveness of fibrosis and serum MMP-9 levels. Besides, a statistically significant correlation was determined between MMP-9 measurements and the number of segments with fibrosis ($p < 0.05$). In the group with cardiac fibrosis, LVEF measurements by CMR were significantly lower ($p < 0.01$), with left ventricular end-diastolic volume (LVEDV) and left ventricular end-systolic volume (LVESV) measurements significantly higher ($p < 0.01$), than the other group. Furthermore, we found a statistically significant correlation between MMP-9 levels and LVEDV and LVESV.

Conclusion: MMP-9 levels correlate with cardiac remodeling in patients with HF and could be useful in predicting left ventricular fibrosis. In clinical practice, the use of serum MMP-9 could provide early consideration of therapies for structural and functional pathology of the heart in patients with HF (*Anatol J Cardiol* 2020; 24: 303-8)

Keywords: myocardial fibrosis, cardiac magnetic resonance, heart failure, matrix metalloproteinase

Introduction

Cardiac fibrosis is a pathological process that could be triggered by ischemia, stress, inflammation, or neurohormonal activities. The etiology of heart failure (HF) determines the distribution and prevalence of fibrosis. Diffuse cardiac fibrosis occurs in idiopathic dilated cardiomyopathy, diabetic cardiomyopathy, hypertensive heart disease, and hypertrophic cardiomyopathy (1). Fibrosis is the major component of myocardium remodeling in ischemic cardiomyopathy; in these patients, focal cardiac fibrosis occurs in ischemic segments (2). In addition, fibrosis in HF has been reported to be associated with mortality and hospitalization (3-5).

Enhanced protease activity in HF contributes to collagen degradation, weakening of connective tissue, impaired myocardial integrity, and ventricular remodeling (1). Although endomyocardial biopsy remains the gold standard for detecting cardiac fibrosis, some other modalities could also be used in clinical practice such as echocardiography, cardiac magnetic resonance (CMR), and biomarkers; indeed, one of the leading methods is the measurement of collagen metabolism-induced biomarkers in the serum. Matrix metalloproteinases (MMP) often perform physiological and pathological connective tissue remodeling by maintaining a balance between collagen synthesis and degradation. MMPs are the primary matrix destructive proteases capable of degrading all protein components of the

Address for correspondence: Dr. Ömer Çelik, Sağlık Bilimleri Üniversitesi, İstanbul Mehmet Akif Ersoy Göğüs, Kalp ve Damar Cerrahisi Eğitim ve Araştırma Hastanesi, İstanbul-Türkiye
Phone: +90 505 260 71 21 E-mail: dromer38@gmail.com

Accepted Date: 21.05.2020 **Available Online Date:** 20.10.2020

©Copyright 2020 by Turkish Society of Cardiology - Available online at www.anatoljcardiol.com
DOI:10.14744/AnatolJCardiol.2020.54937



extracellular matrix (ECM) (6). Lately, CMR has become the non-invasive gold standard method for detecting focal cardiac fibrosis (7). Furthermore, some studies have established a correlation between fibrosis detected in T1 tissue-time CMR and endomyocardial biopsy in patients with HF (8).

This study aims to investigate the correlation between cardiac fibrosis detected on CMR and serum MMP-9 levels in patients with HF.

Methods

This retrospective study was approved by a Local Ethics Committee, which waived the need for obtaining informed consent for the investigation and presentation of deanonimized medical data. We retrospectively examined patients (age: ≥ 18 years) diagnosed with HF who had left ventricular ejection fraction (LVEF) $\leq 40\%$, were admitted to İstanbul Mehmet Akif Ersoy Thoracic and Cardiovascular Surgery Training and Research Hospital from January 2017 to June 2018, and received CMR because of various indications, such as cardiac mass-thrombus investigation, viability, and ejection fraction calculation, related to ischemic cardiomyopathy. Of note, we excluded patients who had intracardiac mass or thrombus, etiology of non-ischemic cardiomyopathy, and moderate to severe valvular heart disease on CMR.

We retrospectively assessed our image and archive communicating system (ExtremePacs, Ankara/Turkey) on a daily basis. In addition, we assessed the images of patients with HF scheduled for CMR examination. In this study, HF was defined according to the 2016 ESC guidelines (9).

All patients eligible for this study were recalled to the hospital for blood sampling. Blood samples were obtained from patients 12–72 h of time interval after performing CMR. In addition, blood samples for plasma MMP-9 levels were obtained from the antecubital vein and stored in ethylenediaminetetraacetic acid tubes. Then, the samples were centrifuged (4°C, 5 min, 2000 \times g), and the supernatant was stored in a freezer at -40°C until the measurement. All measurements were performed with a medical device (Roche Diagnostics, GmbH, Mannheim, Germany) to detect MMP levels for every patient. Of note, patients with HF were compensated and were taking optimal medical therapy for their condition. All patients' functional classes were New York Heart Association class 1 or 2.

All CMR studies were performed with a 1.5-T scanner (Aera, Siemens Medical Systems, Erlangen, Germany), and all CMR acquisitions were performed using phased-array body coils. All the sequences were obtained using prospective cardiac gating. The CMR protocol, in the order of first to last, comprised breath-hold black-axial blood fast spin-echo, multiple breath-hold long-axis four-chamber, long-axis two-chamber, 9–12 stack of short-axes cine images breath-hold using balanced steady-state free precession imaging (SSFP), two-dimensional late gadolinium-en-

hanced (LGE) sequences in four-chamber, two-chamber, and short-axis views covering the entire left ventricle myocardium. The parameters for SSFP cine images were as follows: TR/TE, 3.8/1–3 ms; slice thickness, 5 mm with 5-mm interslice gap; and temporal resolution, 35 ms. We obtained LGE sequences nearly 12 (range: 10–15) min after the administration of 0.10–0.12 mmol/kg gadolinium-DTPA (Magnevist; Schering AG®, Berlin, Germany). Furthermore, the parameters for LGE sequences were as follows: TR/TE, 9.0/3.0 ms; slice thickness, 5 mm; and inversion time, 200–300 ms, which were adjusted as required for each patient to null the normal myocardial signal completely.

Using software systems and functional analysis methods, endocardial and epicardial borders were monitored manually. In addition, the end-diastolic and end-systolic stages were determined in each study using the Argus (Siemens Healthcare, Erlangen, Germany) software system. The observer evaluated the left ventricular functions by calculating the LVEF using the modified Simpson's method on short-axis cine images with the software. Moreover, the observer semi-automatically traced the largest and narrowest ventricular diameters in the middle of the ventricle; this method was used for each stage. Besides, endocardial and epicardial margins were monitored manually on short-axis images at both stages. We divided the left ventricular myocardium into 17 segments-6 regions at the basal level; 6 regions at the midventricular level; 4 regions at the apical level; and 1 apex-based on the American Heart Association segmentation model for the left ventricle (10). Notably, patients with an ejection fraction $>40\%$, HF with preserved ejection fraction, and HF without CMR images were excluded from this study.

Statistical analysis

All statistical analyses were performed using the Number Cruncher Statistical System (NCSS) 2007 (Kaysville, UT, USA). We investigated all continuous variables using the Kolmogorov–Smirnov test to determine their normality. The normally distributed continuous variables are presented as means and standard deviations, while the categorical variables are expressed in frequencies and percentages. We compared all normally distributed continuous variables using the Student's t-test. In addition, Pearson χ^2 and Fisher's Exact test were used to compare the qualitative data. Using Spearman's correlation coefficient, we analyzed the correlation. Furthermore, we performed the binary logistics regression analysis to explore correlation with the presence of LGE. In this study, $p < 0.05$ was considered statistically significant.

Results

We enrolled 53 patients, of whom 32 with cardiac fibrosis were grouped as LGE (+), while the remaining 21 patients without cardiac fibrosis were grouped as LGE (–). Table 1 shows the characteristics and biochemical parameters of the study groups.

Table 1. Demographic characteristics and laboratory findings of the patients

	LGE (+) (n=32)	LGE (-) (n=21)	P
Sex (Male)	30 (56.6%)	13 (61.5%)	0.562
Age	61.6±8.3	59.9±8.5	0.632
Diabetes mellitus (n-%)	11 (20.7%)	9 (16.9%)	0.573
Hypertension (n-%)	29 (54.7%)	20 (37.7%)	0.479
Hyperlipidemia (n-%)	22 (41.5%)	15 (28.3%)	0.542
LBBB (n-%)	5 (9.4%)	3 (5.7%)	0.609
Body mass index (kg/m ²)	25.9±2.9	26.9±4.7	0.339
Hemoglobin (g/dL)	13.3±2	12.7±1	0.317
White blood cell count (10 ⁹ /L)	11.8±10	8.2±2	0.140
Creatinine (mg/dL)	1.3±0.5	1±0.4	0.015
Glomerular filtration rate (mL/min/1.73 m ²)	62.9±21	79.4±18	0.006
MMP-9	1699±254	1356±335	<0.001

MMP-9 - matrix metalloproteinase-9; LGE - late gadolinium-enhanced; LGE (+) - patients with cardiac fibrosis group; LGE (-) - patients without cardiac fibrosis group

We observed no significant differences in the patients' characteristics. In both groups, creatinine and glomerular filtration rate (GFR) were in the normal range. However, the levels of MMP-9 (1699±254 vs. 1356±335; p<0.001) and creatinine (1.3±0.5 vs. 1±0.4; p=0.015) were significantly higher in the LGE (+) group; GFR (62.9±21 vs. 79.4±18; p=0.006) was lower in the LGE (+) group compared with the LGE (-) group (Table 1).

Table 2 presents the CMR findings for the left ventricular volume and LVEF. The left ventricular end-diastolic volume (LVEDV; 257±62 vs. 188±42; p<0.001) and left ventricular end-systolic volume (LVESV; 178±54 vs. 116±39; p<0.001) were significantly high-

er in the LGE (+) group, and the LVEF (28.1±3 vs. 35.5±4; p<0.001) was significantly lower in the LGE (+) group compared with the LGE (-) group.

We observed positive correlations between MMP-9 levels and LVEDV (r=0.711; p<0.001) and LVESV (r=0.655; p<0.001). A negative correlation was found between MMP-9 and LVEF (r=-0.634; p<0.001; Table 3). Accordingly, MMP-9 levels significantly increased when the left ventricular diastolic and systolic volumes increased. Figure 1 shows a positive correlation between MMP-9 levels and the quantity of LGE in CMR. In binary logistic regression analyses, the LVEF and MMP-9 levels remained as independent predictors in the presence of LGE (Table 4). Over-

Table 2. Cardiac magnetic resonance findings of the patients

	LGE (+) (n=32)	LGE (-) (n=21)	P
LVEDV (mL)	257±62	188±42	<0.001
LVESV (mL)	178±54	116±39	<0.001
LVEF (%)	28.1±3	35.5±4	<0.001
Quantity of LGE	4.9±1.8		

LGE - late gadolinium-enhanced; LGE (+) - patients with cardiac fibrosis group; LGE (-) - patients without cardiac fibrosis group

Table 3. The positive and negative correlation between MMP-9 levels and CMR findings of the patients

	r	P
Left ventricular end-diastolic volume	0.711	<0.001
Left ventricular end-systolic volume	0.655	<0.001
Left ventricular ejection fraction	-0.634	<0.001
Quantity of LGE	0.589	<0.001

MMP-9 - matrix metalloproteinase-9; LGE - late gadolinium-enhanced

Table 4. Binary logistics regression analysis for the presence of LGE

	Odds ratio	95% CI	P
Gender	6.086	0.544-88.807	0.134
Left ventricular end-diastolic volume	1.007	0.935-1.1084	0.862
Left ventricular end-systolic volume	0.949	0.859-1.047	0.295
Left ventricular ejection fraction	0.498	0.283-0.787	0.016
MMP-9	7.287	3.820-13.902	<0.001

MMP-9 - matrix metalloproteinase-9; LGE - late gadolinium-enhanced; CI - confidence interval

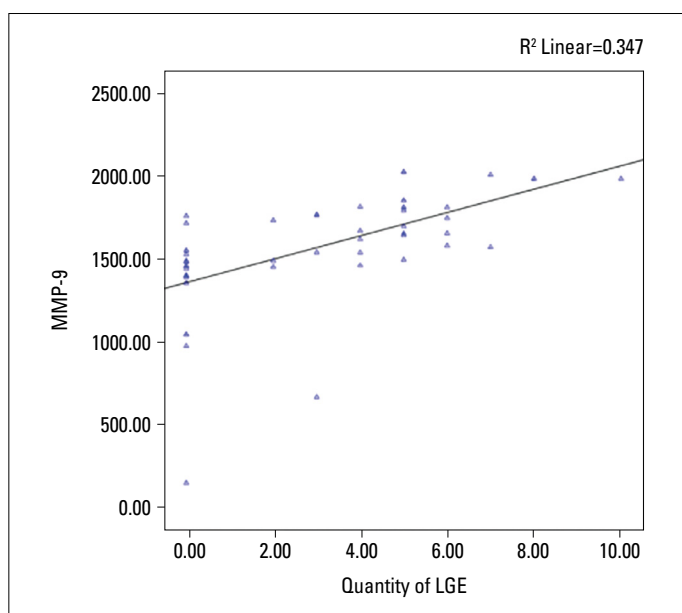


Figure 1. A positive correlation between increased matrix metalloproteinase-9 (MMP-9) levels and the quantity of late gadolinium-enhanced (LGE) in cardiac magnetic resonance

all, these findings suggested that the MMP-9 level increment significantly predicted the presence of LGE in patients with HF, independent of ventricular dilatation.

Discussion

Cardiac fibrosis is a critical component of HF owing to the strong correlation between cardiac fibrosis and HF progression. This study investigated the correlation between MMP-9 and cardiac fibrosis detected on CMR in patients with HF related to ischemic cardiomyopathy. Our findings revealed that the MMP-9 levels increased in patients with fibrosis, as well as correlated with the quantity of LGE, which directly demonstrated the amount of fibrosis. Our study supports the strong correlation between cardiac fibrosis and HF. As a marker of cardiac fibrosis, MMP-9 has a good relationship with the amount of fibrosis in HF patients with ischemic cardiomyopathy.

In energy-dependent cardiomyocytes, ischemia-driven cardiomyopathy occurs secondary to decreased blood flow; Burch et al. (11) termed this clinical syndrome as ischemic cardiomyopathy. If ischemic state and persistent impairment in perfusion continue, myocardial damage and structural and functional changes occur, which result in cardiac fibrosis and remodeling. Some previous studies have documented the correlation between ischemic cardiomyopathy, fibrosis, and cardiovascular adverse event (12, 13). Thus, studies lately indicated that slowing and reversal of remodeling is the key chain in the treatment of HF (14, 15). Based on this research and changing management strategies, the value of early or easier diagnosis of fibrosis and diagnosis of the amount of fibrosis have become crucial.

Endomyocardial biopsy remains the gold standard for detecting fibrosis, although biochemical measurements and noninvasive imaging methods are critical in determining cardiac fibrosis. CMR has become the noninvasive gold standard method for detecting focal cardiac fibrosis since Wu et al. (4) Gradually, CMR is becoming more accessible and more frequently used in routine clinical practice. However, the disadvantage of CMR is that the interpretation requires experience and it is still expensive. Perhaps, cost-effective and less invasive evaluation of fibrosis could be advantageous in the early prediction of possible poor endpoints, which could provide an opportunity to benefit from new therapeutic approaches targeting fibrosis in HF. Hence, various biomarkers have been investigated in the literature to predict fibrosis. MMPs and their inhibitors (TIMP) are promising candidates for the treatment of patients with HF (16, 17). Our study reported that MMP-9 was significantly elevated in HF patients with ischemic cardiomyopathy who had cardiac fibrosis on CMR, and this increase positively correlated with the amount of fibrosis detected by CMR.

Fibrosis is associated with cardiac remodeling and structural changes in the myocardium; both cardiomyocytes and ECM are involved in these pathophysiological changes (18). In the ECM, MMPs play a major role in the pathophysiological changes during remodeling (19). The expression and activity of MMPs, especially MMP-2 and MMP-9, have been reported to be upregulated in patients with end-stage HF (20). In our study, MMP-9 correlated with fibrosis, and the MMP-9 level increase correlated with the increased left ventricular volumes in these patients. In addition, a significant correlation was found between the increased MMP-9 levels and decreased LVEF; this finding is, perhaps, because fibrosis is closely related to remodeling, which is the result of decreased LVEF and increased left ventricular volumes. Consistent with our study, Yan et al. (21) explored left ventricular remodeling in patients with chronic HF with plasma MMP levels and found that the plasma MMP-9 levels correlated with LVESV increment and LVEF reduction. In their study, volume and LVEF measurements were performed by radionuclide angiography. In our study, we performed volume and LVEF analyses by a noninvasive and radiation-free method of CMR.

MMP-9 has been explored in other cardiovascular diseases, except for HF. Indeed, MMP-9 was shown to be related to the increased risk of adverse cardiovascular events. Blankenberg et al. (22) reported that, when MMP-9 levels are increased, the risk of fatal cardiovascular event increases and MMP-9 could be a prognostic marker in patients with cardiovascular disease. In addition, Hlatky et al. (23) reported that elevated MMP-9 levels and genetic polymorphism could be related to acute myocardial infarction in patients with coronary artery disease. Furthermore, Jong et al. (24) stated that MMP-9 could be used as a diagnostic marker in post-myocardial infarction patients to predict the development of HF.

Study limitations

This study has some limitations worth acknowledging. First, this study had a small sample size and was a single-center re-

search. Moreover, because of ethical and economic reasons, CMR could not be performed on healthy individuals to build a control group; thus, this study had no control group. Second, MMP-9 is the only explored MMP in this study. Fibrosis is detected with a noninvasive imaging method, and biopsy was not possible in this study. Third, biomarkers of BNP and NTproBNP were not routinely used during follow-ups and diagnosis of these patients. Furthermore, as the study was not a long-term study, we could not gather patients' data in the long term and did not have adverse cardiovascular event rates in the study group.

Conclusion

This study establishes that MMP-9 significantly correlates with cardiac remodeling and increased left ventricular volumes, along with the presence of fibrosis in patients with HF. Thus, MMP-9 level monitoring could provide detailed information about cardiac remodeling and possible adverse outcomes. Perhaps, gaining a better understanding of MMPs and intervening the ECM restructuring could lead to different treatment strategies and treatment options in the near future. Hence, further investigations of MMP-9 and its inhibitors are warranted for the development of new cardiovascular treatments.

Conflict of interest: None declared.

Peer-review: Externally peer-reviewed.

Authorship contributions: Concept – Ö.Ç., S.S.; Design – Ö.Ç.; Supervision – Ö.Ç., A.A.Ş.; Fundings – Ö.Ç., S.S.; Materials – Ö.Ç., B.U.; Data collection and/or processing – Ö.Ç., A.A.Ş.; Analysis and/or interpretation – A.A.Ş.; Literature search – A.A.Ş.; Writing – A.A.Ş.; Critical review – Ö.Ç., B.U.

References

1. Francis GS, Tang WHW, Walsh RA. Pathophysiology of Heart Failure. Hurst's the Heart, 13th Edition. McGraw-Hill Education – Europe; 2013: p.719-26.
2. Reimer KA, Lowe JE, Rasmussen MM, Jennings RB. The wavefront phenomenon of ischemic cell death. 1. Myocardial infarct size vs duration of coronary occlusion in dogs. *Circulation* 1977; 56: 786-94.
3. St John Sutton M, Pfeffer MA, Moye L, Plappert T, Rouleau JL, Lamas G, et al. Cardiovascular death and left ventricular remodeling two years after myocardial infarction: baseline predictors and impact of long-term use of captopril: information from the Survival and Ventricular Enlargement (SAVE) trial. *Circulation* 1997; 96: 3294-9.
4. Wu KC, Weiss RG, Thiemann DR, Kitagawa K, Schmidt A, Dalal D, et al. Late gadolinium enhancement by cardiovascular magnetic resonance heralds an adverse prognosis in nonischemic cardiomyopathy. *J Am Coll Cardiol* 2008; 51: 2414-21. [CrossRef]
5. Hsia HH, Callans DJ, Marchlinski FE. Characterization of endocardial electrophysiological substrate in patients with nonischemic cardiomyopathy and monomorphic ventricular tachycardia. *Circulation* 2003; 108: 704-10. [CrossRef]
6. Thomas CV, Coker ML, Zellner JL, Handy JR, Crumbley AJ 3rd, Spinale FG. Increased matrix metalloproteinase activity and selective upregulation in LV myocardium from patients with end-stage dilated cardiomyopathy. *Circulation* 1998; 97: 1708-15. [CrossRef]
7. Wu E, Judd RM, Vargas JD, Klocke FJ, Bonow RO, Kim RJ. Visualization of presence, location, and transmural extent of healed Q-wave and non-Q-wave myocardial infarction. *Lancet* 2001; 357: 21-8.
8. Iles L, Pfluger H, Phrommintikul A, Cherayath J, Aksit P, Gupta SN, et al. Evaluation of diffuse myocardial fibrosis in heart failure with cardiac magnetic resonance contrast-enhanced T1 mapping. *J Am Coll Cardiol* 2008; 52: 1574-80. [CrossRef]
9. Ponikowski P, Voors AA, Anker SD, Bueno H, Cleland JGF, Coats AJS, et al.; ESC Scientific Document Group. 2016 ESC Guidelines for the diagnosis and treatment of acute and chronic heart failure: The Task Force for the diagnosis and treatment of acute and chronic heart failure of the European Society of Cardiology (ESC) Developed with the special contribution of the Heart Failure Association (HFA) of the ESC. *Eur Heart J* 2016; 37: 2129-200. [CrossRef]
10. Cerqueira MD, Weissman NJ, Dilsizian V, Jacobs AK, Kaul S, Laskey WK, et al.; American Heart Association Writing Group on Myocardial Segmentation and Registration for Cardiac Imaging. Standardized myocardial segmentation and nomenclature for tomographic imaging of the heart. A statement for healthcare professionals from the Cardiac Imaging Committee of the Council on Clinical Cardiology of the American Heart Association. *Circulation* 2002; 105: 539-42. [CrossRef]
11. Burch GE, Giles TD, Colcolough HL. Ischemic cardiomyopathy. *Am Heart J* 1970; 79: 291-2. [CrossRef]
12. Bilchick KC. The Fault Is in Our Scars: LGE and Ventricular Arrhythmia Risk in LV Dysfunction. *JACC Cardiovasc Imaging* 2016; 9: 1056-8. [CrossRef]
13. Disertori M, Rigoni M, Pace N, Casolo G, Masè M, Gonzini L, et al. Myocardial Fibrosis Assessment by LGE Is a Powerful Predictor of Ventricular Tachyarrhythmias in Ischemic and Nonischemic LV Dysfunction: A Meta-Analysis. *JACC Cardiovasc Imaging* 2016; 9: 1046-55. [CrossRef]
14. Cohn JN, Ferrari R, Sharpe N. Cardiac remodeling--concepts and clinical implications: a consensus paper from an international forum on cardiac remodeling. Behalf of an International Forum on Cardiac Remodeling. *J Am Coll Cardiol* 2000; 35: 569-82. [CrossRef]
15. Heusch G, Libby P, Gersh B, Yellon D, Böhm M, Lopaschuk G, et al. Cardiovascular remodelling in coronary artery disease and heart failure. *Lancet* 2014; 383: 1933-43. [CrossRef]
16. Antonov IB, Kozlov KL, Pal'tseva EM, Polyakova OV, Lin'kova NS. Matrix Metalloproteinases MMP-1 and MMP-9 and Their Inhibitor TIMP-1 as Markers of Dilated Cardiomyopathy in Patients of Different Age. *Bull Exp Biol Med* 2018; 164: 550-3. [CrossRef]
17. Wilson EM, Gunasinghe HR, Coker ML, Sprunger P, Lee-Jackson D, Bozkurt B, et al. Plasma matrix metalloproteinase and inhibitor profiles in patients with heart failure. *J Card Fail* 2002; 8: 390-8.
18. Jugdutt BI. Ventricular remodeling after infarction and the extracellular collagen matrix: when is enough enough? *Circulation* 2003; 108: 1395-403. [CrossRef]
19. Coker ML, Thomas CV, Clair MJ, Hendrick JW, Krombach RS, Galis ZS, et al. Myocardial matrix metalloproteinase activity and abundance with congestive heart failure. *Am J Physiol* 1998; 274: H1516-23. [CrossRef]
20. Reinhardt D, Sigusch HH, Hensse J, Tyagi SC, Körfer R, Figulla HR. Cardiac remodelling in end stage heart failure: upregulation of matrix metalloproteinase (MMP) irrespective of the underlying dis-

- ease, and evidence for a direct inhibitory effect of ACE inhibitors on MMP. *Heart* 2002; 88: 525-30. [\[CrossRef\]](#)
21. Yan AT, Yan RT, Spinale FG, Afzal R, Gunasinghe HR, Arnold M, et al. Plasma matrix metalloproteinase-9 level is correlated with left ventricular volumes and ejection fraction in patients with heart failure. *J Card Fail* 2006; 12: 514-9. [\[CrossRef\]](#)
 22. Blankenberg S, Rupprecht HJ, Poirier O, Bickel C, Smieja M, Hafner G, et al.; AtheroGene Investigators. Plasma concentrations and genetic variation of matrix metalloproteinase 9 and prognosis of patients with cardiovascular disease. *Circulation* 2003; 107: 1579-85. [\[CrossRef\]](#)
 23. Hlatky MA, Ashley E, Quertermous T, Boothroyd DB, Ridker P, Southwick A, et al.; Atherosclerotic Disease, Vascular Function and Genetic Epidemiology (ADVANCE) Study. Matrix metalloproteinase circulating levels, genetic polymorphisms, and susceptibility to acute myocardial infarction among patients with coronary artery disease. *Am Heart J* 2007; 154: 1043-51. [\[CrossRef\]](#)
 24. Jong GP, Ma T, Chou P, Chang MH, Wu CH, Lis PC, Lee SD, Liu JY, Kuo WW, Huang CY. Serum MMP-9 activity as a diagnosing marker for the developing heart failure of post MI patients. *Chin J Physiol* 2006; 49: 104-9.