

stress as a triggering factor is more common in women. Some points in the patient's history and clinical features could differentiate Takotsubo syndrome from myocarditis: stressful trigger vs. viral illness, females >50 year old vs. involvement of young adults, rarely normal ECG changes vs. normal ECG findings in several cases, low or moderate rise in troponin vs. frequent rise in troponin, usually absent LGE in the acute phase vs. non-ischemic late gadolinium enhancement (LGE) pattern (usually subepicardial), usually absent vs. often positive viral genome. These conditions are observed while comparing Takotsubo syndrome and myocarditis, respectively (1).

The unique features of stress cardiomyopathy observed in MRI are myocardial edema and remarkable LV ballooning combined with the absence of significant LGE (2).

Although Takotsubo syndrome typically involves the LV apex, there are atypical forms such as LV basal or RV involvement. Proposed mechanisms are catecholamine hyperactivity, multivessel coronary spasm, microvascular dysregulation, and estrogen deficit. The prominent role of catecholamines in this syndrome increases the possible treatment efficacy of sympathectomy and sympathetic blocks. A lower prevalence of Takotsubo syndrome in the diabetic population supports this theory because of the autonomic dysfunction in diabetics (3).

Takotsubo syndrome is the final diagnosis in approximately 2% of patients with ACS presentation. Cardiac troponin levels are lower in this syndrome than in myocardial infarction, whereas the BNP levels are higher in this syndrome than in myocardial infarction.

LGE in myocarditis has a patchy distribution, whereas LGE is usually absent in Takotsubo (4). Some reports have shown that the known cardiovascular risk factors may be less obvious in the Takotsubo syndrome, whereas mental or neurologic disorders may be more prominent in the past medical history of patients (5).

Conclusion

The age and sex of our patient, history of depression, the absence of late gadolinium enhancement in MRI, and complete resolution of disease markers after 2 weeks were in the favor of recovery from Takotsubo syndrome.

Informed consent: The informed consent was obtained from the patient.

Video 1. Steady state free precessions cine image in 4 chamber view shows dyskinesia and apical ballooning with well preserved contractility of basal segments.

References

1. Lyon AR, Bossone E, Schneider B, Sechtem U, Citro R, Underwood SR, et al. Current state of knowledge on Takotsubo syndrome: a

Position Statement from the Taskforce on Takotsubo Syndrome of the Heart Failure Association of the European Society of Cardiology. *Eur J Heart Fail* 2016; 18: 8-27.

2. Eitel I, von Knobelsdorff-Brenkenhoff F, Bernhardt P, Carbone I, Muellerleile K, Aldrovandi A, et al. Clinical characteristics and cardiovascular magnetic resonance findings in stress (takotsubo) cardiomyopathy. *JAMA* 2011; 306: 277-86.
3. Gowdar S, Syal S, Chhabra L. Probable protective role of diabetes mellitus in takotsubo cardiomyopathy: a review. *Vessel Plus* 2017; 1: 129-36.
4. Scantlebury DC, Prasad A. Diagnosis of Takotsubo cardiomyopathy. *Circ J* 2014; 78: 2129-39.
5. Dawson DK. Acute stress-induced (takotsubo) cardiomyopathy. *Heart* 2018; 104: 96-102.

Address for Correspondence: Maryam Chenaghlu, MD,

Department of Heart Failure and Transplantation,
Rajaie Cardiovascular Medical and Research Center,
Iran University of Medical Sciences;
Valiasr Ave,

Hashemi Rafsanjani Blvd,

Tehran-Iran

Phone: +09144012182

E-mail: mchenaghlu@yahoo.com

©Copyright 2020 by Turkish Society of Cardiology - Available online
at www.anatoljcardiol.com

DOI:10.14744/AnatolJCardiol.2020.45773



Giant right sinus of Valsalva aneurysm led to proximal right coronary artery occlusion

Ke Wei, Hongwei Guo, Fang Fang, Xiang-yang Qian
Department of Vascular Surgery, Fuwai Hospital, National Center for Cardiovascular Diseases, Chinese Academy of Medical Sciences and Peking Union Medical College; Beijing-China

Introduction

Coronary artery stenosis or occlusion due to sinus of Valsalva aneurysm (SVA) is rare, while SVA leading to right coronary artery occlusion is extremely rare (1-3). We present a case of a giant right SVA combined with proximal right coronary obstruction, wherein good results were achieved in the patient with early surgical intervention.

Case Report

A 56-year-old male was admitted to our hospital with a 6-month history of shortness of breath and palpitation following physical exertion. Transthoracic echocardiography revealed a giant right SVA. The aortic valve was tricuspid with trivial aortic regurgitation and the ascending and descending aorta were

within normal limits. The bi-dimensional images confirmed the presence of a right coronary sinus aneurysm with maximum dimensions of 56.82 mm×49.67 mm (Fig. 1). A computed tomography (CT) scan showed the giant right SVA. The proximal right coronary artery (RCA) was not visible, whereas the middle and distal RCA were clearly visible (Fig. 2a-2c). Electrocardiogram was normal.

Surgery was performed through a median sternotomy. Cardiopulmonary bypass was established by ascending aorta, superior vena cava, and inferior vena cava cannulation with left heart venting through the atrial septum. A giant SVA was observed at the right sinus (Fig. 3a). After cross-clamping the ascending aorta, cardioplegia solution was infused through the ascending aorta. The ascending aorta was opened at the border of the SVA and normal ascending aorta. The SVA involved the total right sinus, protruded forward and downward, and the orifice of the RCA could not be found inside (Fig. 3b). The proximal RCA on the SVA was occluded and the proximal RCA on the atrioventricular groove had a small lumen and a very thin wall. The middle RCA on the atrioventricular groove was normal. Coronary artery bypass to the middle RCA was performed immediately with greater saphenous vein (GSV) grafting, and cardioplegia solution was infused through the GSV graft (Fig. 3c). The right sinus was reconstructed with a vascular prosthesis patch ranging from the aortic annulus to the normal ascending aorta and from commissure to commissure (Fig. 3c). The proximal GSV graft was anastomosed to the normal ascending aorta. The cardiopulmonary bypass time was 148 min and cross-clamp time was 108 min.

The duration of mechanical ventilation support was 27.25 h. The patient's duration of stay in the intensive care unit was 89.83 h. The patient's recovery was uneventful. He was discharged from the hospital 6 days after surgery. A postoperative CT scan showed good aortic root morphology (Fig. 2b, 2d).

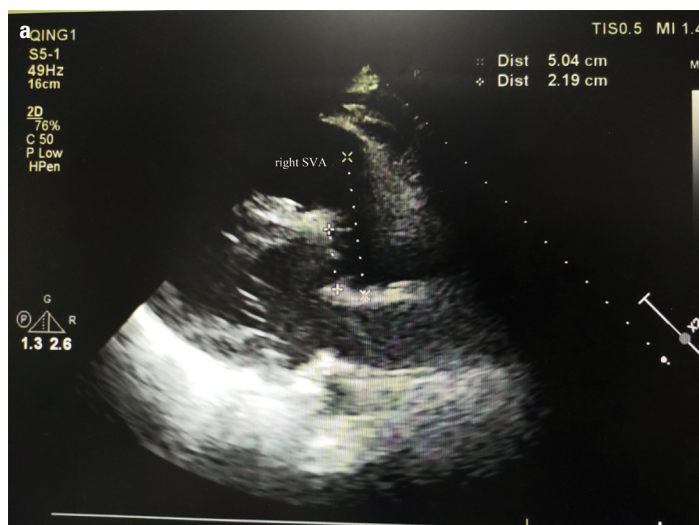


Figure 1. Transthoracic echocardiography showing (a) a giant right SVA, parasternal short axis view at great vessels level, (b) aneurysm measuring: 56.82 mm×49.67 mm
SVA - sinus of Valsalva aneurysm

Discussion

An unruptured SVA is usually asymptomatic in early years with symptoms typically manifesting between 30 and 45 years of age (4). During its expansion, it could cause obstruction of the right ventricular outflow tract, aortic regurgitation, conduction disorders, and more rarely, myocardial ischemia due to compression of the coronary arteries.

The reduction of coronary flow due to SVA compression is a rare condition and may lead to myocardial ischemia or infarction. Approximately 70% of SVAs occur in the right coronary sinus, 29% in the non-coronary sinus, and only 1% in the left coronary sinus (5). However, according to the literature, there is more risk of myocardial ischemia with left SVA than with right SVA (6). This may be

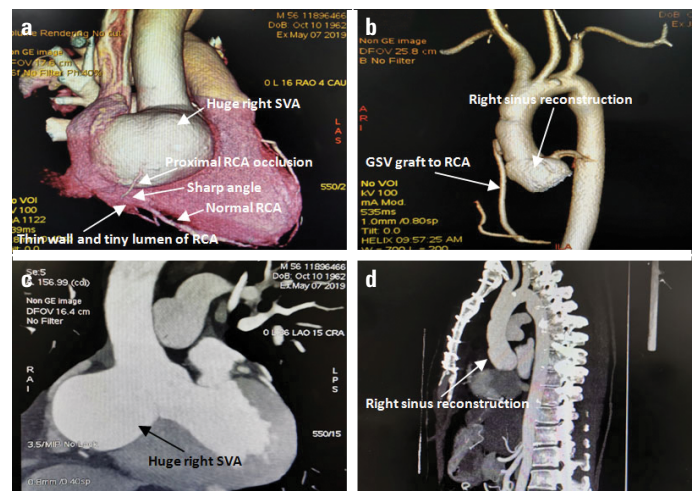


Figure 2. Preoperative and postoperative CT scan showing (a) Giant right SVA with proximal RCA occlusion, (b) Right sinus reconstruction and coronary artery bypass grafting to RCA, (c) Giant right SVA, (d) Right sinus reconstruction
SVA - sinus of Valsalva aneurysm; RCA - right coronary artery

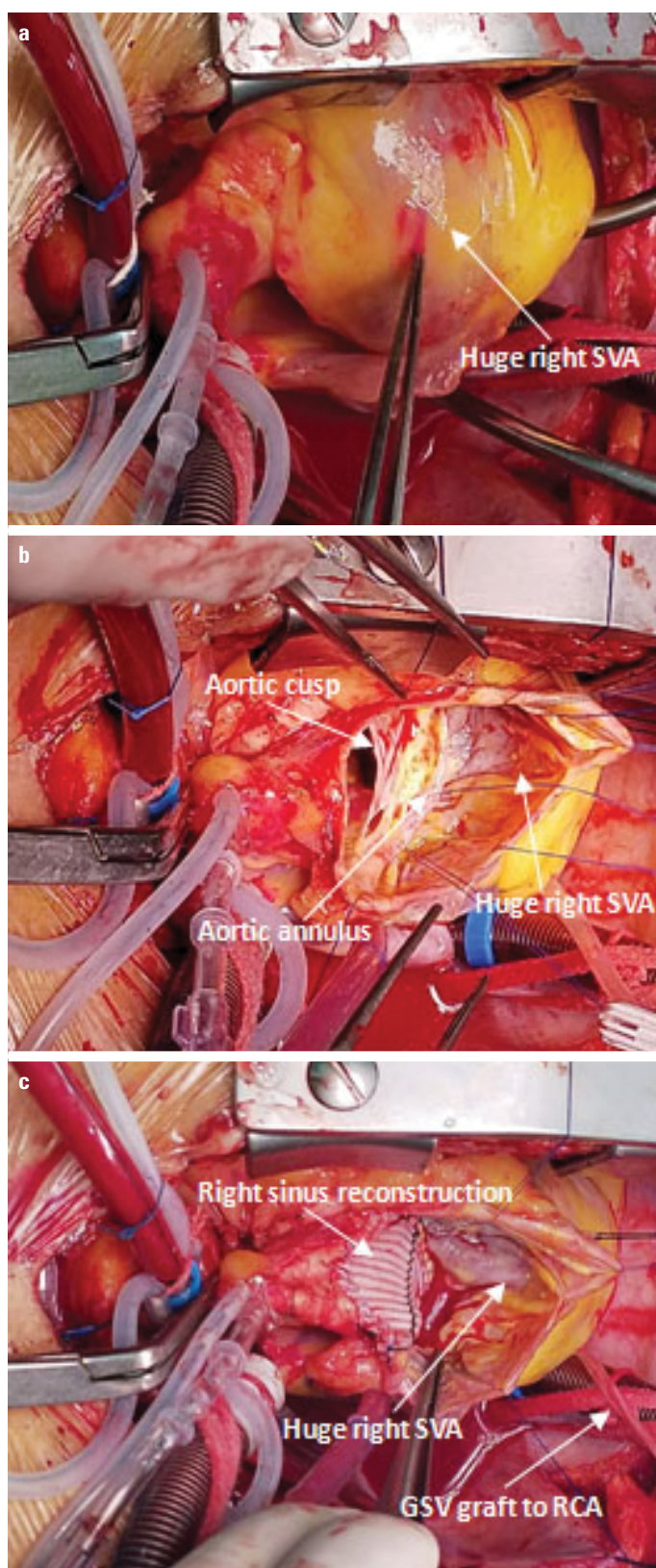


Figure 3. Intraoperative images. (a) Giant SVA, (b) SVA involving the total right sinus, (c) Right sinus reconstruction with a vascular prosthesis patch and coronary artery bypass grafting with GSV graft to RCA
SVA - sinus of Valsalva aneurysm; GSV - greater saphenous vein;
RCA - right coronary artery

associated with the space structure of the proximal left coronary artery, surrounded by the SVA, left atrium, and pulmonary trunk, whereas proximal RCA has more space to compensate for SVA compression. According to a collective review of the literature, the mechanism of coronary obstruction due to SVA is considered to be initiated by hyperextension of the coronary artery due to the bulge in the sinus of Valsalva. The coronary artery obstruction is caused by a thrombus within the aneurysm (7, 8). Most patients of SVA-associated coronary obstruction undergo coronary artery bypass grafting to guarantee a distal myocardial perfusion, despite the fact that there are reports of the successful treatment with SVA repair alone (9). In our case, giant right SVA led to occlusion of proximal RCA. Our viewpoint regarding the mechanism of SVA-associated coronary obstruction is novel. We believe that the right SVA expanded gradually, which may have made proximal RCA form a sharp angle, resulting in coronary flow reduction and proximal RCA occlusion. The proximal RCA on the atrioventricular groove had a small lumen and very thin wall due to this reduction in flow. The middle and distal RCA had normal lumen due to collateral circulation compensatory (Fig. 2a).

Conclusion

Surgery was performed to reconstruct right sinus with a vascular prosthesis patch and coronary artery bypass grafting with GSV to the middle RCA. The patient, reported herein, successfully recovered after surgical treatment with good early results. However, continued follow-up is required for long-term results.

Informed consent: Written informed consent was obtained from this patient.

References

1. Kazuno K, Nakanishi S, Ohtani N. Extra cardiac unruptured aneurysm of the right sinus of Valsalva with aortic regurgitation and right coronary ostial stenosis; report of a case. *Kyobu Geka* 2013; 66: 237-40.
2. Shimoyama T, Hirooka K, Ohnuki M, Nagaoka H. A case of extracardiac unruptured aneurysm of sinus of Valsalva with obstruction of the right coronary artery and aortic regurgitation. *Kyobu Geka* 2001; 54: 1045-8.
3. Sumiyoshi A, Fujii K, Hao H, Shibuya M, Imanaka T, Miki K, et al. Right Sinus of Valsalva Aneurysm Causing Acute Myocardial Infarction. *Circ J* 2015; 79: 2720-2. [CrossRef]
4. Moustafa S, Mookadam F, Cooper L, Adam G, Zehr K, Stulak J, et al. Sinus of Valsalva aneurysms--47 years of a single center experience and systematic overview of published reports. *Am J Cardiol* 2007; 99: 1159-64. [CrossRef]
5. Fang ZF, Huang YY, Tang L, Hu XQ, Shen XQ, Tang JJ, et al. Long-term outcomes of transcatheter closure of ruptured sinus valsalva aneurysms using patent ductus arteriosus occluders. *Circ J* 2014; 78: 2197-202. [CrossRef]
6. Regueiro Abel M, Penas Lado M, López Ciudad V, Castro Beiras A. Sinus of Valsalva aneurysm as a cause of acute myocardial infarction. *Rev Esp Cardiol* 2002; 55: 77-9. [CrossRef]

7. Brandt J, Jögi P, Lührs C. Sinus of Valsalva aneurysm obstructing coronary arterial flow: case report and collective review of the literature. *Eur Heart J* 1985; 6: 1069-73. [CrossRef]
8. Sumiyoshi A, Fujii K, Hao H, Shibuya M, Imanaka T, Miki K, et al. Right Sinus of Valsalva Aneurysm Causing Acute Myocardial Infarction. *Circ J* 2015; 79: 2720-2. [CrossRef]
9. Lijoi A, Parodi E, Passerone GC, Scarano F, Caruso D, Iannetti MV. Unruptured aneurysm of the left sinus of Valsalva causing coronary insufficiency: case report and review of the literature. *Tex Heart Inst J* 2002; 29: 40-4.

Address for Correspondence: Hongwei Guo, MD,

Department of Vascular Surgery,
Fuwai Hospital,

National Center for Cardiovascular Diseases,
Chinese Academy of Medical Sciences and
Peking Union Medical College;

Xicheng Qu, No.167,
Beilishi Lu 100037,

Beijing-China

Phone: +8618801140229

E-mail: ghwdr@sina.com

©Copyright 2020 by Turkish Society of Cardiology - Available online

at www.anatoljcardiol.com

DOI: 10.14744/AnatolJCardiol.2020.10305



Acute anterior myocardial infarction during myopericarditis treatment in a very young adult

Alparslan Kurtul, Fatih Şen, Özkan Bekler

Department of Cardiology, Faculty of Medicine, Hatay Mustafa Kemal University; Hatay-Turkey

Introduction

Patients aged less than 40 years old only account for 1.2% of all patients with acute myocardial infarction (AMI) (1). Several studies as well as meta-analyses have revealed that the use of non-steroidal anti-inflammatory drugs (NSAIDs) can be associated with an increased relative risk of AMI in patients with or without heart disease or other risk factors for coronary artery disease (2-7). Diclofenac and ibuprofen, the most frequently used NSAIDs, are associated with a 40%–50% increased relative risk of AMI, even for low cumulative NSAID amounts (8). The AMI risk in patients with and without cardiovascular risk factors showed a similar elevation (8). The present paper reports an exceedingly rare presentation of AMI in a very young male associated with acute myopericarditis treatment.

Case Report

A 21-year-old man with no prior medical history presented to the emergency department with a 10 hour history of chest pain

suggesting pericarditis. Patient presented with ST segment elevations without reciprocal depression and PR-segment depressions on a 12-lead electrocardiography (ECG) (Fig. 1a) with increased cardiac enzyme levels (cardiac troponin level at admission time was 1.936 ng/mL and two days later peak troponin level was 8.559 ng/mL). The patient smoked 1–2 cigarettes per day for 10 years, but denied illicit drug or alcohol abuse. He had no atherosclerotic coronary artery disease risk factors (family history, hyperlipidemia, etc.) apart from active smoking. Physical examination showed no abnormal findings. He had a history of viral upper respiratory tract infection 1 week ago. Given the age of the patient and characteristics of the chest pain (sitting up and leaning forward tends to ease the pain, while lying down and breathing deep worsens it), acute myopericarditis was initially assumed. At the time of admission, transthoracic echocardiography revealed that left ventricular ejection fraction (LVEF) was 60% and no abnormality was found in segmental wall motion. Left ventricular diameter in diastole measured in the normal range (4.8 cm). Minimal circumferential pericardial effusion was present. However, urgent diagnostic coronary angiography was performed due to persistent, severe chest pain, current risk factor (active smoking) and high cardiac troponin levels. Coronary angiography indicated a noncritical plaque in the left anterior descending (LAD) coronary artery (Fig. 1-b1 and 1-b2-white arrowhead). Right and Left circumflex coronary arteries were normal (Fig. 1-b2, 1-b3). A diagnosis of acute myopericarditis was made and the patient was treated with colchicine, ibuprofen, and proton-pump inhibitor (omeprazole) throughout hospitalization. On the fourth hospital day, the patient's symptoms largely subsided. During the hospitalization period, troponin levels decreased progressively and the patient was discharged asymptomatic with prescriptions for colchicine, ibuprofen, and omeprazole for continued usage.

Ten days after discharge, the patient was admitted to the emergency department again with chest pain at rest spreading to the left arm while he was still taking the prescribed medication. The patient's chest pain was an ischemic type, contrasting with his previous pain on the previous visit, accompanied by cold sweating. The ECG on admission indicated acute anterior wall myocardial infarction (MI) (Fig. 2a). The patient was immediately taken to the catheter laboratory and a second coronary angiography revealed 100% thrombotic occlusion in the LAD-proximal region. After thrombus aspiration, 2 consecutive drug-eluting stents were implanted due to severe thrombotic residues and dissection. Complete opening and distal TIMI-3 flow were achieved after the procedure (Fig. 2-b1 - 2-b3). At second admission, the echocardiogram revealed segmental (septum, mid-anterior, apical) wall motion dysfunction of left ventricular origin with a decreased LVEF, 45%. Treatments consisted of double antiplatelets (aspirin and ticagrelor), ACE inhibitor (perindopril), beta-blocker (metoprolol) and lipid-modulating (atorvastatin) drugs. Four days later he was discharged without any complications.

Two and a half months after discharge, the patient was admitted to the emergency department again with constricting