

## A Case Report: Rhabdomyoma Caused Right Ventricular Outflow Tract Obstruction in an Infant

Sevcan Erdem MD, Osman Küçükosmanoğlu MD, \*O. Kemal Salih MD, \*Hakan Poyrazoğlu MD

\*\*Şeyda Erdoğan MD, \*\*Nurdan Tunalı MD, Nazan Özbarlas MD.

Çukurova University Medical Faculty, Department of Pediatric Cardiology,

\* Department of Cardiovascular Surgery, and \*\* Department of Pathology - Adana-Turkey

### Introduction

Intracardiac tumours are very rarely seen in infants and childhood but rhabdomyomas are the most common primary cardiac tumour in this age group. More than 50 percent of patients with cardiac rhabdomyomas had tuberous sclerosis (1, 2).

We report the case of a 12-days-old boy presenting with right ventricular outflow obstruction caused by rhabdomyoma which was detected by echocardiography.

### Case Report

A twelve-days-old boy was referred to our clinic for evaluation of a systolic murmur. This infant was born at term by normal delivery. A precordial murmur was heard shortly after birth. There was no family history of tuberous sclerosis, seizure disorders, mental retardation or congenital heart disease. The first and second heart sounds were normal and a grade 3/6 systolic ejection murmur was audible, maximally at the upper left sternal border. Electrocardiogram showed sinus rhythm with right axis deviation. The T waves in the right precordial leads were upright. The chest x-ray was normal. Two-dimensional echocardiography revealed a highly mobile echodense mass which was 9x8 mm in size. The mass protruded into the pulmonary valve orifice during systole (Fig. 1). Doppler technique indicated a right ventricular outflow tract velocity of abo-

ut 4.0 m/s which was correspondent to a peak gradient of about 65 mmHg.

Surgery was performed without cardiac catheterization. After sternotomy and pericardiotomy, pulmonary artery was opened. A white pedunculated subvalvular tumour adherent to the posterior leaflet of pulmonary valve, was found arising in the right ventricular outflow tract free wall. It was resected together with posterior leaflet of pulmonary valve (Figure 2).

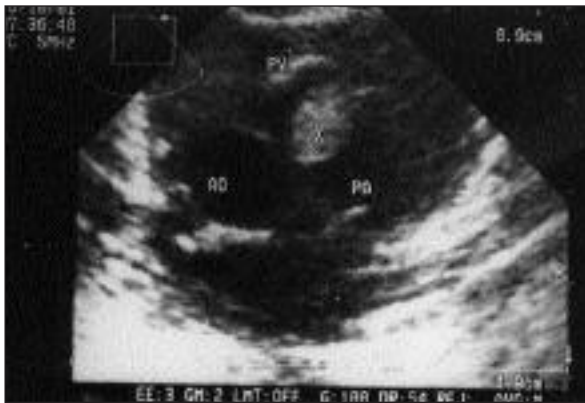Diagnosis of rhabdomyoma was established by histologic examination of surgical specimen. The tumour contained large vacuolated cells. Typical 'spider' cells were seen with eccentric nuclei, granular cytoplasm and thin cytoplasmic extensions projecting toward the cell membrane (Figure 3).

The patient had an uneventful postoperative recovery. Cerebral computed tomography was normal. At 10-months follow up, the child was completely well and his physical and echocardiographic examinations were normal (Figure 4).

### Discussion

Diagnosis of tumour was made by echocardiography but the diagnosis of rhabdomyoma was made by histologic examination in this case. Because myxomas may have a similar appearance on echocardiography they also should be taken in account. However myxomas are most commonly seen in the adult population and rarely they have been described in children including neonates.

In generally, rhabdomyomas are intramural nodules that can occur anywhere within the heart, most commonly involving the ventricular and septal



**Figure 1-** Preoperative echocardiogram. Parasternal short axis view shows a tumour mass obstructing the right ventricular outflow tract. (PA: Pulmonary artery, Ao: Aorta, X: Tumour mass, PV: Pulmonary valve).

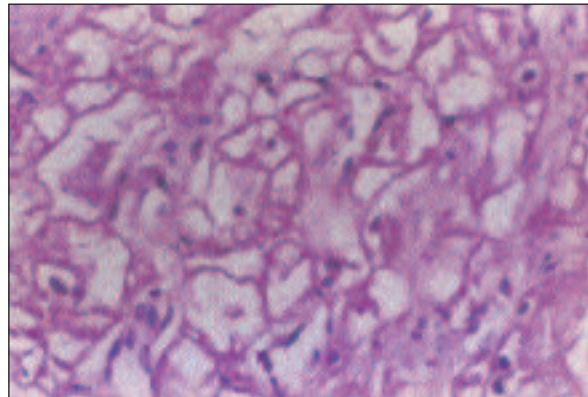


**Figure 2-** Gross features of rhabdomyoma removed during operation..

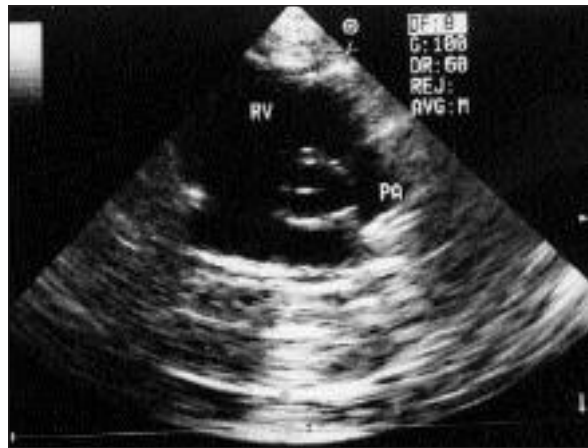
walls. They can occur as single intramural or intracavitary masses in 10% of patients. Occasionally rhabdomyoma causes obstruction to blood flow as our in case (1-7).

As many as 50% of children with rhabdomyoma have tuberous sclerosis; 50% of children with tuberous sclerosis have rhabdomyomas (1, 2). In our case, although there was no family history of tuberous sclerosis and cerebral computed tomography was normal we have to follow up the patient for tuberous sclerosis. Because the nodules of tuberous sclerosis can be microscopic they could not be detected and brain may appear normal by computed tomography.

Rhabdomyomas can regress spontaneously in infants and children (1, 2, 3, 8, 9). Farooki et al. (8) have found that these tumours tend to regress at a constant rate such that the circumference decreases by approximately 2 mm/month. However we



**Figure 3-** Microscopic section of lesion shows typical 'spider' cells (Hematoxylin-eosin stain X 400).



**Figure 4-** Postoperative echocardiogram. The relief of right ventricular outflow tract obstruction is seen.

could not wait for spontaneous regression because of presence of the significant outflow tract obstruction and the mobility of the mass and patient was referred for surgery.

## References

1. Marx GR, Moran MA. Cardiac tumors. In: Allen HD, Gutgesell HP, Clark EB, editors. Moss and Adams' Heart Disease in Infant, Children and Adolescents. 6th edition. Philadelphia: Lippincott Williams and Wilkins; 2000. p. 1435-7.
2. Fyler DC. Cardiac tumors. In: Fyler DC, editor. Nadas' Pediatric Cardiology. Philadelphia: Hanley and Belfus; 1992. p. 727-30.
3. Freedom RM, Lee KJ, Mac Donald C, Taylor G. Selected aspects of cardiac tumors in infancy and childhood. *Pediatr Cardiol* 2000; 21: 299-316.
4. Milner S, Abramowitz JA, Levin SE. Rhabdomyoma of the heart in a new-born infant diagnosis by echocardiography. *Br Heart J* 1980; 44: 224-7.

5. Stern MJ, Cohen MV, Fish B, Rosenthal R. Clinical presentation and noninvasive diagnosis of right heart masses. *Br Heart J* 1981; 46: 552-8.
6. Doministic DE, Frigiola A, Thiene G, Meniconi L, Bazzola L, Finocci G. Subaortic stenosis by solitary rhabdomyoma, successful excision in an infant following 2D echocardiogram and Doppler diagnosis. *Chest* 1977; 71: 102-6.
7. Pillai R, Kharma N, Brom G, Becker AE. Mitral valve origin of pedunculated rhabdomyomas causing subaortic stenosis. *Am J Cardiol* 1991; 67: 663-4.
8. Farooki ZQ, Ross RD, Paridon SM, Humes RA, Karpovich PP, Pinsky WW. Spontaneous regression of cardiac rhabdomyoma. *Am J Cardiol* 1991; 67: 897-9.
9. Ross RD, Farooki ZQ. Medical versus surgical management of intracardiac rhabdomyomas. *Am J Cardiol* 1991; 68: 836.



Gönül Erenberk

Osmangazi Üniversitesi Sanat Galerisi