

- cents without structural heart disease. Pediatric EP Society, Radiofrequency Catheter Ablation Registry. Am J Cardiol 1997; 80: 1438-43. [CrossRef]
9. Paul T, Bökenkamp R, Mahnert B, Trappe HJ. Coronary artery involvement early and late after radiofrequency current application in young pigs. Am Heart J 1997; 133: 436-40. [CrossRef]
10. Tuzcu V. Cryoablation of accessory pathways in children. Pacing Clin Electrophysiol 2007; 30: 1129-35. [CrossRef].

Yazışma Adresi/Address for Correspondence: Dr. Celal Akdeniz
T.C. Sağlık Bakanlığı, İstanbul Mehmet Akif Ersoy, Kalp Damar Cerrahisi Eğitim ve Araştırma Hastanesi, Pediatrik Kardiyoloji Kliniği, İstanbul- Türkiye
Tel: +90 216 542 44 44 E-posta: celalakdeniz@yahoo.com

Çevrimiçi Yayın Tarihi/Available Online Date: 16.05.2012

©Telif Hakkı 2012 AVES Yayıncılık Ltd. Şti. - Makale metnine www.anakarder.com web sayfasından ulaşılabilir.

©Copyright 2012 by AVES Yayıncılık Ltd. - Available on-line at www.anakarder.com
doi:10.5152/akd.2012.131

Transcatheter antegrade perforation and covered stent implantation to subatretic coarctation

Subatretik aort koarktasyonuna transkateter antegrad perforasyon ve kaplı stent yerleştirilmesi

Introduction

Subatretic coarctation is a complex form of aortic coarctation (CoA) with complete luminal obliteration (1-3). Surgical treatment of CoA has been performed successfully since 1940s. Nowadays balloon angioplasty and stent implantation are popular because transcatheter techniques for treatment of CoA are effective, with low morbidity and mortality rates (4, 5). Although endovascular stent implantation has risks and limitations in infants, stents currently are used routinely to dilate and support both native and recoarctations of children over 25 kg (6).

In this report, a child with discrete CoA who had diagnosed subatretic coarctation and successfully treated with wire perforation of luminal obstruction followed covered stent implantation is presented.

Case Report

An 8-year-old boy presented for heart murmur. Physical examination revealed a regular pulse rate of 76/min but weakened femoral pulse. Blood pressure in upper and lower extremities were 140/100, and 119/88 mmHg respectively. There was a 3/6 degree systolic murmur at left upper sternal border and interscapular area. There was a left axis deviation on electrocardiography. Chest radiography demonstrated dilatation of ascending aorta. Transthoracic echocardiography demonstrated dilatation of ascending aorta, left ventricular hypertrophy, bicuspid aortic valve, and collaterals flow at descending aorta. Gradient could not be measured on coarctation level. Interruption impression at descending thoracic aorta was taken.

Catheterization procedure was performed under continuous sedation. 6-Fr sheath was introduced to common right femoral artery. For antegrade access left axillary artery was used. Angiography revealed

subatretic CoA (Fig. 1). There were 30 mmHg pressure differences between proximal and distal ends of interruption. Luminal obstruction was perforated with 0.035 Terumo® guidewire firstly with strict end and then with soft end gently via antegrade way. Guidewire was kept with snare catheter and removed from femoral artery. Then arcus aorta angiography was performed, but predilatation was not applied (Fig. 2). The 12F long sheaths were placed into the CoA, and 28 mm covered Cheatham Platinum stent was advanced over the wire and 12 mm balloon-in-balloon was inflated slowly at the CoA site (Fig. 3 and Video 1. See corresponding video/movie images at www.anakarder.com). CoA did not reoccur in the first year follow-up.

Discussion

Aortic coarctation has been estimated to constitute 7% of congenital heart disease. Surgical treatment of CoA was described for the first time in 1945. Later, percutaneous balloon angioplasty was performed in 1982. In 1993 the first stent implantation into CoA was accessed in clinical practice, and this method has become widely used in all age groups nowadays (2, 6-8).

Subatretic CoA is due to progressive aortic lumen obliteration of developing postnatal life and an unusually severe form of discrete CoA. When aorta is totally occluded surgical repair is undisputed and universally recommended (2, 3). Treatment of complex CoA is difficult and surgery was the first choice (5). However, surgical repair of complex CoA can be hazardous in regard to hemostatic control of large intercostal arteries; furthermore, post-repair paraplegia risk is greater than in simple CoA (9).

Case reports suggest that subatretic coarctation, can be perforated with stiff guidewire, thus creating neo-aortic lumen, and then it is possible to be treated by stent placement. In literature, carefully directed perforation of the obstruction utilizing a coronary wire and creation of a neo-aortic lumen, followed by balloon angioplasty and stent placement, successfully relieving the CoA in adolescents and adults was described (2, 3). In this report, the patient was eight year old, and was

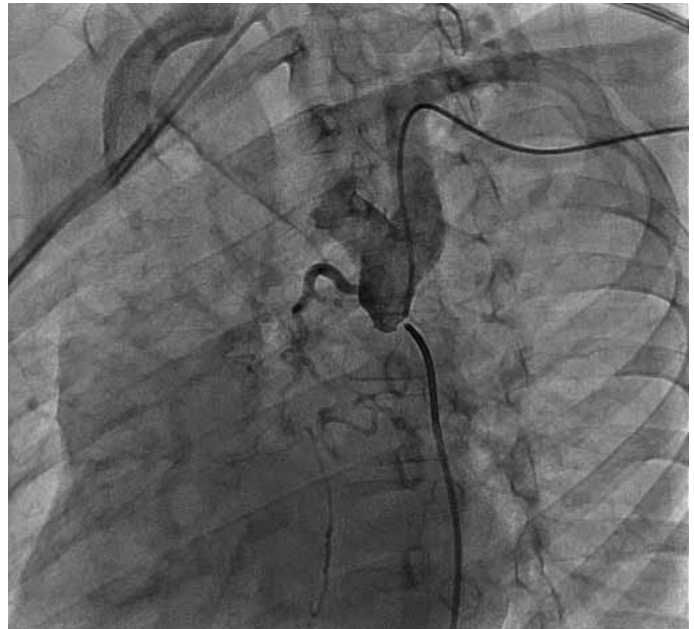


Figure 1. Angiography at proximal end of stenosis revealed subatretic segment and collateral vessels

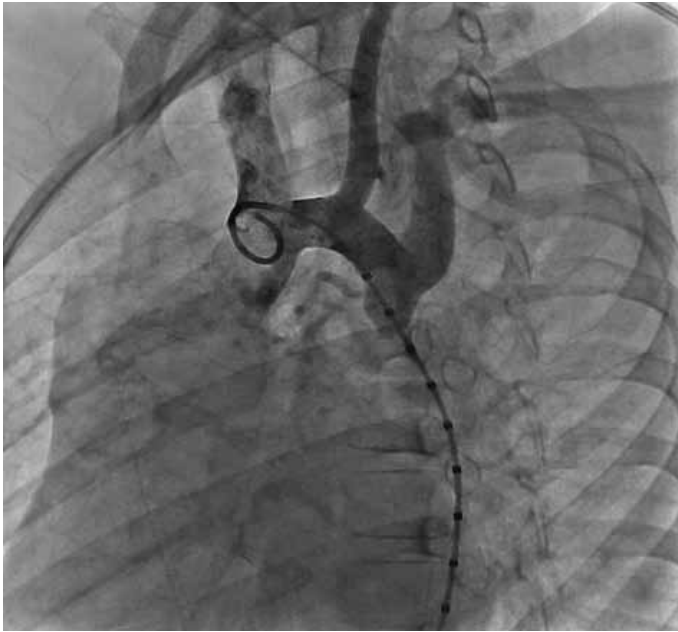

Figure 2. Retrograde contrast injection reveals no contrast pass from coarctation

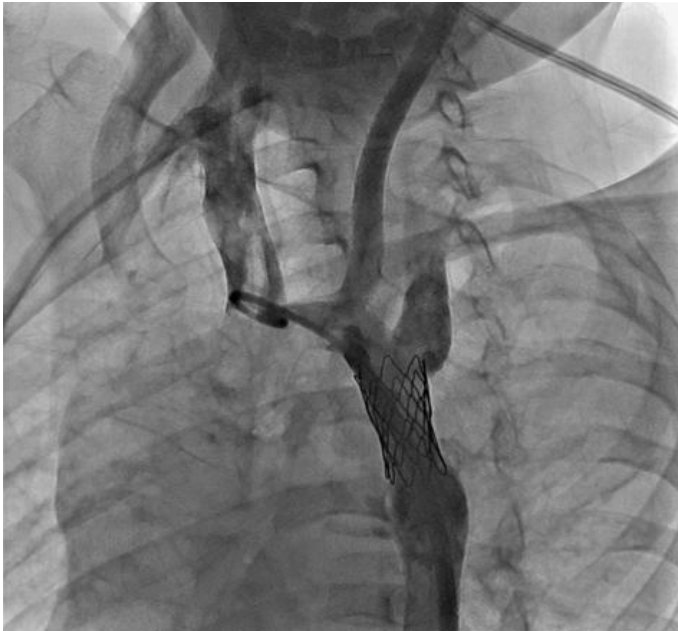

Figure 3. Final aortogram showing successful dilatation of interruption, with no residual gradient

one of the youngest patients presented in the literature. The luminal obstruction of aorta was perforated with Terumo guidewire and a new aortic lumen was created, then the stent was implanted working diligently. During this procedure, firstly we should perform an angioplasty with coronary angioplasty balloon to dilate the passage, but it was not needed because the catheter and long sheath were placed easily. The short- and medium-term results of the procedure were excellent.

Wire perforation of luminal obstruction at CoA is effective to creating a new lumen, but has been found to have a high incidence of aortic complications such as vessel wall injury or disruption, which needs urgent surgery.

Conclusion

Percutaneous treatment brings to the fore with the advances in imaging techniques, devices and methods used in. The increase of the experience of interventional cardiologists has allowed treating complex CoA with stents. With this report, it was declared that a child with subatretic CoA could be treated by percutaneous intervention.

Acknowledgement

The authors would like to thank Dr. Kazım Üzüm for contribution in case's diagnosis, treatment and preparation of manuscript.

Nazmi Narin, Sertaç Hanedan Onan, Ali Baykan, Sadettin Sezer
Department of Pediatric Cardiology, Faculty of Medicine, Erciyes University, Kayseri-Turkey

Video 1.

- Retrograde and antegrade angiography revealed subatretic coarctation
- Antegrade entry to distal site and snaring the guidewire from femoral artery
- Introducing long sheath and deployment of 28 mm covered Cheatham Platinum stent. Ballooning with 12 mm balloon-in-balloon and flaring the proximal end with two separate balloons

References

1. Ewert P, Abdul-Khaliq H, Peters B, Nagdyman N, Schubert S, Lange PE. Transcatheter therapy of long extreme subatretic aortic coarctations with covered stents. *Catheter Cardiovasc Interv* 2004; 63: 236-9. [CrossRef]
2. Musso TM, Slack MC, Nowlen TT. Balloon angioplasty with stenting to correct a functionally interrupted aorta: A case report with three-year follow-up. *Catheter Cardiovasc Interv* 2008; 72: 87- 92.
3. Ewert P, Schubert S, Peters B, Abdul-Khaliq H, Nagdyman N, Lange PE. The CP stent-short, long, covered-for the treatment of aortic coarctation, stenosis of pulmonary arteries and caval veins, and Fontan anastomosis in children and adults: an evaluation of 60 stents in 53 patients. *Heart* 2005; 91: 948-53. [CrossRef]
4. Horvath R, Towgood A, Sandhu SK. Role of transcatheter therapy in the treatment of coarctation of the aorta. *J Invasive Cardiol* 2008; 20: 660-3.
5. Butera G, Piazza L, Chessa M, Negura DG, Rosti L, Abella R, et al. Covered stents in patients with complex aortic coarctations. *Am Heart J* 2007; 154: 795-800. [CrossRef]
6. Baykan A, Karagöz T, Çeliker A. Endovascular stent implantation for coarctation of the aorta in children and young adults: intermediate follow-up results from Turkey. *Turk J Pediatr* 2009; 51: 116-9.
7. Slack MC. The role of stenting in coarctation of the aorta. *Prog Pediatr Cardiol* 2001; 14: 45-57. [CrossRef]
8. Golden AB, Hellenbrand WE. Coarctation of the aorta: stenting in children and adults. *Catheter Cardiovasc Interv* 2007; 69: 289-99. [CrossRef]
9. Kouchoukos NT, Blackstone EH, Doty DB, Hanley FL, Karp RB. Coarctation of the aorta and interrupted aortic arch. In: Kirklin/Barrat-Boyes, editors. *Cardiac surgery*, 3rd ed. Philadelphia: Churchill Livingstone; 2003. p. 1315-77.

Address for Correspondence/Yazışma Adresi: Dr. Sertaç Hanedan Onan
Erciyes Üniversitesi Tıp Fakültesi, Pediatrik Kardiyoloji Bilim Dalı,
Kayseri- Türkiye

Phone: +90 352 437 49 37 Fax: +90 352 437 58 25

E-mail: hanedansertac@hotmail.com

Available Online Date/Çevrimiçi Yayın Tarihi: 16.05.2012

©Telif Hakkı 2012 AVES Yayıncılık Ltd. Şti. - Makale metnine www.anakarder.com web sayfasından ulaşılabilir.

© Copyright 2012 by AVES Yayıncılık Ltd. - Available on-line at www.anakarder.com
doi:10.5152/akd.2012.132