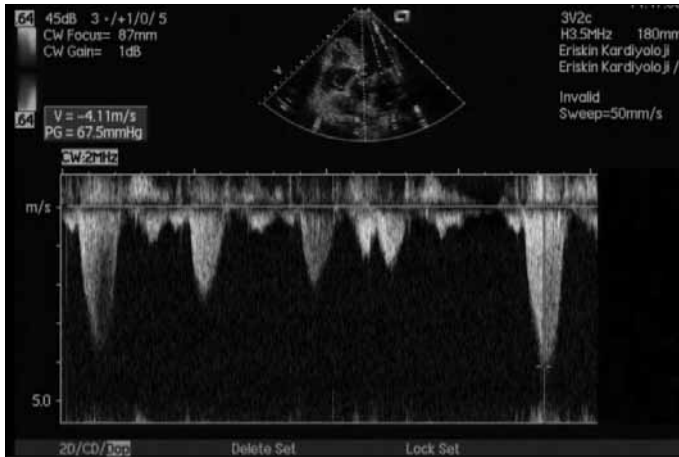

**Figure 2. Pulsed wave Doppler velocity revealing a pressure gradient of 67.5 mmHg at rest in left ventricular outflow tract**

The patient was discharged after the symptoms were relieved and rhythm control was obtained with the therapy of amiodarone plus warfarin. She is still being followed in sinus rhythm without any complaint.

## Discussion

Ebstein's anomaly occurs in approximately 1 per 200.000 live births and accounting for <1% of all congenital heart diseases (5). The main finding of Ebstein's anomaly is the downward displacement of the septal and posterior leaflets of the tricuspid valve in relation to the mitral anterior leaflet more than 8 mm/m<sup>2</sup> (6).

Ebstein's anomaly is a disorder which is not confined to the right heart and left-sided valve abnormalities are also more common than the general population (3). Mitral valve prolapse (3), dysplasia of the mitral valve (3), anomalies of cords and papillary muscles (7) have been described in patients with Ebstein's anomaly. Subaortic stenosis due to the presence of an accessory mitral valve has also been reported in an adult case of Ebstein's anomaly (4).

This is the first case in the literature which reveal LVOT obstruction due to native mitral valve in an adult patient of Ebstein's anomaly who had a surgical closure of atrial septal defect. The patient's condition improved with the medical treatment and normal sinus rhythm was obtained. The signs of heart failure or cyanosis, and any recurrent syncope attack were not observed during the one year control of our case.

If exercise-induced syncope as a symptom and mid-systolic murmur heard over the aortic area as a physical examination finding exist in a patient with Ebstein's anomaly, mitral valve tissue leading to LVOT obstruction should be kept in mind. Two-dimension and color Doppler echocardiogram may clearly demonstrate such finding and for this reason we did not use an additional imaging technique in our case. In patients with Ebstein's anomaly who developed recurrent syncope attacks as a result of LVOT obstruction or heart failure due to severe mitral regurgitation caused by redundancy of the mitral leaflets and chordae, a reconstructive surgery for mitral valve leaflets and chordae may be considered.

## Conclusion

Ebstein's anomaly should not be considered as a disease limited to the right heart. Mitral valve anomalies are seen more frequently than normal population in this disorder. Echocardiography is a useful diagnostic tool in the evaluation of the mitral valve abnormalities related to

Ebstein's anomaly. Mitral valve morphology, systolic anterior motion of the anterior mitral leaflet and mitral valve regurgitation may be seen, and any gradient of LVOT may be measured noninvasively with the use of echocardiography in such patients.

**Video 1.** Two-dimensional and color Doppler echocardiograms showing the mitral anterior leaflet causing left ventricular outflow tract obstruction

## References

- Edwards WD. Embryology and pathologic features of Ebstein's anomaly. *Prog Pediatr Cardiol* 1993; 2: 5-15. [CrossRef]
- Dereani JA, Danielson GK. Ebstein's anomaly of the tricuspid valve. In: Mavroudis C, Backer CL, editors. *Pediatric Cardiac Surgery*. 3rd ed. Philadelphia, Pa: Mosby; 2003. p.524-36.
- Attenhofer Jost CH, Connolly HM, O'Leary PW, Warnes CA, Tajik AJ, Seward JB. Left heart lesions in patients with Ebstein anomaly. *Mayo Clin Proc* 2005; 80: 361-8. [CrossRef]
- Isobe M, Tanaka M, Sekiguchi M. Subaortic stenosis due to accessory tissue of the mitral valve associated with Ebstein's anomaly in an adult. *Int J Cardiol* 1996; 57: 286-8. [CrossRef]
- Attenhofer Jost CH, Connolly HM, Dearani JA, Edwards WD, Danielson GK. Ebstein's anomaly. *Circulation* 2007; 115: 277-85. [CrossRef]
- Attenhofer Jost CH, Connolly HM, Edwards WD, Hayes D, Warnes CA, Danielson GK. Ebstein's anomaly-review of a multifaceted congenital cardiac condition. *Swiss Med Wkly* 2005; 135: 269-81.
- Gerlis LM, Ho SY, Sweeney AE. Mitral valve anomalies associated with Ebstein's malformation of the tricuspid valve. *Am J Cardiovasc Pathol* 1993; 4: 294-301.

**Address for Correspondence/Yazışma Adresi:** Dr. Taner Ulus  
Eskişehir Osmangazi Üniversitesi Tıp Fakültesi, Kardiyoloji Anabilim Dalı,  
Meşelik, Eskişehir-Türkiye  
Phone: +90 222 229 37 00 Fax: +90 222 229 90 11 E-mail: tanerulus@hotmail.com  
**Available Online Date/Çevrimiçi Yayın Tarihi:** 04.10.2011

©Telif Hakkı 2011 AVES Yayıncılık Ltd. Şti. - Makale metnine [www.anakarder.com](http://www.anakarder.com) web sayfasından ulaşılabilir.

©Copyright 2011 by AVES Yayıncılık Ltd. - Available on-line at [www.anakarder.com](http://www.anakarder.com)  
doi:10.5152/akd.2011.173

## Dental volumetric tomography in the radiological detection of carotid artery calcification

*Karotid arter kalsifikasyonunun radyolojik belirlenmesinde dental volümetrik tomografi*

**Binali Çakur, Muhammed Akif Sümbüllü, Ahmet Berhan Yılmaz**  
Department of Oral Diagnosis and Radiology, Faculty of Dentistry,  
Atatürk University, Erzurum-Turkey

## Introduction

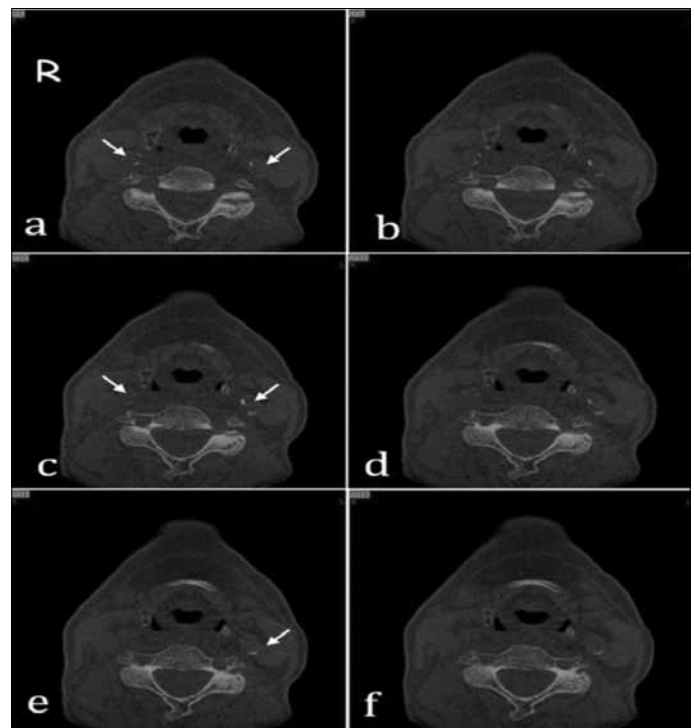
Atherosclerosis, a progressive inflammatory disorder, may lead to coronary heart disease (e.g., angina, myocardial infarction, and sudden death), cerebrovascular disease (e.g., stroke and transient ischemic attack) or peripheral vascular disease (e.g., claudication and critical limb ischemia). Atherosclerosis and its outcomes represent important

health problems both in developed countries and in developing countries (1). Atherosclerosis is caused by an abnormal accumulation of lipids on the walls of the arteries. The carotid bifurcation region is at the highest risk of atherosclerosis because of turbulent flow, flow velocity and shear stress (1, 2). Carotid artery calcification (CAC) can result in important vascular obstruction causing stroke. On the other hand, carotid atherosclerotic disease is one of the major preventable causes of ischemic strokes (3). For this reason, especially in asymptomatic patients with carotid atherosclerosis, early detection of this disease reduces the morbidity and mortality (4). It is suggested that the prevalence of CAC vary from 2 to 5% (1, 2). The presence of CAC can be detected by either non-invasive techniques, such as Doppler ultrasound, magnetic resonance angiography, and computed tomography angiography or invasive techniques, such as digital subtraction angiography (3). However, in dentistry, carotid artery calcifications (CACs) can be detected by the panoramic radiography and dental volumetric tomography (4-6). Dental volumetric tomography (DVT) is relatively a new three-dimensional imaging technique that uses a cone beam that moves around the part of the body under examination and uses generally in dental implantology.

The present case report focuses on the radiological diagnosis of incidental carotid artery calcification by using dental volumetric tomography in an adult person.

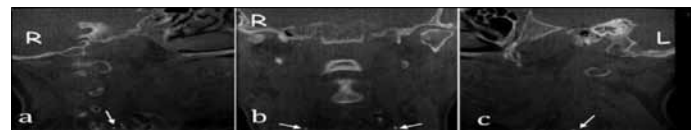
### Case Report

A 67-year-old female was referred to our clinic due to dental problems, tooth loss and prosthetic requirements. She had hypertension, chronic obstructive pulmonary disease. The DVT scanning (NewTom FP, Quantitative Radiology, Verona, Italy) was performed so as to evaluate the patient's dental status and potential dental implant place. The DVT was done on the patient positioned supinely. Positioning of the head of the patient was performed by the use of two light-beam markers. The vertical positioning light was aligned with the mid-sagittal line of the patients, which helps keep the head centered with respect to the rotational axis. The lateral positioning light was centered at the level of the maxilla, indicating the optimized centre of the reconstruction area. In addition, the head position was adjusted in such a way that the hard palate was parallel to the floor, while sagittal plane was perpendicular to the floor. The DVT scans with 0.5 mm axial slices, 1 mm coronal slices, 1 mm sagittal slices and three-dimensional (3D) images were obtained. Imaging parameters were kV= 110, mA= 10, and FOV=140 mm and the output was automatically adjusted during the 360° rotation according to tissue density (automatic exposure control system). In the course of dental implant planning on DVT, we incidentally detected calcified plaques in the bifurcation region of the right and left carotid arteries (Fig. 1-3) and then DVT images was reviewed with respect to more definitively location and definition of the calcified plaques. Although the CACs was seen as multiple "rice grains" (Figs. 1a-1c; right), and linear (Figs. 1a-1f; left) homogeneous opacifications on the axial images, the axial 3D reconstructed image demonstrated the CACs as curvilinear (Fig. 3b - left) homogeneous opacifications. Coronal images demonstrated the CACs lateral to the cervical vertebrae and as linear globular calcifications (Fig. 2b and 3a). In addition, the coronal 3D reconstructed image demonstrated the CACs lateral to the hyoid bone (Fig. 3b). The sagittal images demonstrated the CACs anterior to the cervical vertebrae and at the level of the greater cornu of the hyoid bone (Fig. 2a, 2c). The patient was referred to physicians for medical evaluation and treatment.



**Figure 1.** On sequential axial slices (a-f), bilateral calcified carotid atheroma (white arrows) is demonstrated. Axial slices demonstrated the CACs as multiple "rice grains" (a-c, right) and linear (a-f, left) homogeneous opacifications

CAC - carotid artery calcification

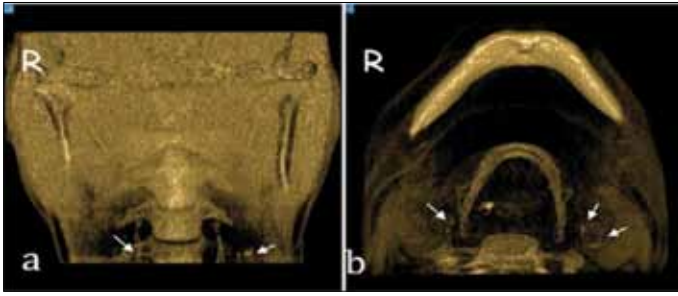


**Figure 2.** The sagittal images of the CACs anterior to the cervical vertebrae and at the level of the greater cornu of the hyoid bone (white arrow) (a, c). Coronal images of the CACs lateral to the cervical vertebrae and as linear globular (white arrows) (b)

CAC - carotid artery calcification

### Discussion

In detecting and preventing of carotid atherosclerotic disease, imaging plays a major role (3). In panoramic radiography, the CACs may be seen as either a radiopaque vertical line or nodular radiopaque mass inferior to the angle of mandible and adjacent to the cervical vertebrae at the level of the C3-C4 intervertebral junction. However, dental panoramic radiography is not as useful as Doppler ultrasonography and three dimensional computed tomography for detecting carotid atherosclerotic disease, because panoramic radiography is essentially a 2D representation of 3D anatomy (1). Over the past decade, dental volumetric tomography has been designed for imaging hard tissue of the maxillofacial region and uses commonly in dental implantology. DVT can produce images with high diagnostic quality, high resolution (sub-millimeter resolution), short scanning time and radiation dose an order of magnitude lower than those of conventional CT scans (5). High-contrast objects such as the anatomical structures and the pathological radiopacities in the carotid vasculature area such as CACs may be assessed by DVT (5, 6). DVT provides 3D localization of various soft tissue calcifications in the head and neck region. Sagittal, coronal and



**Figure 3.** The axial 3D reconstructed image of the CACs as curvilinear homogeneous opacifications (white arrows) (a). However, on the coronal 3D reconstructed image the CACs are seen as linear globular calcifications and lateral to the cervical vertebrae (white arrows) (b)

CAC - carotid artery calcification

axial CBCT images also eliminate the superimposition of anatomic structures (5, 6). On the DVT, the salient features of the CACs depend on orthogonal section. On axial projections, most CAC are seen as single or multiple "rice grains", linear or curvilinear homogeneous opacifications. In coronal sections, CACs are lateral to the anterior tubercle of the cervical vertebrae and seen as linear globular or globular calcifications. On sagittal sections, CACs are medial and inferior to the angle of the mandible, lateral and mostly anterior to the cervical tubercle with vertical position varying from C3 to C5 (6). Normally, bifurcation level of the right carotid artery is more often located between C3 and C4, whereas that of the left carotid artery is located between C4 and C5 (7). In our case, the plaques were at the intervertebral space (at the right side; between C3 and C4 and at the left side; between C4 and C5) and lateral to the cervical vertebrae. Although the CACs were seen as multiple "rice grains", and linear homogeneous opacifications on the axial images, the axial 3D reconstructed image demonstrated the CACs as curvilinear homogeneous opacifications. However, coronal images demonstrated the CACs as linear globular calcifications and lateral to the cervical vertebrae. In our case, curvilinear homogeneous opacifications were not initially observed on the axial images, but on the axial 3D reconstructed image they were observed. It is reported that CACs were unilateral and located on the left side rather than the right side in normal populations (8). Şişman et al. (1) retrospectively investigated the prevalence on 750 PRs in a Turkish population. In their sample, the CAC prevalence was 5.06%. They reported that the most of the CACs were unilateral, but generally located on the right side. Also, they found that the CACs were not significantly different between the males and females. But Bayram et al. (9) and Tamura et al. (8) revealed that the incidence of the CAC was higher in female patients. Also, Bayram et al. (9) reported that the CAC prevalence was 2.1%. It is reported that the combination of risk factors such as hyperlipidemia, hypertension, renal disease, diabetes mellitus, obstructive sleep apnea syndrome, periodontitis, ethnicity, dietary factors, lifestyle and regional differences contribute to CACs (8).

## Conclusion

In dentistry, dentists usually focus on only the teeth and jaws and do not investigate the entire maxillofacial region and the area of the neck during radiographic examination. Thus, we strongly advise that radiological examination should be carefully performed in the whole maxillofacial region and the area of the neck in the patients with or without systemic disease for the evidence of the pathological condition such as carotid artery calcification. For this aim, dental volumetric tomography is a useful imaging modality, especially with the 3D images.

## References

1. Şişman Y, Ertaş ET, Gökçe C, Menku A, Ülker M, Akgünlü F. The prevalence of carotid artery calcification on the panoramic radiographs in Cappadocia region population. *Eur J Dent* 2007; 1: 132-8.
2. Yoon SJ, Yoon W, Kim OS, Lee JS, Kang BC. Diagnostic accuracy of panoramic radiography in the detection of calcified carotid artery. *Dentomaxillofac Radiol* 2008; 37: 104-8. [CrossRef]
3. U-King-Im JM, Young V, Gillard JH. Carotid-artery imaging in the diagnosis and management of patients at risk of stroke. *Lancet Neurol* 2009; 8: 569-80. [CrossRef]
4. Ertaş ET, Mavili E, Şişman Y, Sahman H, Etoz M, Şekerçi AE. Incidental findings of carotid artery stenosis detected by calcifications on panoramic radiographs: report of three cases. *Oral Radiol* 2010; 26: 116-21.
5. Khan Z, Wells A, Scarfe W, Farman A. Cone Beam CT isolation of calcifications in the maxillofacial and cervical soft tissues: a retrospective analysis. *Int J Computer Assist Radiol Surg* 2008; 3: 221-2.
6. Scarfe WC, Farman AG. Soft tissue calcifications in the neck: maxillofacial CBCT presentation and significance. *AADMRT Currents* 2010; 2: 1-15. [CrossRef]
7. Mehdizadeh M, Naghavi E. Evaluation of calcified carotid artery atheromas detected by panoramic radiograph above 50-years-old in Isfahan. *Pakistan Oral & Dental Journal* 2008; 28: 249-52.
8. Tamura T, Inui M, Nakase M, Nakamura S, Okumura K, Tagawa T. Clinicostatistical study of carotid calcification on panoramic radiographs. *Oral Dis* 2005; 11: 314-7. [CrossRef]
9. Bayram B, Uçkan S, Açıkgöz A, Müderrisoğlu H, Aydınalp A. Digital panoramic radiography: a reliable method to diagnose carotid artery atheromas? *Dentomaxillofac Radiol* 2006; 35: 266-70. [CrossRef]

**Address for Correspondence/Yazışma Adresi:** Dr. Binalı Çakur  
Atatürk Üniversitesi, Diş Hekimliği Fakültesi, Oral Diagnoz ve Radyoloji Anabilim Dalı, Erzurum-Türkiye  
Phone: +90 442 231 27 73 Fax: +90 442 236 09 45  
E-mail: bcakur@atauni.edu.tr

**Available Online Date/Çevrimiçi Yayın Tarihi:** 04.10.2011

©Telif Hakkı 2011 AVES Yayıncılık Ltd. Şti. - Makale metnine [www.anakarder.com](http://www.anakarder.com) web sayfasından ulaşılabilir.

©Copyright 2011 by AVES Yayıncılık Ltd. - Available on-line at [www.anakarder.com](http://www.anakarder.com)  
doi:10.5152/akd.2011.174