






# Temporary left ventricular assist device for complete recovery from reversible acute heart failure due to tumor necrosis factor- $\alpha$ inhibitor

 Marie-Camille Soucy-Giguere\*,  Éric Charbonneau\*\*,  Alexandre Cinq Mars\*,  Michelle Dubois\*\*\*,  Mario Sénéchal\*  
Departments of \*Cardiology, and \*\*Cardiovascular Surgery,  
\*\*\*Research Center, Quebec Heart and Lung Institute, Laval  
University; Quebec-Canada

## Introduction

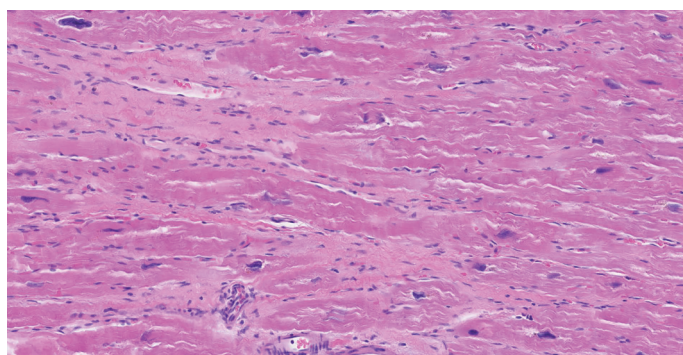
We present the case of a 38-year-old woman with symptoms of acute heart failure (HF). In the previous months, she received tumor necrosis factor (TNF)- $\alpha$  inhibitors for the treatment of arthritis secondary to Crohn's disease. She initially received etanercept (Enbrel) for nearly 1 year and subsequently received infliximab (Remicade) for 6 months. Echocardiograms following the etanercept therapy were normal. Since her disease did not respond well to etanercept, she received 16 treatments of infliximab, at the end of which HF symptoms developed, with rapid clinical deterioration. Her echocardiogram demonstrated dilated cardiomyopathy with severe biventricular dysfunction and left ventricular ejection fraction (LVEF) and right ventricular ejection fraction (RVEF) <20% with severe functional mitral and tricuspid regurgitation. Her extensive diagnostic work-up, including pathological examination of endomyocardial biopsy, was normal. Despite optimal treatment of HF, her status did not improve, and a left ventricular assist device (LVAD, HeartMate II) was implanted. The evolution was unremarkable, and she rapidly recovered in the following months, with LVEF reaching  $\geq 45\%$ . Based on the patient's clinical improvement and LVEF recuperation, LVAD was removed. Her functional status and LVEF remained stable after LVAD explantation. Therefore, the very probable etiology of the precipitated HF was infliximab toxicity.

## Case Report

We describe the case of a 38-year-old woman with symptoms of acute HF following anti-TNF- $\alpha$  therapy for Crohn's disease-related arthritis. She first received etanercept for nearly 1 year and subsequently received infliximab for 6 months starting July 2012. Her echocardiogram before etanercept therapy and in between the two treatments showed a normal LVEF. She had already received 16 treatments of infliximab when she started feeling shortness of breath, dizziness, and fatigue. On presentation, there was

no evidence of active or recent respiratory tract infection, and the patient had no symptoms compatible with viral gastroenteritis. The patient's clinical status deteriorated rapidly, and she was transferred in our institution and hospitalized in January 2013 for progressive HF and volume overload. She had a New York Heart Association (NYHA) functional classification of III–IV/IV. Transthoracic echocardiography revealed severe dilated cardiomyopathy with an LVEF <20%, left ventricular end diastolic diameter (LVEDD) of 66 mm, left ventricular end systolic diameter (LVESD) of 57 mm, and severe functional mitral and tricuspid regurgitation. Elevated creatinine (140 mmol/L), bilirubin (30  $\mu$ mol/L), alanine aminotransferase (74 units/L), and aspartate aminotransferase (50 units/L) levels suggested renal failure and hepatic congestion. She was treated with intravenous (i.v.) diuretics for volume overload and milrinone for low cardiac output symptoms. Infliximab therapy was discontinued at the time of HF diagnosis in our institution.

Her coronary angiogram was normal, and heart biopsy was negative for myocarditis. Figure 1 shows the right ventricle apex biopsy with mild cardiomyocyte hypertrophy and focal interstitial fibrosis. Her cardiac magnetic resonance imaging (MRI) demonstrated a dilated cardiomyopathy with severe left and right HF (LVEF=15% and RVEF=25%). Cardiac MRI also showed mild late gadolinium enhancement and viability in all myocardial segments. Her Swan-Ganz examination showed the following measurements: pulmonary artery pressure 37/25 mm Hg, mean pulmonary artery pressure 32 mm Hg, wedge pressure 26 mm Hg, cardiac index 2.5 L/m<sup>2</sup>, and pulmonary vascular resistance 1.2 UW. HF therapy included furosemide (1 g/24 h i.v.) and milrinone (0.375  $\mu$ g/kg/min), but the introduction of angiotensin-converting-enzyme inhibitor and  $\beta$ -blockers was not possible considering the low cardiac output of the patient. A second echocardiogram performed a few days after the initiation of milrinone treatment showed similar results. New onset non-sustained ventricular tachycardia on day 10 and low blood pressure (70/45 mm Hg) a few days later limited the use of milrinone. Based on patient characteristics (INTERMACS profile II) and institutional resources, LVAD (HeartMate II) was selected to achieve short-term hemodynamic stability and potential bridge to recovery. Surgery was unremarkable with favorable evolution. On



**Figure 1.** Microscopic examination of right ventricle apex biopsy showing mild cardiomyocyte hypertrophy and focal interstitial fibrosis

discharge, the patient received the usual HF treatment including ramipril (2.5 mg d.i.e.), metoprolol (12.5 mg b.i.d.), and furosemide (40 mg b.i.d.) and was followed up on an outpatient basis with a monthly clinical evaluation.

At follow-up, treadmill ramp tests and routine echocardiography were performed. The ramp test consisted of decreasing the pump function from 9400 rpm to 6400 rpm while assessing the LVEF, left ventricular dimension, and clinical status at rest and during a Bruce protocol treadmill stress test. Progressive clinical and echocardiographic improvements were noted with LVEF reaching 45% with LVEDD and LVESD of 50 mm and 34 mm, respectively, 3 months after the implantation. While downgrading to 6400 rpm, her clinical status remained unchanged, and echocardiographic finding demonstrated an LVEF of 45%. The explantation of the device was finally performed, and the procedure was uneventful. During explantation, a Hemashield graft was positioned at the apex, and final closure was performed with multiple 4-0 polypropylene stitches. The patient was released from the hospital 1 week after explantation with HF medication including metoprolol (25 mg b.i.d.), furosemide (40 mg d.i.e.), ramipril (5 mg b.i.d.), and aldactone (25 mg d.i.e.). At 6 months, her clinical status remained unchanged (NYHA I/IV), and echocardiography demonstrated an LVEF of 45% with LVEDD and LVESD of 45 mm and 37 mm, respectively.

## Discussion

TNF- $\alpha$  antagonists have demonstrated benefits in the treatment of patients with rheumatoid arthritis, Crohn's disease, and other inflammatory condition (1). Infliximab, a frequently used TNF- $\alpha$  inhibitor, is a chimeric monoclonal antibody against TNF- $\alpha$  and is used, when in combination with methotrexate, to treat rheumatoid arthritis (2). TNF- $\alpha$  has a negative inotropic impact on myocytes and may eventually cause clinical HF (3). "Reverse signaling" is also another mechanism that may explain the negative impact of TNF- $\alpha$  inhibition on cardiac function (4). Recent data from clinical trials suggest that TNF- $\alpha$  antagonists might induce HF in a subset of patients (2). In one case series of 10,050 patients treated with adalimumab (Humira), 0.3% of patients developed new HF, and 7% of patients with pre-existing HF experienced exacerbation of their disease (5). The Food and Drug Administration acknowledged 158 reports of patients with congestive HF (CHF) associated with the use of TNF- $\alpha$  inhibitors. A more extensive analysis of 51 of 158 patients was performed. The two cohorts were composed of 30 patients treated with etanercept and 21 patients treated with infliximab, respectively. There were 42 cases of new onset CHF and nine cases of exacerbation of pre-existing CHF. Among the new cases, half had no prior risk factors for CHF. The median time to onset was 3.5 months, and the mean age of the patients was 64 years. Three deaths occurred, and 51 patients who developed CHF (four etanercept and six infliximab) were <50 years. Only three had known risk factors for CHF. All patients in the two cohorts terminated their anti-TNF medication, with three resolved, six partially improved,

and one patient died (6). In another cohort, among patients with rheumatoid arthritis, the cumulative incidence of definite or possible HF among those treated with TNF- $\alpha$  antagonists was 4.4 cases per 1000 individuals in comparison with 1.0 case per 1000 individuals in the group of patients who did not receive similar medication. Of interest in these series, 50% of patients had no classical risk factors for HF (2).

The relationship between TNF- $\alpha$  inhibition and HF occurrence remains unclear. One hypothesis is that TNF- $\alpha$  and other cytokines may have a positive impact on cardiac function and homeostasis. In the same line, TNF- $\alpha$  may induce nitric oxide production and decrease peripheral vascular resistance. Furthermore, a large network of cytokines is involved in HF, and TNF- $\alpha$  blockade alone may not be sufficient to show any benefits (7). Clearly, further research regarding anti-cytokine therapies is necessary, but in the meantime, clinicians should be aware that new onset HF or exacerbation of pre-existing HF may develop in patients on TNF- $\alpha$  antagonist therapy (4, 6).

## Conclusion

TNF- $\alpha$  inhibitors are being used more often nowadays for the treatment of various rheumatologic diseases. New onset HF or deterioration of a pre-existing heart condition is a possible complication of these treatments. Regular clinical evaluations of HF symptoms should be routinely assessed, and those presenting with symptoms should be further investigated by echocardiograms. The case presented here is an example of the potential toxicity of TNF- $\alpha$  inhibitors on heart function. We highlight the usefulness of the LVAD in achieving significant clinical improvement as a bridge to complete heart function recovery.

**Informed consent:** The patient consented to the publication of her case report.

## References

1. Bernatsky S, Hudson M, Suisse S. Anti-rheumatic drug use and risk of hospitalization for congestive heart failure in rheumatoid arthritis. *Rheumatology (Oxford)* 2005; 44: 677-80. [\[CrossRef\]](#)
2. Kwon HJ, Coté TR, Cuffe MS, Kramer JM, Braun MM. Case reports of heart failure after therapy with a tumor necrosis factor antagonist. *Ann Intern Med* 2003; 138: 807-11. [\[CrossRef\]](#)
3. Cole J, Busti A, Kazi S. The incidence of new onset congestive heart failure and heart failure exacerbation in Veteran's Affairs patients receiving tumor necrosis factor alpha antagonists. *Rheumatol Int* 2007; 27: 369-73. [\[CrossRef\]](#)
4. Juhász K, Buzás K, Duda E. Importance of reverse signaling of the TNF superfamily in immune regulation. *Expert Rev Clin Immunol* 2013; 9: 335-48. [\[CrossRef\]](#)
5. Schiff MH, Burmester GR, Kent JD, Pangan AL, Kupper H, Fitzpatrick SB, et al. Safety analyses of adalimumab (HUMIRA) in global clinical trials and US postmarketing surveillance of patients with rheumatoid arthritis. *Ann Rheum Dis* 2006; 65: 889-94. [\[CrossRef\]](#)



6. Cush JJ. Unusual toxicities with TNF inhibition: heart failure and drug-induced lupus. *Clin Exp Rheumatol* 2004; 22 (5 Suppl 35): S141-7.
7. Moe KT, Khairunnisa K, Yin NO, Chin-Dusting J, Wong P, Wong MC. Tumor necrosis factor- $\alpha$ -induced nuclear factor-kappaB activation in human cardiomyocytes is mediated by NADPH oxidase. *J Physiol Biochem* 2014; 70: 769-79. [CrossRef]

**Address for Correspondence:** Mario Sénéchal, MD,

Department of Cardiology,  
Quebec Heart and Lung Institute,

Laval University, 2725,  
Chemin Sainte-foy G1V4G5 Quebec City,  
Québec-Canada

Phone: 418-656-8711

E-mail: mario.senechal@criucpq.ulaval.ca

©Copyright 2019 by Turkish Society of Cardiology - Available online  
at [www.anatoljcardiol.com](http://www.anatoljcardiol.com)

DOI:10.14744/AnatolJCardiol.2019.67124



## A rare complication of posterior myocardial infarction: Anterolateral papillary muscle rupture

**Ahmet Karaduman, İsmail Balaban, Berhan Keskin, Çetin Geçmen, Gökhan Kahveci**  
Department of Cardiology, Kartal Koşuyolu Heart Training and Research Hospital; İstanbul-Turkey

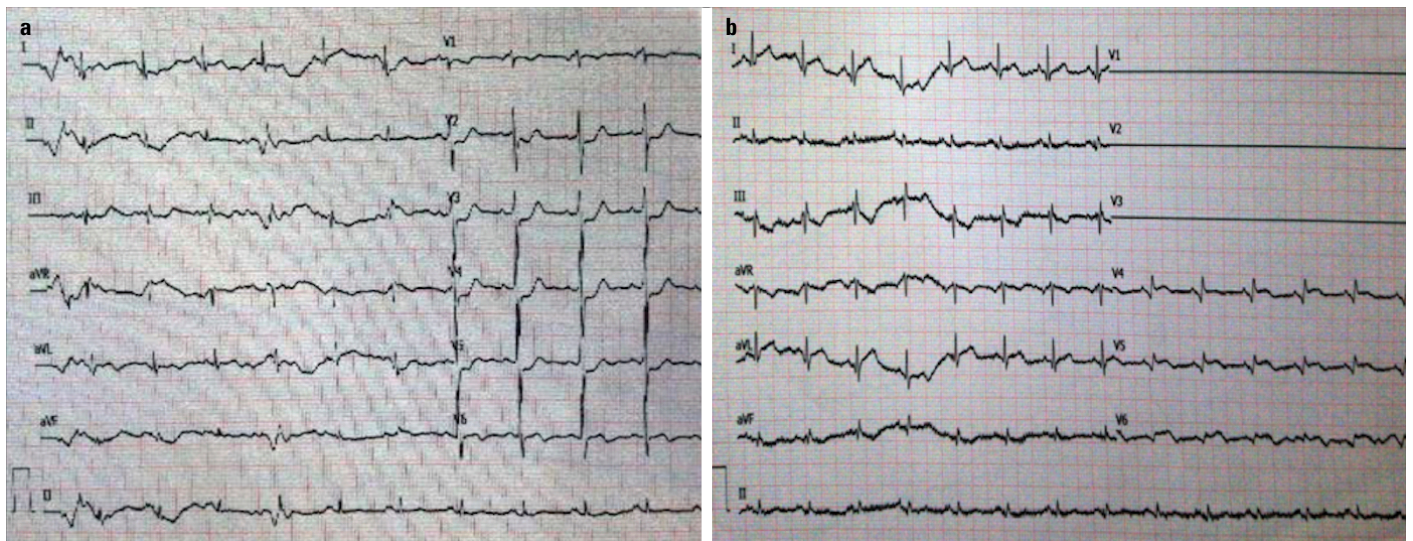
### Introduction

Papillary muscle rupture is one of the fatal complications of acute myocardial infarction. The incidence of anterolateral papillary muscle (APM) rupture is 6-12 times lower than that of

posteromedial papillary muscle (PPM) rupture. This is because APM has a dual blood supply from left anterior descending artery (LAD) and left circumflex artery (LCX), whereas the blood supply of PPM is maintained only by the posterior descending artery (1). In case of the presence of a lesion in both LCX and LAD, APM rupture can be seen. We present a case with an example of this pathophysiologic mechanism, which will provide insights into the features of patients with the Acute coronary syndrome (ACS) and APM rupture.

### Case Report

A 68-year-old male with no medical history of known coronary artery disease presented to the emergency department with acute chest pain. His blood pressure was 130/70 mm Hg and heart rate 92 bpm. Auscultation of the patient revealed loud S1 and S2, S4 gallop rhythm and no murmur. A 12-lead electrocardiogram showed ST depression on the anterior leads and ST elevation on the posterior leads (Fig. 1). The patient was admitted to the catheter laboratory with the diagnosis of posterior myocardial infarction (MI). Coronary angiogram showed a non-dominant LCX with first obtuse marginal branch (OM1) with complete occlusion of proximal end, a diffuse plaque in LCX after OM1, and LAD with 90% stenosis in the mid portion. Primary percutaneous coronary intervention (PCI) to OM1 and elective PCI to LAD was selected as the best treatment option (Fig. 2a-2c). The 3.0×15-mm drug-eluting stent was implanted into OM1 (Fig. 2d). The patient was admitted to the coronary intensive care unit and was hemodynamically stable. After 12 h, hypotension and tachycardia suddenly developed. Trans-thoracic echocardiogram (TTE) showed severe mitral regurgitation (MR). Furthermore, transesophageal echocardiogram (TEE) showed a normal thickness of the mitral valve and a flail



**Figure 1.** (a) 12-lead electrocardiogram shows ST-segment depression in anterior leads. (b) Posterior electrocardiogram shows ST-segment elevation in posterior leads