

life-threatening bradycardia, hypotension, and altered mental status (3). Complete heart blocks may occur in some patients. However, there was no report regarding long lasting atrioventricular (AV) block and permanent pacemaker implantation.

A 55-year-old female without any cardiovascular disease history and drug use was admitted to our emergency department with complete AV block and symptoms of nausea, dizziness and syncope. She has been taking average 50 mL/day of honey because of gastric pain for a week and she took last dose 2 h ago. Her heart rate was 39 bpm and blood pressure was 70/40 mmHg. Electrocardiogram (ECG) revealed complete AV block (Fig. 1A). Since the AV block and symptoms of the patient did not resolve with intravenous administration of 3 mg atropine sulfate, a temporary transjugular pacemaker was implanted. In addition, intravenous sodium chloride (100 mL/h) was infused. Her symptoms and hemodynamic status resolved over the next 6 h. However, no resolution occurred on ECG. Her transthoracic echocardiography showed no abnormal findings. She was hospitalized for a week, however complete AV block did not resolve over time. Because of the persistent AV block, coronary angiography performed in order to rule out CAD and revealed normal coronary arteries. Therefore, permanent pacemaker was implanted to the patient (Fig. 1B) and she was discharged uneventfully from the hospital.

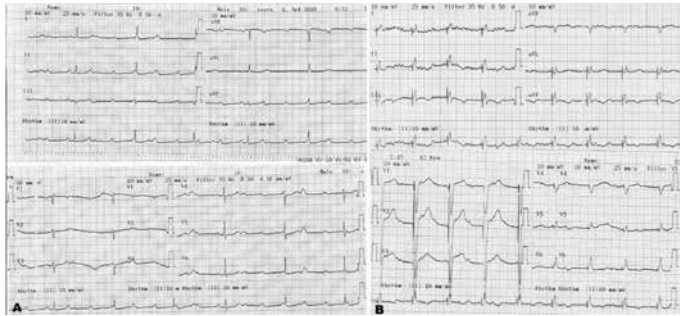


Figure 1. Electrocardiogram of the patient on admission reveals complete atrioventricular block with a ventricular rate of 39 beats/minute (A) Electrocardiogram after permanent pacemaker implantation shows pacemaker rhythm (B)

Uğur Canpolat, Asena Gökçay Canpolat*, Kudret Aytemir
From Departments of Cardiology and *Internal Medicine, Faculty of Medicine, Hacettepe University, Ankara-Turkey

References

1. Gündüz A, Türedi S, Uzun H, Topbaş M. Mad honey poisoning. Am J Emerg Med 2006; 24: 595-8. [CrossRef]
2. Maejima H, Kinoshita E, Seyama I, Yamaoka K. Distinct sites regulating grayanotoxin binding and unbinding to D4S6 of Na(v)1.4 sodium channel as revealed by improved estimation of toxin sensitivity. J Biol Chem 2003; 278: 9464-71. [CrossRef]
3. Ergün K, Tüfekcioğlu O, Aras D, Korkmaz S, Pehlivan S. A rare cause of atrioventricular block: Mad Honey intoxication. Int J Cardiol 2005; 99: 347-8. [CrossRef]

Address for Correspondence/Yazışma Adresi: Dr. Uğur Canpolat
Hacettepe Üniversitesi Tıp Fakültesi, Kardiyoloji Anabilim Dalı, 06100 Sıhhiye, Ankara-Türkiye
Phone: +90 312 305 17 80 Fax: +90 312 305 41 37
E-mail: dru_canpolat@yahoo.com

Available Online Date/Çevrimiçi Yayın Tarihi: 18.09.2012

©Telif Hakkı 2012 AVES Yayıncılık Ltd. Şti. - Makale metnine www.anakarder.com web sayfasından ulaşılabilir.

©Copyright 2012 by AVES Yayıncılık Ltd. - Available on-line at www.anakarder.com
doi:10.5152/akd.2012.228

Giant J-wave (Osborn wave) related to hypothermia and hypokalemia

Hipokalemi ve hipotermi ile ilişkili dev J dalgası (Osborn dalgası)

A 21-year-old man was admitted to our hospital's emergency service with confusion. He had used cephalosporin treatment for urinary tract infection and upper respiratory system infection for 5 days. On physical examination; stiff neck, papillary edema, confusion, disorientation were detected. Heart rate was 45 beats/min. Blood pressure was 110/84 mmHg, O₂ saturation was 83% and body temperature was 30.1°C. There was no external factor to reduce patient's body temperature. Additionally hypokalemia (2.7 mmol/L), hyperchloremia (114 mmol/L), respiratory acidosis (pH:7.22), CO₂ retention (pCO₂: 58.1 mmHg) were detected. On electrocardiogram (ECG) prolonged QT segment (680 msec.) and complexes extra deflection (Osborn waves) at the end of the QRS were seen (Fig. 1). The patient was transported to intensive care unit with pneumonia and encephalitis related sepsis that induced hypothermia. After warming up, combined antibiotherapy (meropenem 500 mg flk 2x1 i.v., vancomycin 500 mg flk 2x1 i.v., acyclovir 400 mg tb 2x1, oseltamivir fosfat 75 mg tb 2x1) and ventilation support the hypothermic humps "Osborn waves" disappeared (Fig. 2). The physiologic effect of hypothermia on ECG is known as Osborn wave that

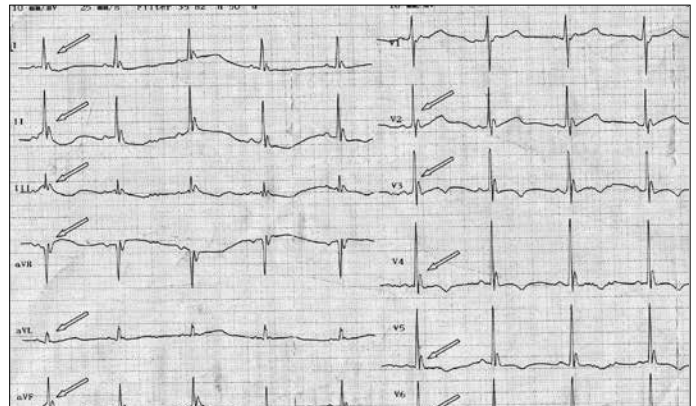


Figure 1. Electrocardiogram on admission: sinus rhythm, Osborn waves can be seen in almost all derivations

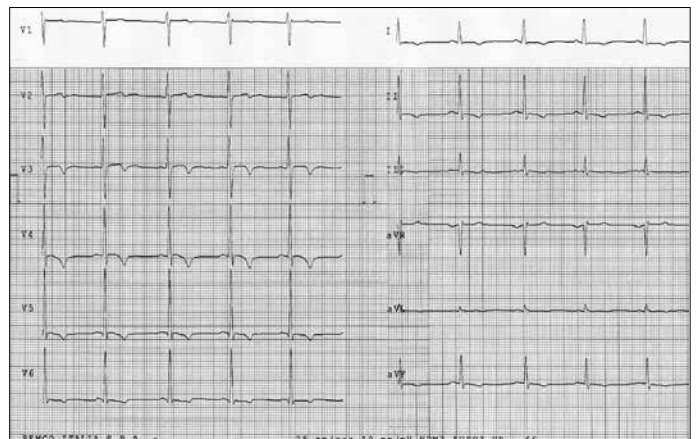


Figure 2. Electrocardiogram after treatment: sinus rhythm, Osborn waves disappeared, T-wave negativities can be seen almost in all derivations

was firstly described by Joseph Osborn in 1953 (1). These waves are a deflection with hump configuration occurring at the J point on the ECG. Mostly seen in hypothermia but they may be associated with sepsis, hypokalaemia, hypercalcemia, hypoglycemia, diabetic ketoacidosis, neuroleptic drug abuse, Brugada syndrome, damage to brain and ischemic heart disease (2-4). Recent findings suggest that hypothermia has conduction delay effects but the Osborn waves are directly associated with high CO₂ and low pH levels under hypothermic conditions. Some animal studies demonstrates that, although hypothermia is corrected, Osborn waves still maintain because of low pH levels (5).

Murat Yalçın, Zafer Işılak, Ömer Uz, Mehmet Doğan
Department of Cardiology, Gülhane Military Medical Academy,
Haydarpaşa Hospital, İstanbul-Turkey

References

1. Osborn JJ. Experimental hypothermia; respiratory and blood pH changes in relation to cardiac function. Am J Physiol 1953; 175: 389-98.
2. Morales GX, Bodiwala K, Elayi CS. Giant J-wave (Osborn wave) unrelated to hypothermia. Europace 2011; 13: 283. [CrossRef]
3. Şentürk T, Özbek C, Tolga D, Kazazoğlu AR. J deflections on ECG in severe hypothermia and hypokalaemia: a case report. Neth Heart J 2011 May 17.
4. Hoşcan Y, Özgül M. Report of a case with huge Osborn waves. Anadolu Kardiyol Derg 2006; 6: 411-2.
5. Edelman ER, Joynt K. J waves of Osborn revisited. J Am Coll Cardiol 2010;18; 55: 2287.

Address for Correspondence/Yazışma Adresi: Dr. Murat Yalçın
GATA, Haydarpaşa Hastanesi, Kardiyoloji Bölümü, Tıbbiye Caddesi 34668
Üsküdar, İstanbul-Türkiye
Phone: +90 216 542 34 80 Fax: +90 216 348 78 80
E-mail: med_murat@yahoo.com

Available Online Date/Çevrimiçi Yayın Tarihi: 18.09.2012

©Telif Hakkı 2012 AVES Yayıncılık Ltd. Şti. - Makale metnine www.anakarder.com web sayfasından ulaşılabilir.

©Copyright 2012 by AVES Yayıncılık Ltd. - Available on-line at www.anakarder.com
doi:10.5152/akd.2012.229

Increased level of cardiac troponin-I due to rheumatoid factor positivity in a healthy patient with normal coronary arteries

Normal koroner damarlara sahip sağlıklı bir hastada serum romatoid faktör pozitifliğine bağlı artmış kardiyak troponin değerleri

Dear Editor,

Detection of rise and/or fall of cardiac biomarkers (preferably troponin) with at least one value above the 99th percentile of the upper reference limit together with evidence of myocardial ischemia are required for the diagnosis of myocardial infarction (1).

A 56-year-old man was admitted to emergency department with dyspepsia and epigastric pain. Physical examination was normal except a mild tenderness in the epigastrium. He did not have an allergy.

Electrocardiography was normal. Laboratory test were normal except increased troponin-I which was 0.5ng/mL (reference level, <0.01 ng/mL; the diagnostic cut-off for major myocardial injury is 0.4 ng/mL) with normal creatine kinase and creatine kinase-MB fraction and showed no serial increase in subsequent blood tests. Echocardiography showed normal cardiac functions. Coronary angiography demonstrated normal coronary arteries (Fig. 1). The serologic tests for viral etiology were negative for hepatitis B and C virus, human immunodeficiency virus, Cocksackie virus-B, adenovirus and parvovirus B19, Cytomegalovirus and Epstein-Barr virus. His rheumatoid factor status was positive. At one month follow-up visit cardiac troponin-I level was 0.6ng/mL and so interference studies were carried out which showed antibody interference in the troponin assay.

The presence of heterophilic antibodies in high titers may lead to analytical errors in two-site immunoassays (2). Our patient had no recent history of animal exposure, vaccination and antiserum therapy. Rheumatoid factor is a heterogeneous group of auto antibodies that are directed against immunoglobulin-G and presented in the sera of many patients with rheumatoid arthritis, other immune diseases and healthy individuals. It has been reported that 5% of healthy patients might have circulating rheumatoid factor, and approximately 1% of patients with elevated cardiac troponin-I levels may have this elevation solely because of the rheumatoid factor (3). Our patient had rheumatoid factor positivity but we did not have specific agent to remove in our laboratory. So we performed polyethylene glycol which is used to precipitate large immune complexes in the serum as a simple, inexpensive and easy method (4). Treating with polyethylene glycol made the test negative. Although highly specific and sensitive to acute myocardial injury, pulmonary embolism, congestive heart failure, cardiac trauma, cardiopulmonary resuscitation, electrical cardioversion, sepsis, end stage renal disease, arrhythmias, epileptic seizures, stroke and cardiac interventions may also increase cardiac troponins. High sensitive cardiac troponins are novel markers of cardiac injury having high sensitivity and specificity besides providing accurate early diagnosis, risk stratification and screening in compared to standard troponin assays (5). In this patient we exclude all cardiac and non-cardiac reasons of true positivity of troponin levels. Only logical explanation remaining was false positivity of cardiac troponin-I level so we have performed polyethylene glycol for definitive diagnosis, which confirmed our hypothesis.

In conclusion, whenever unexpected cardiac troponin-I results are encountered in a inconsistent clinical picture it is wise to ask to the laboratory for their assistance for the probability of false positive results as immunoassays are widely used nowadays and results from antibody interference cause troublesome consequences, misdiagnosis, unnecessary and expensive procedures to investigate this unexpected laboratory abnormality.

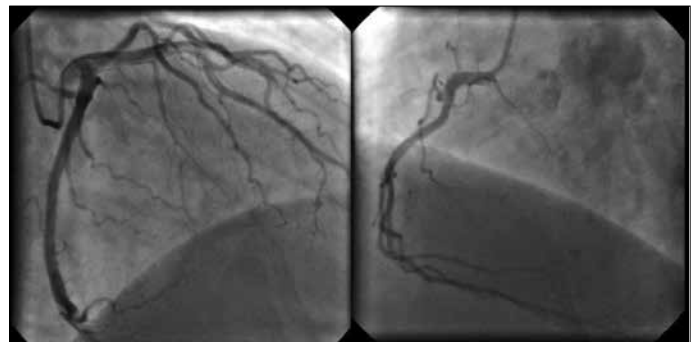


Figure 1. Coronary angiography view of normal coronary arteries