

- balloon valvuloplasty catheter during transcatheter aortic valve replacement. *JACC Cardiovasc Interv* 2017; 10: 1593-5.
- Mustafa A, Farooq V, Manoly I, Hassan R, Fraser DG. Recurrent balloon rupture during transcatheter aortic valve replacement (TAVR)-Implication for access site choice. *Heart Lung Circ* 2015; 24: e193-4.
 - Kasapkara HA, Aslan AN, Durmaz T, Bozkurt E. Bulging sign: A precursor of annular rupture observed before aortic balloon rupture during valvuloplasty in transcatheter aortic valve implantation. *Turk Kardiyol Dern Ars* 2016; 44: 154-7.
 - [No authors listed]. Percutaneous balloon aortic valvuloplasty. Acute and 30-day follow-up results in 674 patients from the NHLBI Balloon Valvuloplasty Registry. *Circulation* 1991; 84: 2383-97.
 - Blanke P, Reinöhl J, Schlensak C, Siepe M, Pache G, Euringer W, et al. Prosthesis oversizing in balloon-expandable transcatheter aortic valve implantation is associated with contained rupture of the aortic root. *Circ Cardiovasc Interv* 2012; 5: 540-8.

Video 1. After the bioprosthesis valve was adjusted to the proper position, the balloon was tried to inflate with opaque saline injection; however, it did not inflate.

Video 2. The re-installed valve was successfully implanted.

Video 3. There were no paravalvular insufficiencies in control aortography after the valve implantation.

Address for Correspondence: Dr. Nermin Bayar, Antalya Eğitim ve Araştırma Hastanesi, Kardiyoloji Bölümü, Öğretmenevleri Mah 914. Sokak 19 Cadde Fetih Konakları B Blok Daire: 5, Konyaaltı, Antalya- Türkiye
Phone: +90 505 400 75 09
E-mail: dr.nermin@mynet.com



©Copyright 2018 by Turkish Society of Cardiology - Available online at www.anatoljcardiol.com
DOI:10.14744/AnatolJCardiol.2018.02170

A different approach to multilayer flow modulator implantation in aortic aneurysm

Cengiz Ovalı, Mustafa Behçet Sevin
Department of Cardiovascular Surgery, Faculty of Medicine, Eskişehir Osmangazi University; Eskişehir-Turkey

Introduction

Thoracoabdominal aortic aneurysms are commonly observed clinical conditions; if remain untreated, the aneurysms might grow larger and cause death due to rupture (1, 2). Since the early 1950s, open surgery approach has been used for the treatment (3). However, with developments in endovascular methods for the last 20 years, percutaneous treatment methods have become an alternative to open surgery. Percutaneous treatment methods have been

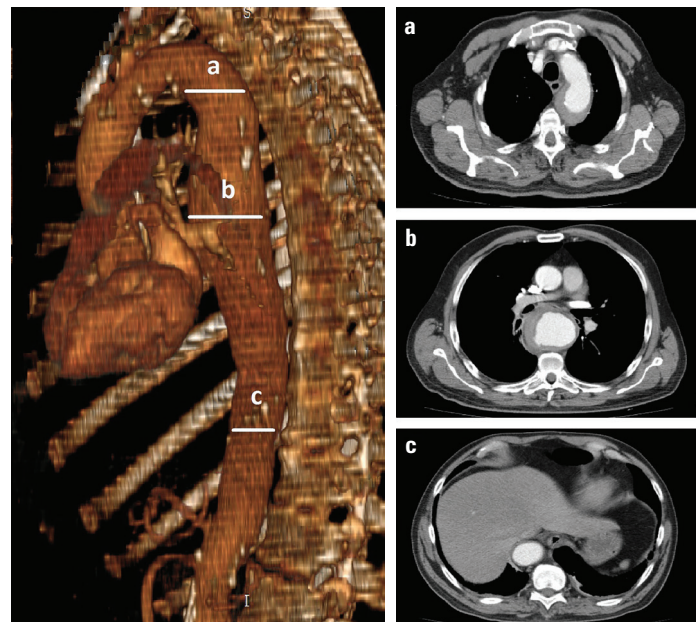


Figure 1. Contrast CT angiography of the aortic aneurysm

increasingly used since they are shown to shorten the duration of intensive care and hospitalization and can be applied in patients with other system problems, can reduce blood loss and transfusion needs, and have lower rates of mortality and morbidity (3, 4).

Certain special endovascular systems have been developed for treating complex aneurysms of the major side branches arising from or nearby the aneurysm sac. Fenestrated stent grafts (5), chimney technique and multilayer flow modulator (MFM) are among the best known endovascular systems (6, 7).

Case Report

A 64-year-old male patient presented to our clinic with chest and back pain. His medical history revealed previous treatment for hypertension and diabetes mellitus for the last 10 years. Critical stenosis in the left and right coronary arteries was detected in coronary angiography; contrast computed tomography showed a 7-cm diameter aortic aneurysm starting from the distal of the left subclavian artery and extending to proximal of the celiac trunk (Fig. 1). Two MFMs (Cardiatis, CTMS 40150) were placed in the aneurysm region for endovascular intervention. However, the targeted region could not be reached due to the insufficient flexibility of the transmission system of the stent and/or anatomy of the aortic arch, an observation that was evident with the presence of the proximal end of the stent angled to the aortic axis (Fig. 2). Consequently, the procedure was terminated; the patient underwent open heart surgery 3 days later, and arterial cannulation was performed from the right subclavian artery after sternotomy. Subsequently, aortotomy was performed in the ascending aorta after total circulatory arrest under antegrade cerebral perfusion. The angulation (Fig. 3) of the MFM stent was corrected by manual guidance. Afterward, an MFM stent was im-

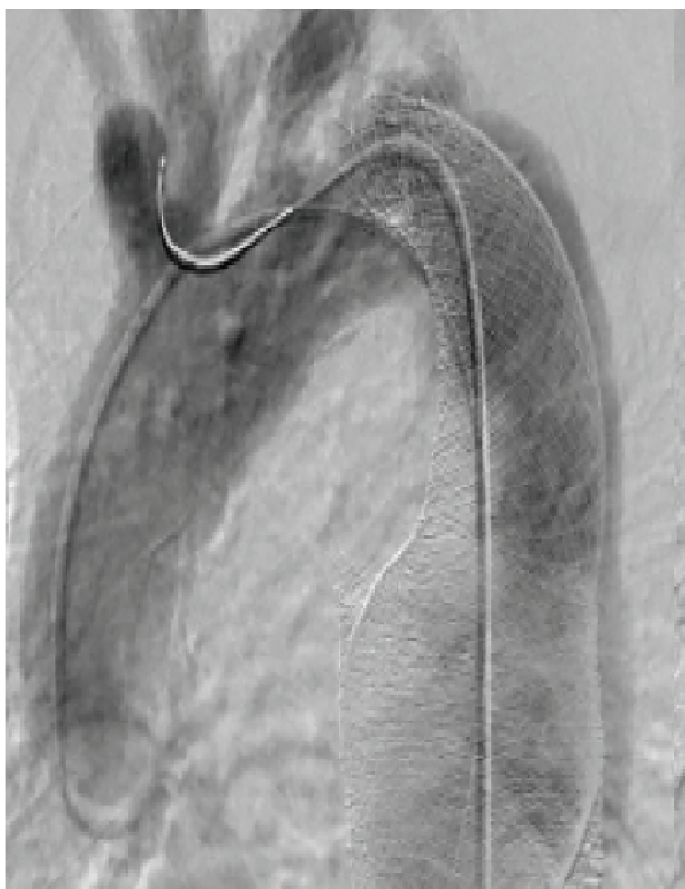


Figure 2. Suboptimal insertion of a multilayer flow modulator placed through the femoral artery

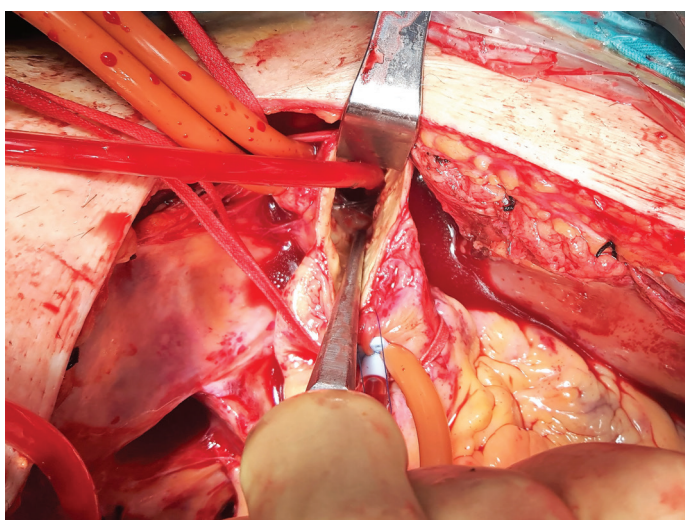


Figure 3. The appearance of arcus aorta in the aortotomy

planted aligning from the T4 vertebra level up to the innominate artery distal (Fig. 4-6). Then, the procedure was continued with coronary bypass. The patient was extubated at the 4th hour after surgery, and no symptoms associated with neurological deficit and/or organ failure were seen. The patient was discharged on the 5th day after operation (Fig. 7).

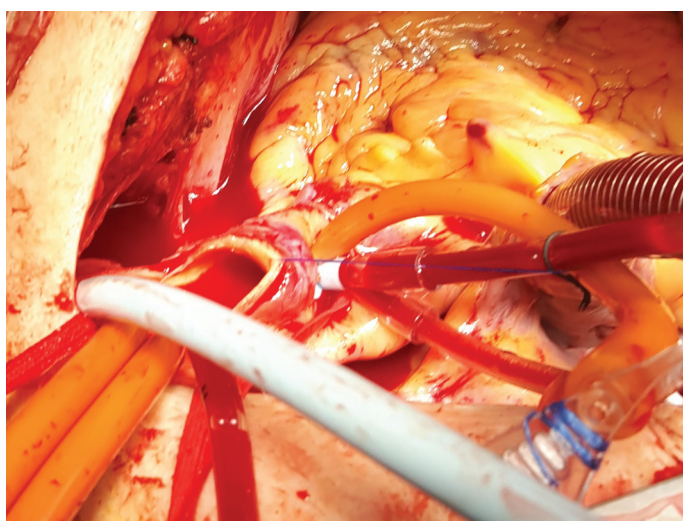


Figure 4. Insertion of the multilayer flow modulator through the aortotomy

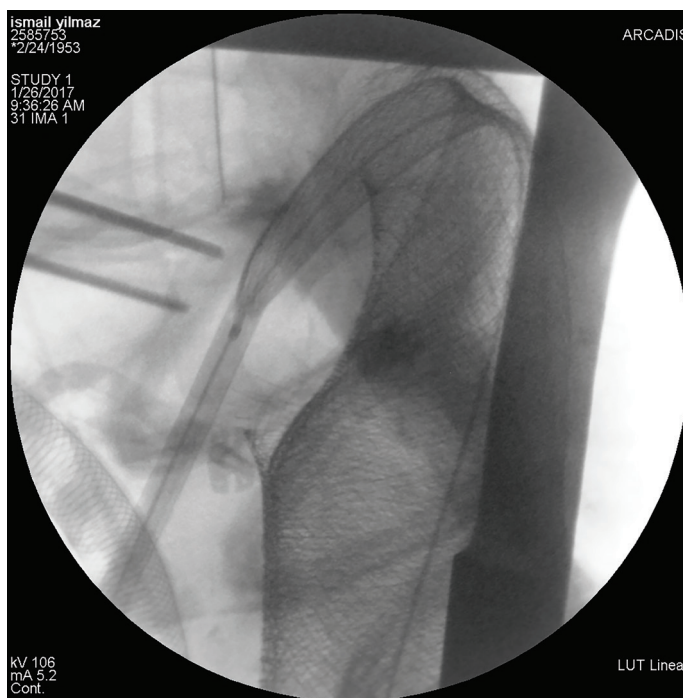


Figure 5. The opening of the multilayer flow modulator

Discussion

Recently, many new approaches have been developed for the treatment of thoracoabdominal aortic aneurysms; among them, endovascular systems have been increasingly used due to lower morbidity and mortality (3, 4). Although the femoral artery (80%) is most commonly used for intervention, iliac, subclavian, and axillary arteries can also be used as alternatives. The diameter of vessel, amount of calcification, and severity of tortuosity are the most important factors for determining the intervention area. The vessel diameter should be at least ≥ 7 mm for 20-22-F introducers.

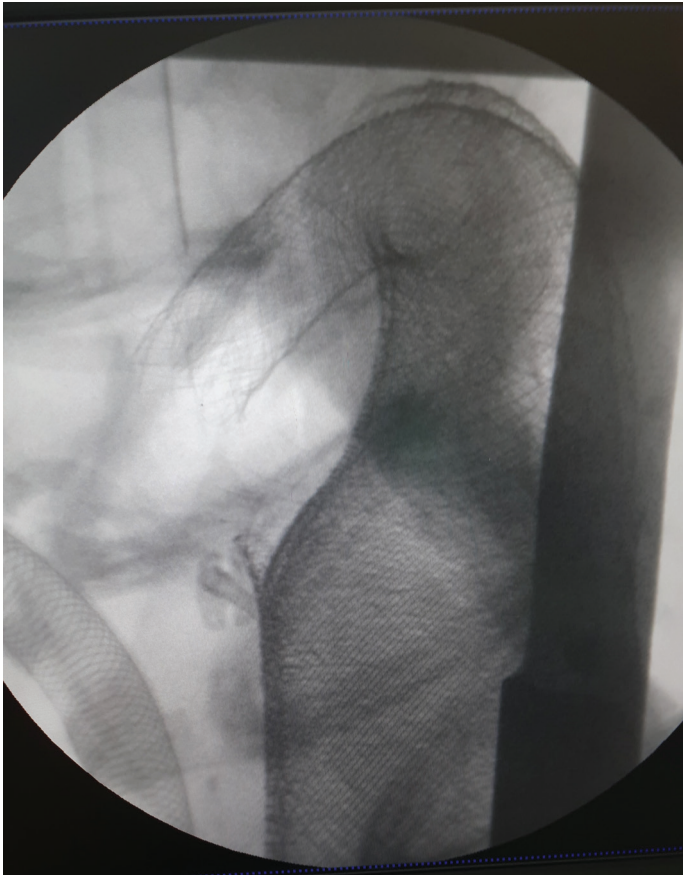


Figure 6. Implantation of the multilayer flow modulator

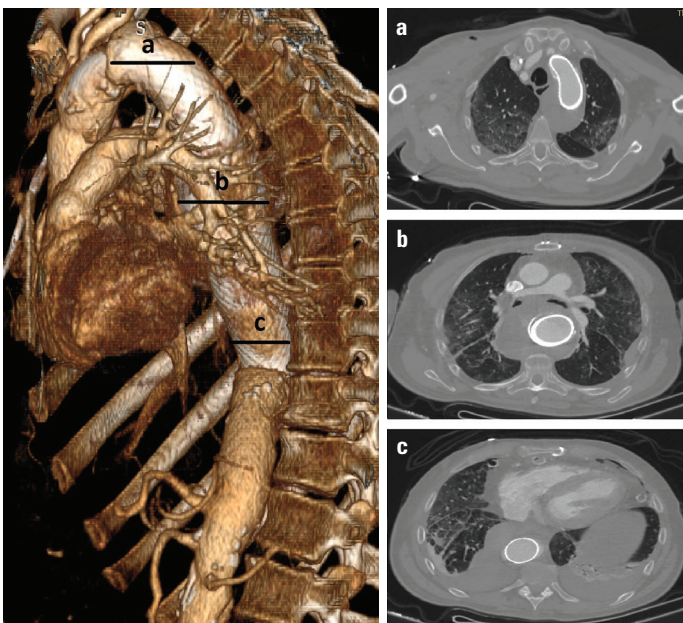


Figure 7. Contrast CT angiography after the operation

The presence of heavy calcification increases the risk of rupture and dissection of the aorta. The amount of calcification not only leads to a decrease in the vessel diameter but also restricts its expandability. Extreme tortuosity in the vessel is another problem

that complicates percutaneous intervention. In the presence of tortuosity, straightening of the vessel can be achieved using strong firm wires. The use of two or three wires can efficiently facilitate straightening of extreme tortuosity in the vessel (8).

When femoral arteries are not suitable for endovascular intervention due to the presence of stenosis and/or calcification, iliac arteries are most commonly used (15%). There are at least a few cases wherein 8-10 mm conduit grafts were anastomosed to iliac arteries. The use of conduit graft facilitates the feasibility of the procedure and significantly decreases the incidence of complication rates (9, 10).

In case no peripheral artery is suitable for the intervention and both mortality and morbidity of the surgical intervention for an aneurysm are high, the endovascular operation can be performed through the ascending aorta after sternotomy. If the patient has an additional pathology that requires open heart surgery, as in our case, one may consider intervening in the extracorporeal circulation and to cut the ascending aorta to perform the surgery. If there is no requirement for an open heart surgery, we believe that the operation can be performed by following these steps: performing an upper ministernotomy without intervening in the extracorporeal circulation, followed by an anastomosis of an 8-10 mm diameter conduit graft to be used as the entry point.

Conclusion

The ascending aorta can be used as an intervention area in the treatment of aortic aneurysms when the endovascular operation cannot be performed due to the difficulty of intervention area or implantation difficulty during operation.

References

1. Erbel R, Aboyans V, Boileau C, Bossone E, Bartolomeo RD, Eggebrecht H, et al; ESC Committee for Practice Guidelines. 2014 ESC Guidelines on the diagnosis and treatment of aortic diseases: Document covering acute and chronic aortic diseases of the thoracic and abdominal aorta of the adult. The Task Force for the Diagnosis and Treatment of Aortic Diseases of the European Society of Cardiology (ESC). *Eur Heart J* 2014; 35: 2873-926. [\[CrossRef\]](#)
2. Boodhwani M, Andelfinger G, Leipsic J, Lindsay T, McMurtry MS, Therrien J, et al; Canadian Cardiovascular Society. Canadian Cardiovascular Society position statement on the management of thoracic aortic disease. *Can J Cardiol* 2014; 30: 577-89. [\[CrossRef\]](#)
3. Dubost C, Allary M, Oeconomos N. Resection of an aneurysm of the abdominal aorta: reestablishment of the continuity by a preserved human arterial graft, with result after five months. *AMA Arch Surg* 1952; 64: 405-8. [\[CrossRef\]](#)
4. Makaroun MS, Dillavou ED, Wheatley GH, Cambria RP; Gore TAG Investigators. Five-year results of endovascular treatment with the Gore TAG device compared with open repair of thoracic aortic aneurysms. *J Vasc Surg* 2008; 47: 912-8. [\[CrossRef\]](#)

5. Moulakakis KG, Mylonas SN, Avgerinos E, Papapetrou A, Kakisis JD, Brountzos EN, et al. The chimney graft technique for preserving visceral vessels during endovascular treatment of aortic pathologies. *J Vasc Surg* 2012; 55: 1497-503. [CrossRef]
6. Debing E, Aerden D, Gallala S, Vandenbroucke F, Van den Brande P. Stenting complex aorta aneurysms with the Cardiatis multilayer flow modulator: first impressions. *Eur J Vasc Endovasc Surg* 2014; 47: 604-8. [CrossRef]
7. Pane B, Spinella G, Perfumo C, Palombo D. A Single Center Experience of Aortic and Iliac Artery Aneurysm Treated with Multilayer Flow Modulator. *Ann Vasc Surg* 2016; 30: 166-74. [CrossRef]
8. Vatakencherry G, Gandhi R, Molloy C. Endovascular Access for Challenging Anatomies in Peripheral Vascular Interventions. *Tech Vasc Interv Radiol* 2016;19: 113-22. [CrossRef]
9. Peterson BG, Matsumura JS. Creative options for large sheath access during aortic endografting. *J Vasc Interv Radiol* 2008; 19(6 Suppl): S22-6. [CrossRef]
10. Jaldin RG, Sobreira ML, Moura R, Bertanha M, Mariaúba JVO, Pimenta REF, et al. Unfavorable iliac artery anatomy causing access limitations during endovascular abdominal aortic aneurysm repair: application of the endoconduit technique. *J Vasc Bras* 2014; 13: 318-24. [CrossRef]

Address for Correspondence: Dr. Cengiz Ovalı,
Eskişehir Osmangazi Üniversitesi Tıp Fakültesi,
Kalp ve Damar Cerrahisi Anabilim Dalı,
Eskişehir- Türkiye
Phone: +90 222 239 29 79
E-mail: drcengizovali@gmail.com
©Copyright 2018 by Turkish Society of Cardiology - Available online
at www.anatoljcardiol.com
DOI:10.14744/AnatolJCardiol.2018.49274

