

May positive U waves in V1-V3 leads predict left main coronary artery occlusion?

V1-V3 derivasyonlardaki pozitif U dalgaları sol ana koroner arter oklüzyonunu öngörebilir mi?

A 41 years old male presented with unstable angina pectoris. Electrocardiography on admission revealed marked positive U waves in V1-V3 chest leads on electrocardiography (Fig. 1). Transthoracic echocardiography revealed a normal left ventricular ejection fraction. Early coronary angiography revealed critical occlusion of the distal left main coronary artery (LMCA) (Fig. 2). Coronary artery bypass surgery was offered to the patient. The characteristic electrocardiography patterns suggestive of the LMCA as culprit vessel are (1): ST depression in leads II, III or aVF (highest sensitivity 88%), ST elevation in both aVR and aVL (highest specificity 98%), ST elevation in aVR less than the ST elevation in V1 and right bundle branch block and left anterior fascicular block. Yamaji et al (2) showed that ST elevation in aVR greater than or equal to that in V1 distinguished LMCA group from left anterior descending coronary artery disease group with 81% sensitivity, 80% specificity and 81% accuracy. Other sensitive criteria of LMCA disease are ST deviation in $V6-V1 \geq 0$ and $V6/V1 \geq 1$ described by Mahajan et al (3) in the largest series of electrocardiography analysis on acute coronary syndrome resulting from culprit LMCA lesion. However, to the best of our knowledge, the relationship between positive U wave and LMCA occlusion has not been reported in the literature so far. Our patient is the first case showing this relationship in the literature.

Ersan Tatlı, Tarık Yıldırım, Meryem Aktoz, Mutlu Büyüklü
Department of Cardiology, Trakya University School of Medicine,
Edirne, Turkey

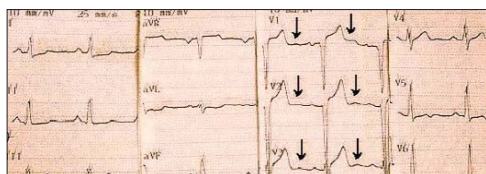


Figure 1. Electrocardiography on admission showing positive U waves in V1-V3 leads

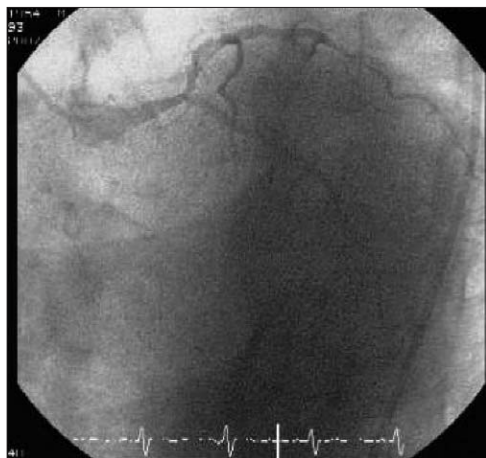


Figure 2. Left coronary angiogram showing critical occlusion of the distal left main coronary artery

References

1. Kurisu S, Inoue I, Kawagoe T, Ishihara M, Shimatani Y, Nakamura S, et al. Electrocardiographic features in patients with acute myocardial infarction associated with left main coronary artery occlusion. *Heart* 2004; 90: 1059-60.
2. Yamaji H, Iwasaki K, Kusachi S, Murakami T, Hirami R, Hamamoto H, et al. Prediction of acute left main coronary artery obstruction by 12 lead electrocardiography. ST elevation in lead aVR with less ST segment elevation in V1. *J Am Coll Cardiol* 2001; 38: 1348-54.
3. Mahajan N, Hollander G, Thekkoot D, Temple B, Malik B, Abrol S, et al. Prediction of left main coronary artery obstruction by 12-lead electrocardiography: ST segment deviation in lead V6 greater than or equal to ST segment deviation in lead V1. *Ann Noninv Electrocardiol* 2006; 11: 102-12.

Address for Correspondence/Yazışma Adresi: Dr. Ersan Tatlı
Trakya University School of Medicine, Cardiology, Edirne, Turkey
Phone: +90 284 235 76 41/2100 Fax: +90 284 235 23 05 E-mail: ersantatli@yahoo.com

A rare pathogen causing endocarditis: Streptococcus constellatus

Endokardite neden olan ender bir patojen: Streptococcus constellatus

Herein we reported a 35-year-old man who developed endocarditis caused by Streptococcus (S) constellatus, a member of *S. milleri* group. Unlike other viridans streptococci, members of the *S. milleri* group rarely cause infective endocarditis.

A 35-year-old male patient was admitted to our clinic with complaints of tiredness, night sweating, cough and fever lasting two months. On clinical examination, vital signs except body temperature (39.5°C) were within normal limits. We detected 2/4th grade diastolic murmur along left sternal border. His blood analysis revealed hematocrit 45%, leucocytes 16500/mm³, ESR 75 mm/h. On his transthoracic echocardiographic examination severe aortic regurgitation, mild degree aortic stenosis (peak gradient 21 mmHg) and multiple vegetations on the aortic cusps (maximum diameter 9X5 mm) were seen (Fig.1). Two blood cultures for aerobic and anaerobic pathogens were immediately taken and therapy with penicillin G-gentamycin combination was initiated.

From blood cultures evaluated with The BacT/ALERT and the BACTEC 9240 systems viridans streptococci were isolated. Despite intensive antibiotic therapy, the patient's general condition was not improved, and hence, another set of blood cultures was obtained. The isolates grew well and had pinpoint colonies of alpha-hemolysis on 5% defibrinated sheep blood agar (Salubris, Turkey) in 5% CO₂ and ambient air at 37°C. They were catalase-negative and gram-positive cocci. The isolate was identified as *S. constellatus* by both the API Rapid ID32 Strep system (bioMerieux, France) and REMEL Rapid STR system (Apogent-USA). The isolate was susceptible to ceftriaxone, chloramphenicol, erythromycin, ofloxacin, cefotaxime, tetracycline, levofloxacin, and vancomycin but resistant to penicillin G. We immediately changed the antibiotic treatment to cefotaxime 2x4 g IV per day. However, the persistence of vegetations on control transthoracic echocardiogram repeated three days later led us to transfer the patient to cardiac surgery clinic for aortic valve replacement with St Jude mechanical valve. Intraoperative and postoperative course was uneventful. We continued cefotaxime therapy for another six week and the patient discharged on the postoperative 20th day.

Nearly all microorganisms can cause infective endocarditis especially gram-positive cocci and the so-called HACEK microorganisms (1). Furthermore, viridans streptococci are the leading cause of native valve endocarditis especially in subacute cases (1).