

## Short-long-short sequence-induced torsade de pointes after transcatheter aortic-valve implantation

**Kevser Gülcihan Balcı, Mustafa Mücahit Balcı, Samet Yılmaz, Orhan Maden**  
**Clinic of Cardiology, Türkiye Yüksek İhtisas Education and Research**  
**Hospital; Ankara-Turkey**

### Introduction

The gold-standard treatment of symptomatic aortic stenosis (AS) is surgical aortic-valve replacement (SAVR); however, many patients owing to high operative risks are not candidates for this treatment (1). Hence, transcatheter aortic-valve implantation (TAVI) was introduced to be an alternative modality to SAVR. Because of older patient population and structural heart disease, TAVI patients may have proarrhythmic tendencies related to electrolyte imbalances and drug-drug interactions. Among patients with pacemakers, implantable cardioverter-defibrillators (ICD), and cardiac resynchronization therapy (CRT) receivers, the proarrhythmic effect of pacing was described earlier (2-4). Torsades de pointes (TdP) is a polymorphic ventricular tachycardia in the setting of a prolonged QTc interval (5); however, pacing related episodes and triggered activity related TdP in AS patients were cited in several reports (2-4, 6, 7). This report describes a 78-year-old patient being VVI paced, who experienced a short-long-short sequence-induced TdP without QT prolongation in intensive care unit after TAVI.

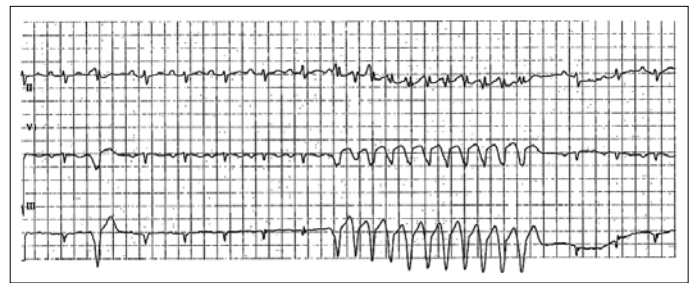
### Case Report

Seventy-eight-year-old female was admitted to the hospital with progressive dyspnea. She underwent pacemaker implantation two months ago because of an intermittent third-degree atrioventricular block. The initial transthoracic echocardiography (TTE) revealed severe AS (mean gradient, 50 mm Hg; aortic-valve area, 0.8 cm<sup>2</sup>) and mild aortic regurgitation with normal ejection fraction (65%). The heart team decided to perform TAVI via a trans-femoral approach utilizing a 29-mm CoreValve (Medtronic, Minneapolis, MN) successfully 3 days after coronary intervention. Post-procedural TTE showed a well-functioning bioprosthetic valve and mild aortic insufficiency.

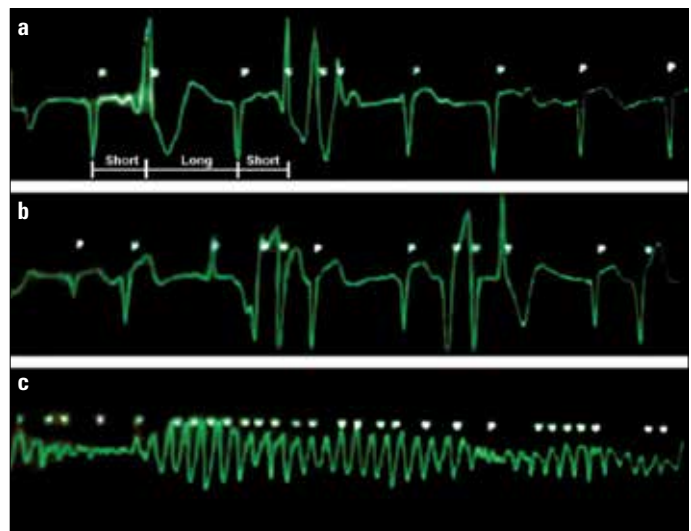
On the post-procedural third day, ventricular extrasystoles (VES) with short-long-short sequences and non-sustained ventricular tachycardia (VT) with right bundle branch block pattern (RBBB) were seen on the monitor (Fig. 1). The patient later experienced TdP (Fig. 2). Following 300 J defibrillation, regular rhythm was maintained. There was no QT prolongation (QT=420 milliseconds) and pacemaker malfunction, and her electrolytes were within normal limits. She had no ischemic symptoms or electrocardiogram (ECG) abnormalities. Although we increased pacemaker basic rate to 80 beat/minute, because of the absence of a conclusive cause of TdP, the heart team decided to upgrade the pacemaker to a dual chamber pacemaker-defibrillator (DDD-ICD) as it would be safer for the patient. The patient was discharged from the hospital after 2 days of ICD implantation with good clinical condition.

### Discussion

In the elderly population, AS is a common medical problem. Patients with severe symptomatic AS with high risk profile are candi-



**Figure 1. Morphology of ventricular extra-systoles and ventricular tachycardia indicate the origin of arrhythmia from left ventricular outflow tract**



**Figure 2. a-c. Short-long-short sequence (a, b). Torsade de pointes (c)**  
 dates for TAVI and tend to be older than those who undergo SAVR. Therefore, they may be more susceptible to arrhythmias. Not only treating the underlying heart condition, but also the post-procedural care of the older patients and managing the complications may be important for the outcome.

Most common arrhythmias are bradycardia and atrioventricular block after TAVI, and it has been shown that approximately every 7<sup>th</sup> patient undergoing TAVI requires a permanent pacemaker after the procedure (8). Tachycardia is unusual and there are a few case reports presenting VT after TAVI procedure in the literature (9, 10). However, our case is the first one presenting TdP after TAVI. In our case, the origin of VES and VT were most probably the left ventricular outflow tract (LVOT) because of RBBB morphology in ECG. Patient underwent pacemaker implantation two months before TAVI. Before pacemaker implantation, the rate of the idioventricular rhythm was 30/minute, and QT was 470 milliseconds. In our case, after pacemaker implantation, the measured QT interval was 420 milliseconds at a rate of 65 beats/minute; however, the right ventricular apex pacing could disguise left ventricular electrical remodeling as well as QT prolongation, which may enhance the susceptibility for arrhythmias in such patients.

Furthermore, in AS patients, hypertrophic myocardium may generate the substrate for arrhythmias via triggered activity (6). Vos et al. (7) showed that six weeks after creating a complete AV block in the dog leads to electrical remodeling due to the altered electrophysiological properties of the hypertrophic myocardium and subsequently an

arrhythmogenic susceptibility. Short-long-short sequences that led to TdP may have been the manifestation of triggered activity in our case. Therefore, we performed DDD-ICD implantation for the prevention of sudden cardiac death.

## Conclusion

In this case, we emphasize the precise care of post-procedural TAVI patients. They are older and fragile; therefore, may be the candidates for arrhythmias. Despite the treatment of severe AS with either TAVI or surgery, a tendency toward arrhythmia may remain as the reverse remodeling process continues. Even after a successful intervention, an unexpected death can occur due to malignant arrhythmias.

## References

1. Alsara O, AlSarah A, Laird-Fick H. Advanced age and the clinical outcomes of transcatheter aortic valve implantation. *J Geriatr Cardiol* 2014; 11: 163-70.
2. Turitto G, Haq S, Benson D, El-Sherif N. Torsade de pointes: an electrophysiological effect of cardiac resynchronization? *Pacing Clin Electrophysiol* 2006; 29: 520-2. [\[CrossRef\]](#)
3. Sweeney MO, Ruetz LL, Belk P, Mullen TJ, Johnson JW, Sheldon T. Bradycardia pacing-induced short-long-short sequences at the onset of ventricular tachyarrhythmias: a possible mechanism of proarrhythmia? *J Am Coll Cardiol* 2007; 50: 614-22. [\[CrossRef\]](#)
4. Fisher JD. Pacemaker pro-arrhythmia: beyond spike-on-T and endless loop tachycardia. *J Am Coll Cardiol* 2007; 50: 623-5. [\[CrossRef\]](#)
5. Drew BJ, Ackerman MJ, Funk M, Gibler WB, Kligfield P, Menon V, et al. Prevention of torsade de pointes in hospital settings: a scientific statement from the American Heart Association and the American College of Cardiology Foundation. *J Am Coll Cardiol* 2010; 55: 934-47. [\[CrossRef\]](#)
6. Dilaveris P, Vassilopoulos C, Tsagga E, Vavuranakis M, Stefanadis C. Torsades de pointes as a cause of sudden death in a patient with aortic stenosis and atrial fibrillation. *Ann Noninvasive Electrocardiol* 2006; 11: 284-6. [\[CrossRef\]](#)
7. Vos MA, de Groot SH, Verduyn SC, van der Zande J, Leunissen HD, Cleutjens JP, et al. Enhanced susceptibility for acquired torsade de pointes arrhythmias in the dog with chronic, complete AV block is related to cardiac hypertrophy and electrical remodeling. *Circulation* 1998; 98: 1125-35. [\[CrossRef\]](#)
8. Erkapic D, De Rosa S, Kelava A, Lehmann R, Fichtlscherer S, Hohnloser SH. Risk for permanent pacemaker after transcatheter aortic valve implantation: a comprehensive analysis of the literature. *J Cardiovasc Electrophysiol* 2012; 23: 391-7. [\[CrossRef\]](#)
9. Dvir D, Haim M, Kornowski R. Left-ventricular outflow tract ventricular tachycardia event following CoreValve transcatheter aortic-valve implantation. *Catheter Cardiovasc Interv* 2012; 79: 331-3. [\[CrossRef\]](#)
10. Beinart R, Danik S, Palacios I, Barrett C, Inglessis I, Agnihotri A, et al. Ventricular tachycardia following trans-apical aortic valve replacement. *Europace* 2012; 14: 450-2. [\[CrossRef\]](#)

**Address for Correspondence:** Dr. Samet Yılmaz,  
Türkiye Yüksek İhtisas Eğitim ve Araştırma Hastanesi  
06100, Ankara-Türkiye  
Phone: +90 507 305 58 83  
Fax: +90 312 306 10 00  
E-mail: sametyilmazmd@gmail.com



©Copyright 2015 by Turkish Society of Cardiology - Available online at [www.anatoljcardiol.com](http://www.anatoljcardiol.com)  
DOI: 10.5152/akd.2015.6120

# *Elizabethkingia meningosepticum* endocarditis: A rare case and special therapy

Jing Yang, Wencheng Xue\*, Xiaonan Yu\*\*

Departments Infection Control, \*Clinical Laboratory, \*\*Transfusion General Hospital of Shenyang Military Area Command, Shenyang-China

## Introduction

Among the *Elizabethkingia* species, *E. meningosepticum* is the most pathogenic member of genus. As primarily opportunistic pathogens, they majorly cause meningitis in premature and newborn infants and rarely cause pneumonia, endocarditis, and meningitis in immunocompromised adults (1). Here we describe an adult patient with an *E. meningosepticum* endocarditis who had no underlying diseases. To the best of our knowledge, this is the first documented case of this type in China.

## Case Report

A 66-year-old man was admitted to the emergency department of our hospital with heart failure, respiratory failure, renal failure, and bilateral pleural effusion. He had been admitted in another hospital due to fever and chest pain 2 days before. The patient was referred to our hospital because he had chest distress, shortness of breath, and could not lie on his back. He had no history of hypertension or diabetes. At the time of admission, he had a temperature of 37.2°C, BP of 131/47 mm Hg, pulse of 105 beats/min, and respiratory rate of 36 breaths/min. Hemogram showed WBC count of  $18.9 \times 10^9$  cells/L with 83% neutrophils. The levels of TNT, blood urea, creatinine, LDH, CysC, ProBNP, and d-dimer were 0.175 ng/mL, 20.17 mmol/L, 159.0  $\mu$ mol/L, 378.0 U/L, 2.39 mg/L, 31386.7 pg/mL, and 0.6  $\mu$ g/mL, respectively. HIV, HBsAg, and HCV ELISA showed negative results. Echocardiography revealed left ventricular enlargement, decreased cardiac function, aortic valve prolapse, moderate aortic insufficiency, mild to moderate mitral regurgitation, and trace of pericardial effusion. He was administered symptomatic treatment and etapenem due to the probable lower respiratory tract infection.

The blood cultures grew Gram-negative bacilli after 28 of incubation at 37°C on the third day after admission. The Gram-negative rod was nonmotile and catalase- and oxidase-positive. Consequently, it was identified as *E. meningosepticum* using VITEK2 Gram-negative identification card (bioMérieux) because was sensitive to piperacillin-tazobactam, imipenem, meropenem, levofloxacin, minocycline, cefepime, piperacillin, ceoperazone-sulbactam, ticarcillin-clavulanic acid, vancomycin, teicoplanin, and rifampicin and resistant to aztreonam, ceftazidime, gentamicin, and amikacin. Vegetative culture was also positive for *E. meningosepticum*. It had the same resistance phenotype with that organism isolated from blood. The sputum culture showed normal flora.

The patient was treated on the lines of acute bacterial endocarditis with injections of Vancomycin 1 g/12 h intravenously initially; the dose was reduced to 0.5 g/week later as the patient became afebrile and his subsequent blood cultures were sterile. Aortic valve replacement and intracardiac aortic sinus aneurysm repair surgery was then performed. However, 11 days later he developed *Acinetobacter baumannii* septicemia and cardiac arrest and died despite resuscitative measures.