

consolidation (Fig. 2a, 2b). Ticagrelor was stopped and oxygen therapy started. On the 2nd day, hemoptysis stopped, and the infiltration of the lung areas decreased on chest radiography (Fig. 1c). The patient was discharged on the 8th day with clopidogrel as the second antiplatelet regimen.

Discussion

Alveolar hemorrhage caused by antiplatelet medication is a rare complication of ACS. There is only a limited number of case reports related to DAH due to ticagrelor in the literature before (2, 3). Yıldırım et al. (2) reported a 54-year-old man who took ticagrelor therapy due to ACS and developed DAH 4 days after ticagrelor use. However, the patient died due to septic shock on the 35th day. Whitmore et al. (3) reported a patient who used ticagrelor 90 mg BID and aspirin 100 mg daily following stenting. Their patient presented with hemoptysis, and CT imaging showed bilateral ground-glass opacities consistent with pulmonary hemorrhage. They stopped ticagrelor therapy and continued with aspirin, and DAH improved (3). These two cases were relatively more unstable than our patients after procedure. One of them had a cardiac arrest after the admission and died due to sepsis. The second one presented to the hospital with pneumonia. However, our cases were stable after coronary angiography and developed hemoptysis abruptly.

DAH is a life-threatening clinical syndrome characterized by common radiographic findings of pulmonary hemorrhage, hypoxic respiratory insufficiency, and hemoptysis. The most common causes of DAH are pulmonary capillary hypertension, systemic vasculitis (microscopic polyangiitis, Wegener granulomatosis), and rheumatologic diseases (rheumatoid arthritis, systemic lupus erythematosus). The diagnosis of DAH is based on clinical, radiographic, bronchoscopic, and pathologic examination. Sometimes, the diagnosis of DAH is made by exclusion of other reasons related to dyspnea. DAH is frequently clinically confused with acute pulmonary edema and may lead to false diagnosis.

The most probable cause of DAH in our cases was the antiplatelet action of ticagrelor. Patients were discharged from hospital with clopidogrel, and there was no bleeding event after discharge. Although clopidogrel also has an antiplatelet effect, ticagrelor has a stronger effect on platelet aggregation. This may be the explanation of hemoptysis with ticagrelor but not clopidogrel. Another explanation may be that ticagrelor induced pneumonia due to drug hypersensitivity. Histopathologic diagnosis is required for demonstrating this drug reaction. However, biopsy was not done in our patients. Therefore, exclusion of this cause is not possible at this time.

The proper treatment of DAH depends on the underlying reason. Immunosuppressive treatment is the basis of treatment in patients with DAH associated with systemic vasculitis and rheumatic diseases (4). However, there is no definitive treatment algorithm for DAH due to antiplatelet agents. First, all drugs with antiplatelet or antithrombotic effect should be cut and reversed as soon as possible. Second, oxygen, bronchodilators, intubation, and mechanical ventilation should be given.

In the present case, it is important to consider the differential diagnosis of DAH due to antithrombotic treatment. After other causes of DAH were excluded, the symptoms of DAH were improved in follow-up, and patients were discharged from hospital with transitions from ticagrelor to clopidogrel.

References

1. Valgimigli M, Bueno H, Byrne RA, Collet JP, Costa F, Jeppsson A, et al.; ESC Scientific Document Group. 2017 ESC focused update on dual antiplatelet therapy in coronary artery disease developed in collaboration with EACTS. *Eur J Cardiothorac Surg* 2018; 53: 34-78.
2. Yıldırım F, Kara İ, Okuyan H, Abacı A, Türkoğlu M, Aygencel G. Diffuse alveolar hemorrhage associated with low molecular weight heparin and dual anti-platelet therapy after percutaneous coronary intervention. *Clin Respir J* 2017; 11: 1071-3.
3. Whitmore TJ, O'Shea JP, Starac D, Edwards MG, Waterer GW. A case of pulmonary hemorrhage due to drug-induced pneumonitis secondary to ticagrelor therapy. *Chest* 2014; 145: 639-41.
4. Lara AR, Schwarz MI. Diffuse alveolar hemorrhage. *Chest* 2010; 137: 1164-71.

Address for Correspondence: Dr. Samet Yılmaz,
Pamukkale Üniversitesi Hastaneleri,
Kardiyoloji Kliniği, Çamlaraltı Mah. Kalp Merkezi No: 7
Pamukkale/Denizli- Türkiye
Phone: +90 507 305 58 83
E-mail: sametyilmazmd@gmail.com
©Copyright 2018 by Turkish Society of Cardiology - Available online
at www.anatoljcardiol.com
DOI: 10.14744/AnatolJCardiol.2018.47776



Extreme example of early repolarization

İb Gökhan Altunbaş, İb Ertan Vuruşkan, İb Murat Sucu
Department of Cardiology, Faculty of Medicine, Gaziantep University;
Gaziantep-Turkey

Introduction

Once accepted as a benign phenomenon, electrocardiographic early repolarization pattern is now considered to have significant clinical importance. Haïssaguerre et al. (1) were first to describe the possible association between early repolarization pattern and idiopathic ventricular fibrillation. Since then, numerous studies have documented the clinical association between early repolarization pattern and future arrhythmic events. Due to different definitions, the prevalence of early repolarization pattern varies widely between 2% and 31% (2). The 2015 European Society of Cardiology Guidelines for the management of ventricular arrhythmias and the prevention of sudden cardiac death recommend that early repolarization syndrome (ERS) should be diagnosed only in patients with early repolarization pattern on electrocardiography (ECG) and a history of resuscitated cardiac

arrest or a documented episode of ventricular fibrillation and/or polymorphic ventricular tachycardia (3). Also, due to lack of clear evidence, the panel experts could not make recommendations for the management.

Case Report

A 68 year-old woman presented to our outpatient clinic for preoperative evaluation before total knee replacement. ECG showed atrial fibrillation with ST-segment elevation on precordial and inferior derivations, most striking in V3 through V6 (Fig. 1). ECG was alarming but there was no chest pain, and anamnesis revealed that the patient previously had an abnormal ECG. In addition, coronary angiography was performed twice, first 3 years ago and the second one last year in different hospitals, which showed normal coronary artery anatomy. Thus, previous hospital records were also evaluated, which revealed identical ECG findings (Fig. 2). Troponin was also negative, and thus, ECG findings were accepted as early repolarization pattern. Transthoracic echocardiography revealed normal left ventricular systolic function, biatrial enlargement, and moderate rheumatic mitral regurgitation. We wanted to perform a provocative test with ajmaline to reveal if the patient had Brugada syndrome (BrS), but the patient absolutely denied the procedure due to need for intensive care unit hospitalization and minor risk of triggering lethal arrhythmias. The patient was taking rivaroxaban 20 mg, metoprolol 50 mg, candesartan/hydrochlorothiazide 16/12.5 mg, and digoxin 0.25 mg half tablet daily (1×1/2). The patient did not have any history of syncope or aborted sudden death. Perioperative recommendations were made, and the patient underwent uneventful total knee arthroplasty surgery. Routine follow-up was recommended at hospital discharge.

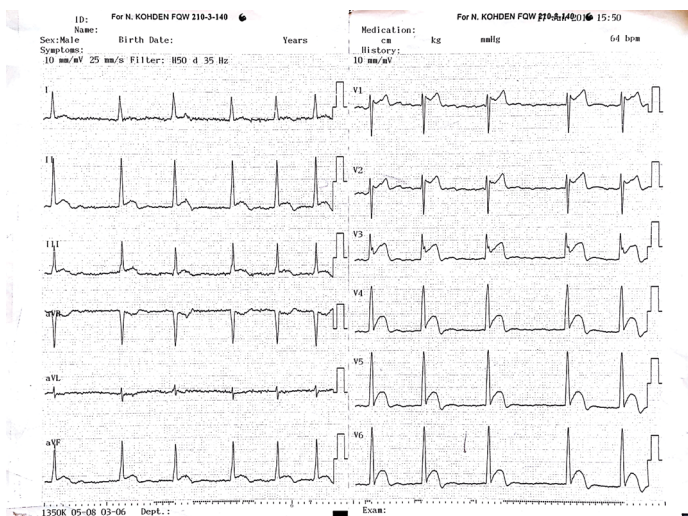


Figure 1. ECG shows atrial fibrillation. ST elevations are most prominent in V3, which also has a notch on the descending part of QRS compatible with early repolarization

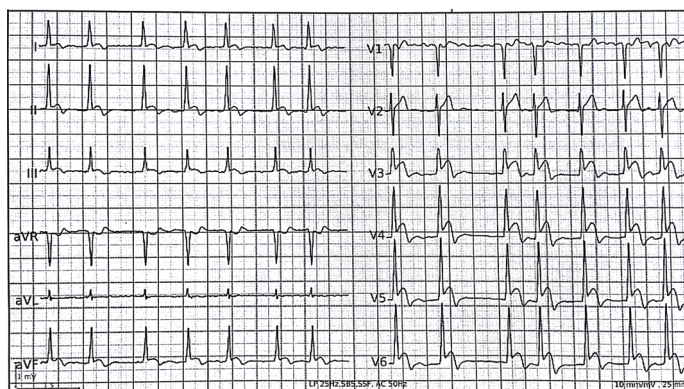

Figure 2. ECG done in the last year showing similar findings

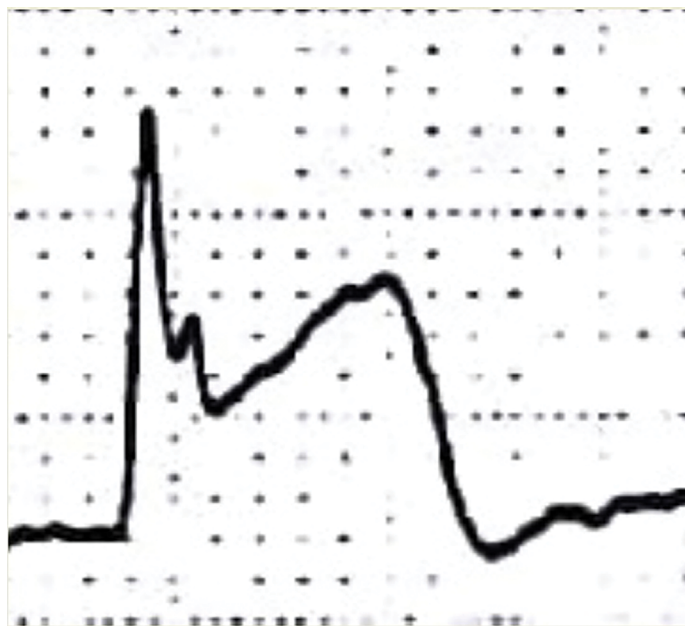


Figure 3. A magnified view of V3 from Figure 1 clearly showing the notch and exaggerated ST elevation

Discussion

We have presented an extreme example of ECG that can only be explained by early repolarization pattern.

In the current ECG (Fig. 1), the QRS pattern in V1 suggests the Brugada pattern, but ST-segment elevation in V3 through V6 could not be explained by the Brugada pattern. ST-segment elevation in V2 resembles the type 2 Brugada pattern; however, currently, only type 1 ECG pattern is accepted as diagnostic for BrS. Digoxin use was also considered as diagnostic, but as already known, digoxin is associated with "sagging" ST depression; thus, it was ruled out. Since coronary angiography was performed twice and revealed normal coronary artery anatomy, myocardial ischemia was also ruled out.

There is a semantic confusion regarding early repolarization pattern and the J wave. However, a recent consensus document has made clear recommendations (4). First, J point was defined

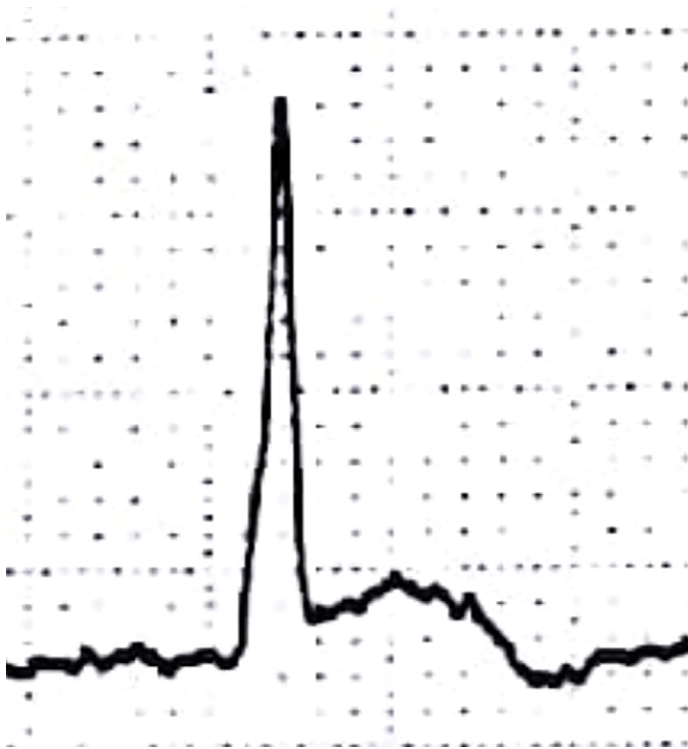


Figure 4. A magnified view of aVF from Figure 1 showing rapidly upsloping ST elevation

as the onset or peak of the ST segment. The consensus proposes the following definition: J onset (Jo) suggests the onset of a notch, J peak (Jp) suggests the peak of a notch or onset of a slur, and J termination (Jt) suggests the end of a notch or slur. The report also emphasizes that ST-segment elevation without a slur or notch cannot be accepted as early repolarization. Our patient had a notch on the descending part of QRS, most visible in V3. Figure 3 is a magnified picture of the V3 derivation from Figure 1, which clearly delineates the notch on the descending limb of the QRS complex.

Tikkanen et al. (5) revealed that the presence of early repolarization pattern on the surface ECG does not indicate increased arrhythmic risk per se; rather, the morphology of the ST segment defines the risk of sudden death. In their study, they found that early repolarization with rapidly upsloping ST segment is not associated with arrhythmic risk; however, early repolarization with horizontal or descending ST segment is significantly associated with an increased risk of arrhythmic death. Our patient had rapidly upsloping ST elevation. Figure 4 is a magnified view of Figure 1; aVF derivation clearly shows ST elevation >1 mm with a rapidly upsloping pattern. This was also compatible with findings of the Tikkanen et al.'s (6) study since our patient did not have any history of aborted sudden death.

The localization of the ST-segment elevation is also important with respect to the risk of arrhythmic death. Two major population-based studies consistently showed that inferior localization of early repolarization pattern carries the highest risk of arrhythmic death (6, 7). Our case had minimal ST elevation on leads II, III, and aVF, but there was no notch or slur; thus, this cannot be accepted as early repolarization pattern.

J wave syndrome is an umbrella term comprising BrS and ERS. There are many similarities between these two entities. One major difference is the localization of the affected region; the anterior right ventricular outflow tract is the most affected segment in BrS, and the inferior region of the left ventricular wall is the most affected segment in ERS (8). It is common to see the two ECG patterns in the same patient.

Conclusion

Herein, we presented an extreme example of electrographic early repolarization pattern. Since our patient did not experience aborted sudden death or sustained ventricular tachycardia attacks, this was accepted solely as an ECG phenomenon.

References

- Haïssaguerre M, Derval N, Sacher F, Jesel L, Deisenhofer I, de Roy L, et al. Sudden cardiac arrest associated with early repolarization. *N Engl J Med* 2008; 358: 2016-23. [\[CrossRef\]](#)
- Maury P, Rollin A. Prevalence of early repolarization/J wave patterns in the normal population. *J Electrocardiol* 2013; 46: 411-6.
- Priori SG, Blomström-Lundqvist C, Mazzanti A, Blom N, Borggrefe M, Camm J, et al.; ESC Scientific Document Group. 2015 ESC Guidelines for the management of patients with ventricular arrhythmias and the prevention of sudden cardiac death: The Task Force for the Management of Patients with Ventricular Arrhythmias and the Prevention of Sudden Cardiac Death of the European Society of Cardiology (ESC). Endorsed by: Association for European Paediatric and Congenital Cardiology (AEPC). *Eur Heart J* 2015; 36: 2793-867. [\[CrossRef\]](#)
- Macfarlane PW, Antzelevitch C, Haïssaguerre M, Huikuri HV, Potse M, Rosso R, et al. The early repolarization pattern: a consensus paper. *J Am Coll Cardiol* 2015; 66: 470-7. [\[CrossRef\]](#)
- Tikkanen JT, Junttila MJ, Anttonen O, Aro AL, Luttinen S, Kerola T, et al. Early repolarization: electrocardiographic phenotypes associated with favorable long-term outcome. *Circulation* 2011; 123: 2666-73.
- Tikkanen JT, Anttonen O, Junttila MJ, Aro AL, Kerola T, Rissanen HA, et al. Long-term outcome associated with early repolarization on electrocardiography. *N Engl J Med* 2009; 361: 2529-37. [\[CrossRef\]](#)
- Sinner MF, Reinhard W, Müller M, Beckmann BM, Martens E, Perz S, et al. Association of early repolarization pattern on ECG with risk of cardiac and all-cause mortality: a population-based prospective cohort study (MONICA/KORA). *PLoS Med* 2010; 7: e1000314. [\[CrossRef\]](#)
- Antzelevitch C, Yan GX, Ackerman MJ, Borggrefe M, Corrado D, Guo J, et al. J-Wave syndromes expert consensus conference report: Emerging concepts and gaps in knowledge. *Europace* 2017; 19: 665-94.

Address for Correspondence: Dr. Gökhan Altunbaş,

Gaziantep Üniversitesi Tıp Fakültesi,

Kardiyoloji Anabilim Dalı,

Gaziantep- Türkiye

Phone: +90 342 360 60 60

E-mail: drgokhanaltun@gmail.com

©Copyright 2018 by Turkish Society of Cardiology - Available online at www.anatoljcardiol.com

DOI:10.14744/AnatolJCardiol.2018.14265

