

# Left main bronchus as a guide for individualized transseptal puncture using a conventional fluoroscopic approach in cryoballoon ablation of atrial fibrillation

Yuan Yuan, Minxia Zhang<sup>1</sup>, Wangwei Yang, Ling Tao, Hexiang Cheng

Department of Cardiology, Xijing Hospital, Fourth Military Medical University (Air Force Medical University); Xi'an-China

<sup>1</sup>Department of Cardiology, Zhenghe Hospital; Xi'an-China

## ABSTRACT

**Objective:** Although imaging modalities, such as transesophageal and intracardiac echocardiography, have helped to improve the safety of atrial transseptal puncture (TSP), fluoroscopy is still traditionally and widely used in TSP. The aim of the present study was to evaluate an individual knack for TSP during cryoballoon ablation of atrial fibrillation (AF) under fluoroscopy.

**Methods:** Through the prospective study of 72 cases of patients with paroxysmal or persistent AF admitted for cryoablation in our center, 46 cases using a puncture site toward the bifurcation of the left main bronchus (LMB group) and 26 cases using an anterior–inferior puncture site (AI group) were included in the study. The acute pulmonary vein (PV) isolation success rate, single-procedure success rate, and time-to-effect (TTE) between the two groups were analyzed.

**Results:** All PVs were identified and successfully isolated, and there are no differences in the two groups. However, the mean TTE was shorter in the LMB group than in the AI group. Moreover, a higher single-procedure success rate was observed in the LMB group.

**Conclusion:** The bifurcation of the LMB can be clearly evaluated in each patient under fluoroscopy and is an anatomical landmark for the location of the left PV. TSP guided by the LMB is a new practical method for choosing individualized transseptal sites for catheter ablation of AF, which can help to shorten TTE and procedure time. (*Anatol J Cardiol* 2019; 21: 150-4)

**Keywords:** left main bronchus, transseptal puncture, cryoballoon ablation, atrial fibrillation, fluoroscopy

## Introduction

Circumferential pulmonary vein isolation (PVI), achieved by cryoballoon ablation or radiofrequency ablation, is an established strategy for paroxysmal and persistent atrial fibrillation (AF) ablation (1, 2). Each ablation technology has its own advantages and disadvantages (3). However, a growing body of research indicates that patients treated with second-generation cryoballoon system had significantly fewer reablations, readmissions, and cardioversions due to receiving a better durable, contiguous and transmural lesion surrounding the pulmonary vein antrum (4).

Transseptal puncture (TSP) is routinely performed during AF ablation and impacts on outcomes of ablation (5).

Currently, an anterior and inferior transseptal access is thought to be beneficial in cryoballoon ablation, especially for isolating the inferior pulmonary veins (PVs) (6, 7). However,

more anterior and inferior access does not always provide good support and not facilitate to form a good coaxial angle when ablating the right inferior PV (RIPV) or left pulmonary vein, especially in the enlarged left atrium.

With the aim to explore an ideal puncture site, we primarily noticed that the left superior pulmonary vein (LSPV) ostium is right below the bifurcation of the left main bronchus (LMB) at 30° or 45° right anterior oblique (RAO) by pulmonary vein angiography in each heart no matter how big the heart is. Therefore, we developed this modified method that uses the bifurcation of the LMB as an anatomical landmark to accomplishing TSP under fluoroscopy, and we proposed the hypothesis that this puncture site pointing to the bifurcation of the LMB allows the ideal approach angles and support for four PV ablations compared with angles from the anterior–inferior transseptal approach.

In the present study, we compared two alternate TSP sites and evaluated the acute success rate (elimination of electrical poten-

**Address for correspondence:** Hexiang Cheng, MD, Department of Cardiology, Xijing Hospital, Fourth Military Medical University (Air Force Medical University), 710032, Xi'an-China

Phone: +86 2984775183 Fax: +86 2984771170 E-mail: chyx70@163.com

**Accepted Date:** 27.11.2018 **Available Online Date:** 31.01.2019

©Copyright 2019 by Turkish Society of Cardiology - Available online at [www.anatoljcardiol.com](http://www.anatoljcardiol.com)  
DOI:10.14744/AnatolJCardiol.2018.08566



tials between the pulmonary veins and the left atrium), single-procedure success rate, and time-to-effect (TTE) guided by this modified method. We attempted to determine which approach was more ideal and individualized during cryoballoon ablation.

## Methods

### Patient population

A total of 72 consecutive patients who underwent PVI by cryoballoon ablation for symptomatic drug refractory AF (paroxysmal or persistent) were enrolled at a single specialized cardiac care center. The patients were divided into two groups randomly. The anterior and inferior TSP was performed in 26 patients (AI group). TSP toward the bifurcation of the LMB was performed in 46 patients (LMB group). The study protocol was approved by the local Institutional Review Board. Informed consent was obtained from all patients involved in the study.

### Transeptal procedure

The puncture was performed under fluoroscopy. The whole assembly (Brockenbrough needle, SL1 sheath; St. Jude Medical) was withdrawn into the fossa ovalis after a second subtle movement in both groups. Thereafter, in the LMB group, the tip of the assembly was rotated clockwise until the right pointing bifurcation of the LMB at 45° RAO and then punctured across the septum. However, in the AI group, an anterior and inferior transeptal access was performed, which is near the posterior and superior edge of the coronary sinus ostium. Immediately after TSP, administration of heparin bolus (100 U/kg) was followed by supplemental doses of heparin throughout the procedure with the goal of maintaining active clotting time at least in excess of 300 s.

### Cryoablation

Following a single TSP, an achieve mapping catheter and a 28 mm second-generation cryoballoon (CB-2, Arctic Front Advance; Medtronic, Inc.) were positioned within the left atrium. The sequence of cryoablation is as follows: LSPV, left inferior PV (LIPV), RIPV, and right superior PV (RSPV). The endpoint of the ablation was PVI.

### Statistical analysis

Data are presented as mean±standard error of the mean. The difference of processing time among two groups was analyzed by using Student's t test and SPSS 13.0 (SPSS Inc., Chicago, IL, USA). A p value <0.05 was considered statistically significant.

## Results

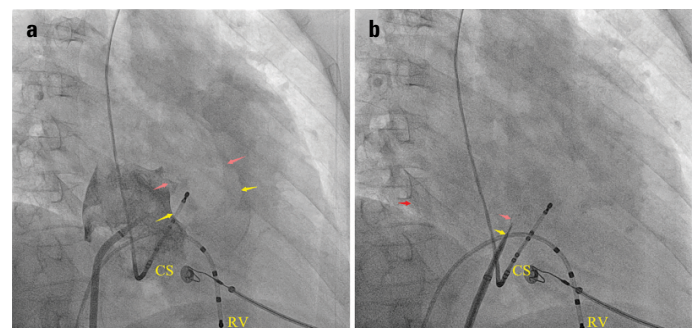
LMB and its bifurcation, left upper lobe bronchus, and left lower lobe bronchus can be very easily identified in every patient in fluoroscopic 45° RAO projection. Sixty-one patients were treated with antral circumferential PVI using CB-2 tech-

nology. There were no significant differences in the baseline clinical characteristics in two groups (Table 1). All transeptal sites reached the target (Fig. 1, 2). A total of PVs (100%) were identified and successfully isolated in both groups. There were no significant differences in puncture time in two groups. Cryoablation utilizing transeptal access in the LMB group (Fig. 3) resulted in an improvement in TTE compared with the AI group (LSPV: 41±13 s vs. 51±19 s, LIPV: 40±12 s vs. 56±22 s, RSPV: 46±19 s vs. 51±18 s, RIPV: 44±18 s vs. 56±25 s, p<0.001) and higher single-procedure success rate (LSPV: 88% vs. 65%, LIPV: 91% vs. 46%, RSPV: 82% vs. 61%, RIPV: 66% vs. 38%, p<0.001). Moreover, the direction of the puncture toward the bifurcation of the LMB usually faced the ostium of the left pulmonary vein. The 15F steerable sheath (FlexCath™; Medtronic) provided better support and coaxial alignment during ablation

**Table 1. Baseline characteristics of the subjects**

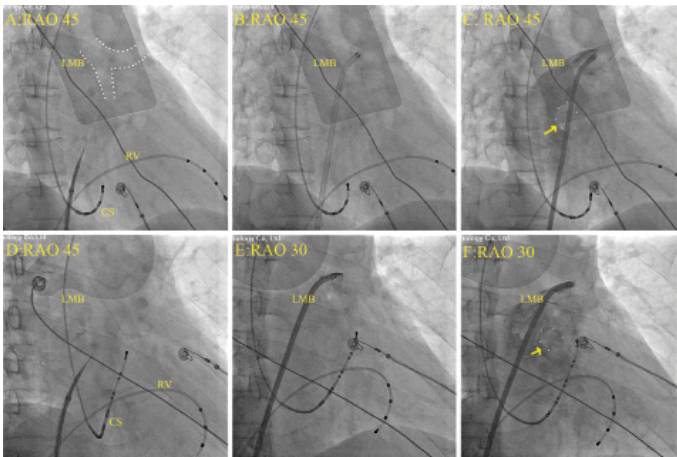
| Variable                       | LMB group<br>(n=46) | AI group<br>(n=26) | P value |
|--------------------------------|---------------------|--------------------|---------|
| Age                            | 60±10               | 56±6               | NS      |
| Gender (%)                     |                     |                    |         |
| Female                         | 17 (37)             | 10 (40)            | NS      |
| Male                           | 29 (63)             | 16 (60)            | NS      |
| Paroxysmal atrial fibrillation | 40 (87)             | 21 (81)            | NS      |
| Persistent atrial fibrillation | 6 (13)              | 5 (19)             | NS      |
| Left atrial diameter (mm)      | 37.4±6.2            | 39.2±4.7           | NS      |
| Right atrial diameter (mm)     | 35.1±4.9            | 35.4±2.7           | NS      |
| Ejection fraction              | 51.7±5.9            | 50.1±3.4           | NS      |

Values are presented as mean±standard deviation or n (%).  
 LMB - left main bronchus; AI - anterior and inferior



**Figure 1.** Previous fluoroscopic image identified the imaging features of the anterior–inferior puncture sites by right atrial angiography at 45° RAO. (a) Showing the outline of the aorta root (white area of medium-free marked by pink arrow), non-coronary cusp, and left-coronary cusp (yellow arrow). (b) Showing the puncture site (yellow arrow), contrast medium injected into the left atria (pink arrow), and posterior edge of the left atria (red arrow). The puncture site was rotated in the forward direction, often close to CS catheter but not beyond its bottom at 45° RAO. Moreover, this site was below the top of the RV catheter above 1.5 cm at the bottom of the CS catheter.

CS - coronary sinus catheter; RV - right ventricle catheter



**Figure 2.** Fluoroscopic views during TSP and left atrial angiography in two patients. (a, d) Direction of the Brockenbrough needle point to the bifurcation of the LMB. (b, e) SL1 sheath was placed in the LSPV, image of LSPV overlapped bifurcation. (c, f) Angiography of the left atrium. Image of distal LSPV overlapped left upper lobe bronchus, they went into the hilum together in parallel. Whirlpool of contrast medium (yellow arrows) showed the LIPV ostium posterior to the distal left lower lobe bronchus and right below the LIPV ostium. These spatial relationships were more standard at 45° RAO. LMB, left main bronchus. CS - coronary sinus catheter; RV - right ventricle catheter

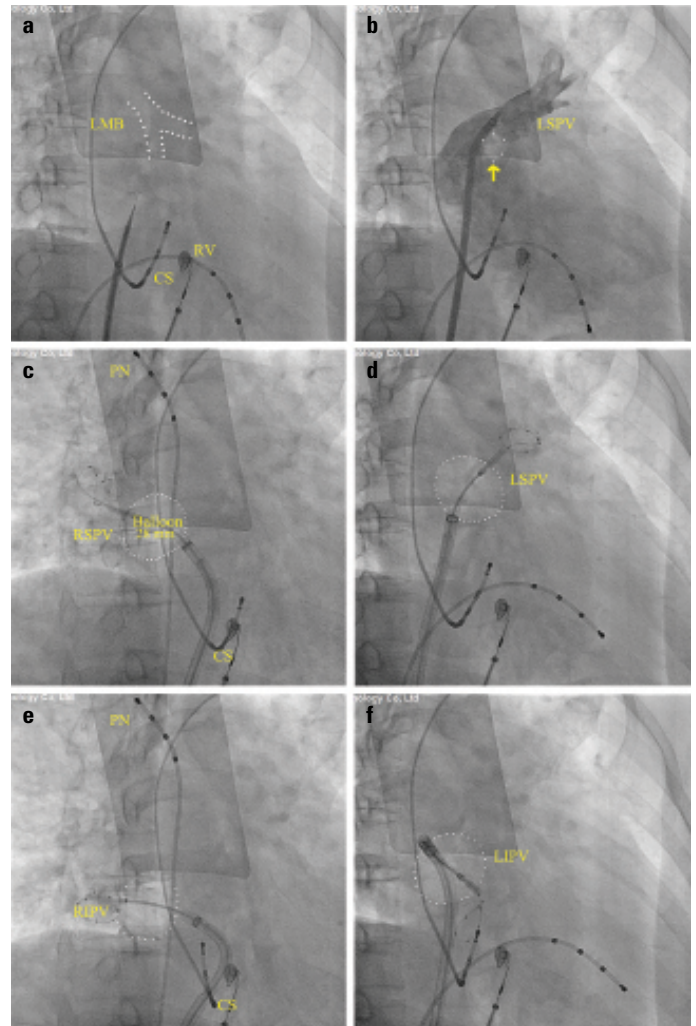
through this puncture site. In addition, this transeptal site still allowed enough maneuvering space for the apparatus.

The advantage of the puncture site in the LMB group was more obvious when the LIPV was positioned more anterior (Fig. 4). Moreover, there are several features in the location relationship between the LIPV ostium and the bronchus in RAO view (Fig. 5). Each group had one case of phrenic nerve injury during ablation, but they recovered within 1 month. No iatrogenic complications occurred in both groups.

## Discussion

PVI is an effective treatment in patients with symptomatic AF refractory or intolerant to antiarrhythmic medications (8). The second-generation cryoballoon is increasingly used for the treatment of AF. Knowing the exact anatomy of the left atrium and PVs before the operation is important for improving the success rate and avoiding the complication (9, 10).

The atrium plays a pivotal role in electromechanical, mechanical, and endocrine regulation of the heart. Moreover, the left atrium has multiple anatomical shape variations (11, 12). The morphology of the left atrium, PVs, and ostia of PVs, as well as the left atrial appendage, could be displayed clearly on a 64-slice spiral computed tomography with multiple reconstruction techniques and transesophageal echocardiography (TEE) or intracardiac echocardiography, which can help to locate the transeptal site (6, 7, 13). However, fluoroscopy is still traditionally and widely used in many arrhythmia centers. Fluoroscopic image can provide very important information about the left atrium and

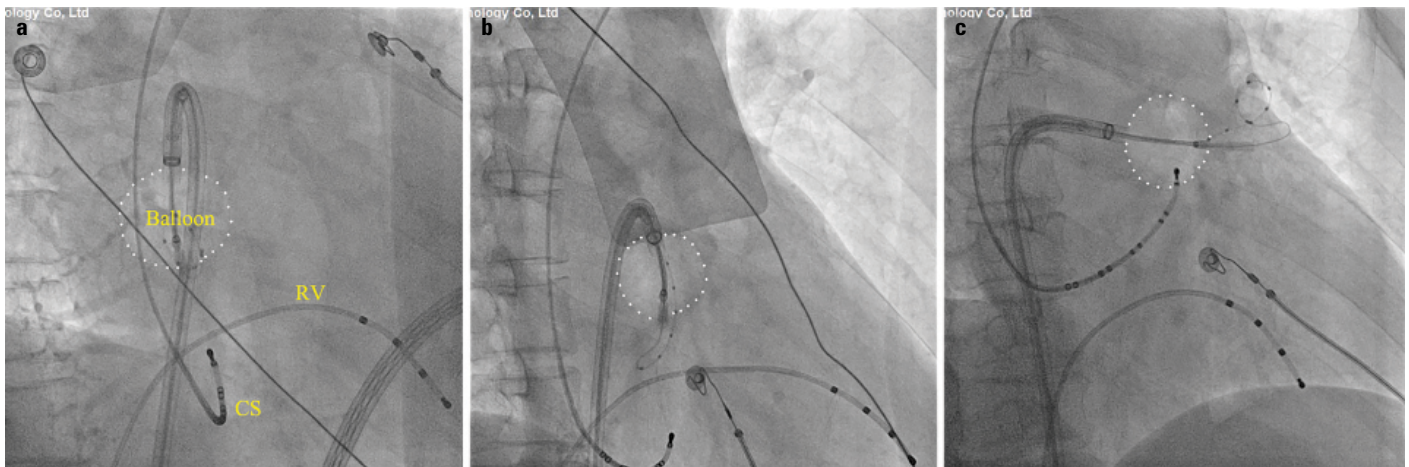


**Figure 3.** Fluoroscopic views at 45° RAO. (a) Puncture site toward the bifurcation of the LMB. (b) Angiography showing the LSPV antrum near the bifurcation and the LIPV ostium posterior to the distal end of the left lower lobe bronchus (yellow arrows). (c-f) Cryoballoon occlusion of RSPV, LSPV, RIPV, and LIPV. This puncture site could balance all approach angles of all four PVs.

PN - phrenic nerve catheter; LMB - left main bronchus; CS - coronary sinus catheter; RV - right ventricle catheter

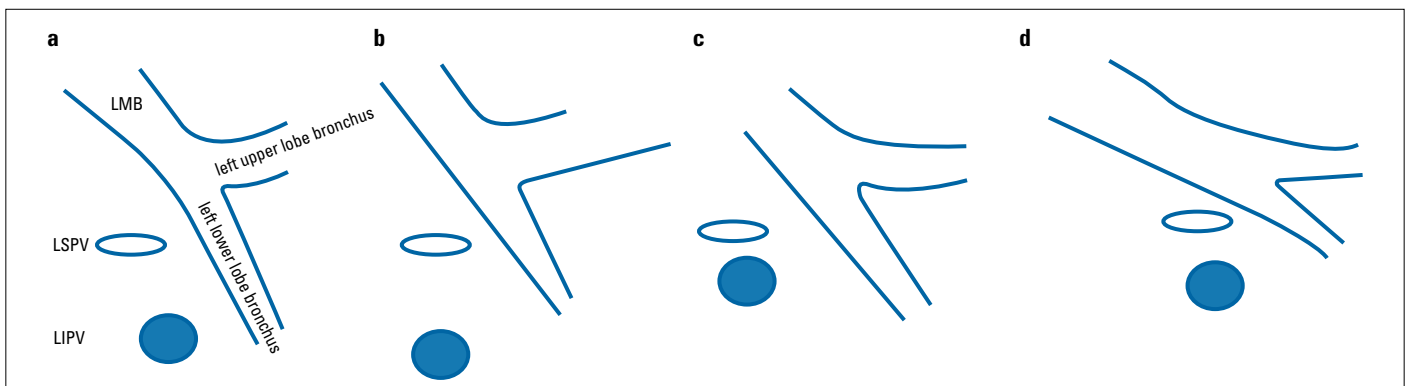
PVs, which would help to design an individualized transeptal site for each heart (14-16).

It is generally known that the top of the right atria is the bottom of the aorta root and non-coronary cusps located anterior-superior to the intra-atrial septum (17, 18), and the coronary sinus was  $9.3 \pm 5.3$  mm in diameter (19). Therefore, in the AI group, the puncture site was around midpoint between the top of the RV catheter and the bottom of the CS catheter, but not beyond the bottom of the CS catheter at 45° RAO. It should be noted that the bottom of the CS catheter represents the bottom of the left atrium instead of the bottom of the CS ostium (20). However, this kind of puncture site is at the forefront of the left atrium, especially when the coronary sinus is very close to the mitral annulus, or the atrium was dilated. According to the anatomical relationship, the LIPV ostium often tends to be



**Figure 4.** Showing the LIPV representative cryoballoon engagement angle by using the transeptal site toward the bifurcation of the LMB at 45° RAO in three patients. Pictures A and B were the two most common ways with natural curve. Picture C was relatively rare while the LIPV ostium was directed backward due to an anterior hilum and narrow angle between the LIPV and the left atrium, which was not convenient to operate with an anterior transeptal site in such a situation.

CS - coronary sinus catheter; RV - right ventricle catheter



**Figure 5.** Diagram illustrating the anatomy relationships between the LIPV ostium and the bronchus in RAO view. Left lower lobe bronchus commonly tends downwards (a-c) or horizontally forward (d). The LSPV ostium is regularly inferior-posterior to the bifurcation of the LMB (a-d). Hence, the bifurcation of the LMB is an accurate anatomical landmark for the location of the LSPV ostium under fluoroscopy. Although a width of ridge between the LSPV and the LIPV is variant, the LIPV ostium is right inferior or infra-anterior to the LSPV ostium generally. Therefore, the bifurcation of the LMB actually can help to identify precisely where the LIPV antrum is. Moreover, the LIPV ostium is posterior to the distal end of the left lower lobe bronchus usually (a, d), or inferior-posterior to it occasionally (b), or posterior to the middle part of it rarely (c). Therefore, the more left lower lobe bronchus comes out vertical downward, the more ostium of the LSPV and LIPV is in a straight line. The bifurcation of the LMB and the bifurcation of the left pulmonary vein are supposed to be near the same coronal plane

along the same vertical line with the LSPV ostium instead of always being anterior to the LSPV at RAO. Therefore, the anterior-inferior puncture site and LIPV do not lie in the same plane, which impairs coaxiality, especially for the LIPV. Moreover, the anterior-inferior puncture site is further away from the RIPV. Therefore, those are possible reasons for increasing the difficulty of inferior PV occlusion.

An optimal puncture site might have regard to cryoballoon engagement angle of all PVs. Based on this idea, we developed this modified TSP method by using the bifurcation of the LMB as a guide. We know that the LMB divides into the left upper lobe bronchus and the left lower lobe bronchus. LSPV drains the left upper lobe and runs parallel with the upper lobe bronchus. Fluoroscopic imaging at RAO is characterized as follows: (1) the LSPV tends to overlap with the left upper lobe bronchus, and the LSPV ostium

tends to be on the extended line of the left upper lobe bronchus or be frequently posterior-inferior to the bifurcation of the LMB; (2) the distal portion of the LIPV and left lower lobe bronchus usually merges together; and (3) the LIPV ostium often tends to be along the same vertical line with the LSPV ostium, but anterior to the LSPV occasionally. Hence, the left upper lobe bronchus and left lower lobe bronchus are important anatomical reference markers for the location of the LIPV antrum under fluoroscopy no matter how PVs or bronchus varies. Therefore, a benefit of the puncture site toward the bifurcation of the bronchus is that the sheath can be aligned with the angle of the LIPV naturally and smoothly, which can help to improve single-procedure success rate.

Even though the LIPV ostium rarely directs backward due to a more anterior hilum and narrow angle between the LIPV and the left atrium, the sheath could still be flexibly turned to the

posterior wall of the left atrium by using the puncture site we recommended (Fig. 5c). Far from being difficult for isolating the RIPV utilizing this site we recommend, there is enough space for maneuvering the sheath and balloon. The single-procedure success rate of the RIPV was also high with this transseptal access.

### Study limitation

Later, we have successfully practiced this method in patients with aortic sinus aneurysm in our daily routines. However, all patients in the present study had no thoracic deformity or shift in the mediastinum. This is our limitation. However, we believe that this individual knack is still instructive for these abnormal persons because the left upper lobe bronchus, LSPV, and left hilum have a fixed anatomical relationship. LMB with its two lobar bronchi (left upper and lower lobar bronchi) is also fibrocartilaginous tube, supported by incomplete cartilaginous tracheal rings. This integral structure can be easily seen even with low radiation dose at 45° RAO. The left upper lobe bronchus arises from the superolateral wall of the LMB to traverse the left hilum into the left upper lobe in parallel with the LSPV so is the left lower lobe bronchus. Therefore, the bifurcation of the LMB and the bifurcation of the left pulmonary vein are supposed to be near the same coronal plane.

### Conclusion

The puncture technique we presented is safe, simple, and effective and makes the process more smooth and easy. Actually, this knack is suitable for both cryoballoon and radiofrequency ablation.

**Funding:** This work was supported by the National Natural Science Foundation of China (81703407, 31370996).

**Conflict of interest:** None declared.

**Peer-review:** Internally and externally peer-reviewed.

**Authorship contributions:** Concept – Y.Y., L.T., H.C.; Design – Y.Y., L.T., H.C.; Fundings – Y.Y.; Data collection &/or processing – Y.Y., M.Z., W.Y.; Analysis &/or interpretation – M.Z., W.Y.; Literature search – M.Z., W.Y.; Writing – Y.Y.; Critical review – Y.Y., L.T., H.C.

### References

- Haïssaguerre M, Jaïs P, Shah DC, Takahashi A, Hocini M, Quiniou G, et al. Spontaneous initiation of atrial fibrillation by ectopic beats originating in the pulmonary veins. *N Engl J Med* 1998; 339: 659-66.
- Calkins H, Hindricks G, Cappato R, Kim YH, Saad EB, Aguinaga L, et al. 2017 HRS/EHRA/ECAS/APHRS/SOLAECE expert consensus statement on catheter and surgical ablation of atrial fibrillation. *Heart Rhythm* 2017; 14: e275-e444. [CrossRef]
- Kuck KH, Brugada J, Fünkrantz A, Metzner A, Ouyang F, Chun KR, et al.; FIRE AND ICE Investigators. Cryoballoon or Radiofrequency Ablation for Paroxysmal Atrial Fibrillation. *N Engl J Med* 2016; 374: 2235-45.
- Kuck KH, Fünkrantz A, Chun KR, Metzner A, Ouyang F, Schlüter M, et al.; FIRE AND ICE Investigators. Cryoballoon or radiofrequency ablation for symptomatic paroxysmal atrial fibrillation: reintervention, rehospitalization, and quality-of-life outcomes in the FIRE AND ICE trial. *Eur Heart J* 2016; 37: 2858-65. [CrossRef]
- Chierchia GB, Casado-Arroyo R, de Asmundis C, Rodriguez-Manero M, Sarkozy A, Conte G, et al. Impact of transseptal puncture site on acute and mid-term outcomes during cryoballoon ablation: a comparison between anterior, medial and posterior transatrial access. *Int J Cardiol* 2013; 168: 4098-102. [CrossRef]
- Su W, Kowal R, Kowalski M, Metzner A, Svinarich JT, Wheelan K, et al. Best practice guide for cryoballoon ablation in atrial fibrillation: The compilation experience of more than 3000 procedures. *Heart Rhythm* 2015; 12: 1658-66. [CrossRef]
- Rich ME, Tseng A, Lim HW, Wang PJ, Su WW. Reduction of Iatrogenic Atrial Septal Defects with an Anterior and Inferior Transseptal Puncture Site when Operating the Cryoballoon Ablation Catheter. *J Vis Exp* 2015; 100: e52811. [CrossRef]
- Tang M, Kriatselis C, Nedios S, Ye G, Roser M, Fleck E, et al. A novel cryoballoon technique for mapping and isolating pulmonary veins: a feasibility and efficacy study. *J Cardiovasc Electrophysiol* 2010; 21: 626-31. [CrossRef]
- Ho SY, Sanchez-Quintana D, Cabrera JA, Anderson RH. Anatomy of the left atrium: implications for radiofrequency ablation of atrial fibrillation. *J Cardiovasc Electrophysiol* 1999; 10: 1525-33.
- Ciuk S, Janas P, Klimek-Piotrowska W. Clinical anatomy of human heart atria and interatrial septum - anatomical basis for interventional cardiologists and electrocardiologists. Part 2: left atrium. *Kardiol Pol* 2018; 76: 510-9.
- Cates J, Biegging E, Morris A, Gardner G, Akoum N, Kholmovski E, et al. Computational Shape Models Characterize Shape Change of the Left Atrium in Atrial Fibrillation. *Clin Med Insights Cardiol* 2015; 8(Suppl 1): 99-109.
- Balli O, Aytimir K, Karcaaltincaba M. Multidetector CT of left atrium. *Eur J Radiol* 2012; 81: e37-46. [CrossRef]
- Erden İ, Erden EÇ, Golcuk E, Aksu T, Yalin K, Güler TE, et al. Impact of transesophageal echocardiography during transseptal puncture on atrial fibrillation ablation. *J Arrhythm* 2016; 32: 170-5.
- Koektuerk B, Yorgun H, Koektuerk O, Turan CH, Gorr E, Horlitz M, et al. Rotational Angiography Based Three-Dimensional Left Atrial Reconstruction: A New Approach for Transseptal Puncture. *Cardiovasc Ther* 2016; 34: 49-56. [CrossRef]
- Afzal S, Veulemans V, Balzer J, Rassaf T, Hellhammer K, Polzin A et al. Safety and efficacy of transseptal puncture guided by real-time fusion of echocardiography and fluoroscopy. *Neth Heart J* 2017; 25: 131-6. [CrossRef]
- Bourier F, Reents T, Ammar-Busch S, Semmler V, Telishevska M, Kottmaier M, et al. Transseptal Puncture Guided by CT-Derived 3D-Augmented Fluoroscopy. *J Cardiovasc Electrophysiol* 2016; 27: 369-72.
- Collins JA, Munoz JV, Patel TR, Loukas M, Tubbs RS. The anatomy of the aging aorta. *Clin Anat* 2014; 27: 463-6. [CrossRef]
- Murillo H, Lane MJ, Punn R, Fleischmann D, Restrepo CS. Imaging of the aorta: embryology and anatomy. *Semin Ultrasound CT MR* 2012; 33: 169-90. [CrossRef]
- El-Maasarany S, Ferrett CG, Firth A, Sheppard M, Henein MY. The coronary sinus conduit function: anatomical study (relationship to adjacent structures). *Europace* 2005; 7: 475-81. [CrossRef]
- Habib A, Lachman N, Christensen KN, Asirvatham SJ. The anatomy of the coronary sinus venous system for the cardiac electrophysiologist. *Europace* 2009; 11 (Suppl 5): v15-21. [CrossRef]