

**A mass compressing the left atrium**

P. 95

**Right Answer:** 3. Bronchogenic cyst

Pathologic examination of surgical pieces revealed a cystic lesion lined by ciliated pseudo-stratified columnar epithelium. He was diagnosed with bronchogenic cyst. His symptoms were relieved immediately after operation. Postoperative transthoracic echocardiography parasternal long axis (3A) and apical four-chamber views (3B) showed no cystic lesion.

Bronchogenic cysts are rare congenital anomalies that are typically found in the mediastinum or lung parenchyma. They are the most common primary cysts of the mediastinum that originated from the primitive foregut. The most common location of bronchogenic cysts in mediastinum includes hilar, para-tracheal, sub-carina, paraesophagus and pericardium (1, 2). Bronchogenic cysts were also seen in sub-diaphragmatic, intra-pericardium, supraclavicular spaces and retro-peritoneal. Patients with bronchogenic cysts may have different symptoms according to the lesions' size, location and communication. The most common of them are dysphagia, shortness of breath and chest pain (3). Differential diagnoses should include a duplication cyst, esophageal leiomyoma and lymphadenopathy.

Preoperative echocardiography and tomography showed a cystic mass. Broncho-pulmonary foregut malformations cause cystic mass lesions in the chest cavity. The two most common types are bronchogenic cyst and esophageal duplication cyst. Esophageal duplication cysts are usually localized around the right posterior-inferior mediastinum whereas bronchogenic cysts are localized around the tracheobronchial tree.

Leiomyomas are the most common benign tumor of the esophagus and present as a homogeneous and hypo-echoic lesion with clear margins surrounded by a hyper-echoic area which can be easily differentiated from cystic lesion. Therefore, preoperative radiologic findings suggested bronchogenic cyst.

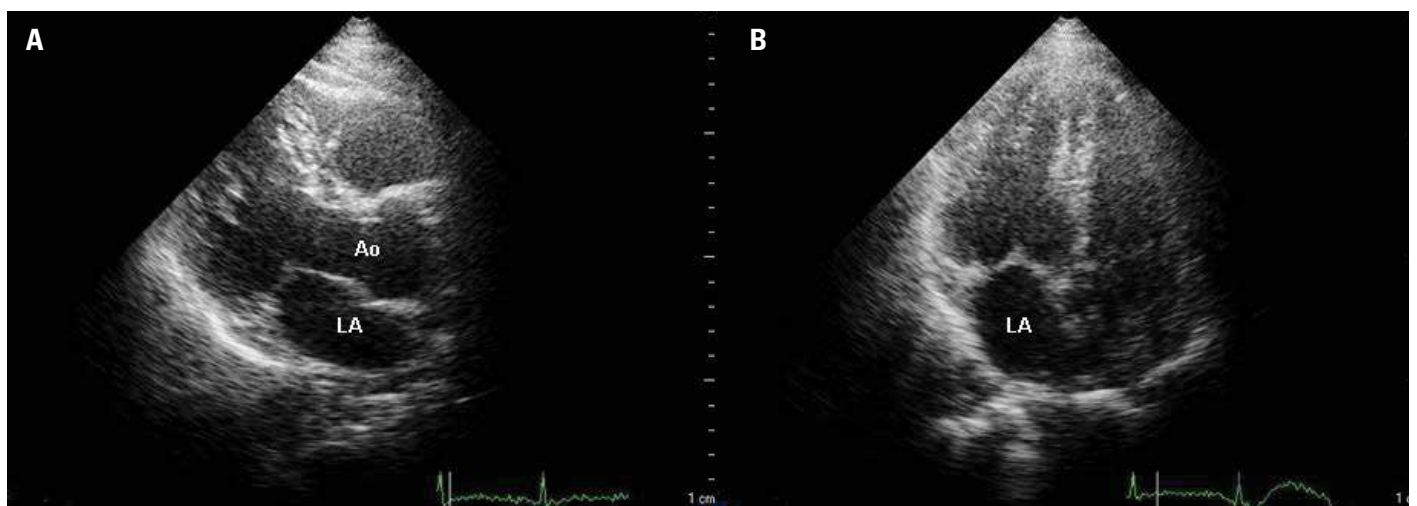
All suspected bronchogenic cysts were recommended to be removed surgically. Because complete surgical resection would help to establish diagnosis, alleviate symptoms, and prevent complications. Therefore, we decided to perform surgical resection for our case.

**Sait Demirkol, Samed Samedli, Şevket Balta, Uğur Bozlar\***  
Departments of Cardiology and \*Radiology, Faculty of Medicine, Gülhane Military Medical Academy; Ankara-Turkey

**Video 1.** Two-dimensional transthoracic echocardiography parasternal long-axis (A) and apical four-chamber views (B) showed a thin-walled hypoechoic mass compressing the left atrium

**References**

1. St-Georges R, Deslauriers J, Duranceau A, Vaillancourt R, Deschamps C, Beauchamp G, et al. Clinical spectrum of bronchogenic cysts of the mediastinum and lung in the adult. *Ann Thorac Surg* 1991; 52: 6-13. [\[CrossRef\]](#)
2. Limaïem F, Ayadi-Kaddour A, Djilani H, Kilani T, El Mezni F. Pulmonary and mediastinal bronchogenic cysts: a clinicopathologic study of 33 cases. *Lung* 2008; 186: 55-61. [\[CrossRef\]](#)
3. Özpolat B, Doğan OV. Absence of pericardium in combination with bronchogenic cyst, atrial septal defect, mitral valve prolapsus and hypospadias. *Anadolu Kardiyol Derg* 2009; 9: E16-7.



**Figure 3.** Postoperative two-dimensional transthoracic echocardiography parasternal long axis (A) and apical four-chamber views (B) showed no cystic lesion