

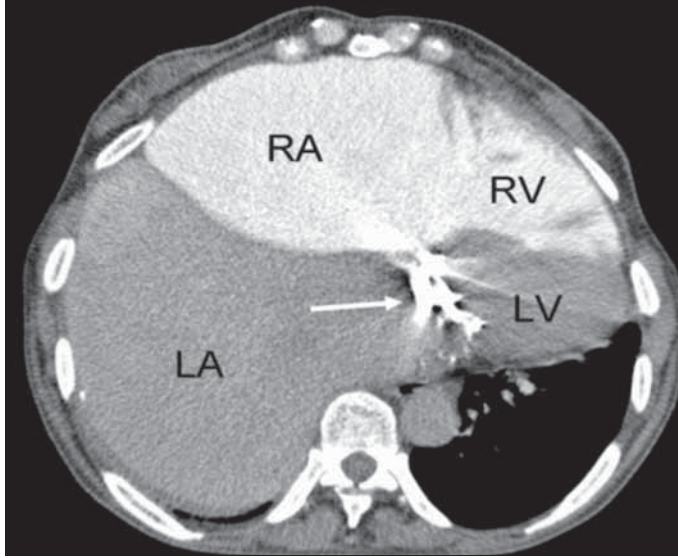Figure 2. Axial contrast-enhanced CT image shows extreme biatrial dilatation with right ventricular dilatation. Right hemithorax is filled with dilated atrial chambers. Right lung is atelectatic. Prosthetic mitral valve is also seen (arrow)

CT - computed tomography, LA - left atrium, LV - left ventricle, RA - right atrium, RV - right ventricle

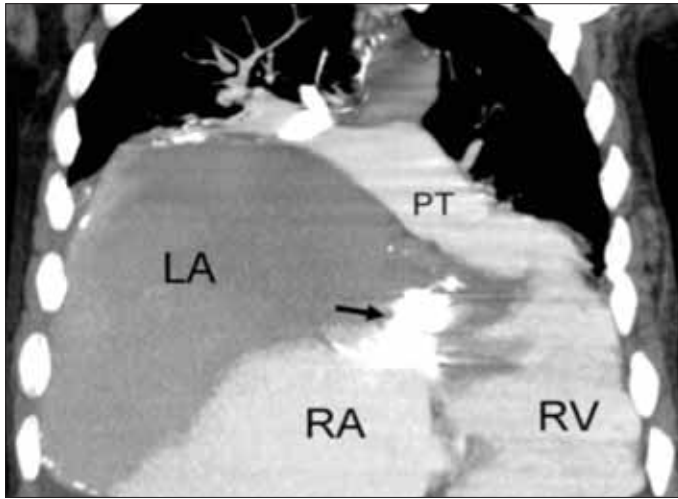


Figure 3. Coronal MIP (maximum intensity projection) reformatted CT image demonstrates striking biatrial dilatation with right ventricular enlargement. Right hemithorax is filled with dilated atrial chambers. Pulmonary truncus dilated due to pulmonary hypertension. Mitral valve prosthesis is also seen (arrow)

CT - computed tomography

**Naim Ceylan, Selen Bayraktaroğlu, Sanem Nalbantgil*,
Recep Savaş, Hüdaver Alper**
From Departments of Radiology and *Cardiology, Faculty of
Medicine, Ege University, İzmir, Turkey

Address for Correspondence/Yazışma Adresi: Dr. Naim Ceylan,
Department of Radiological, Faculty of Medicine, Ege University, İzmir, Turkey
Phone: +90 232 390 22 25 Fax: +90 232 342 00 01
E-mail: ceylanaim@gmail.com

Available Online Date/Çevrimiçi Yayın Tarihi: 11.01.2011

© Telif Hakkı 2011 AVES Yayıncılık Ltd. Şti. - Makale metnine www.anakarder.com web sayfasından ulaşılabilir.

© Copyright 2011 by AVES Yayıncılık Ltd. - Available on-line at www.anakarder.com
doi:10.5152/akd.2011.020

Aortic pseudoaneurysm mimicking intraatrial mass 🎬

İntraatriyal kitleyi taklit eden aortik psödoanevrizma

A 34-year-old female presented to the emergency department with dyspnea, chest pain and recurrent fever. Her initial vital signs revealed a high fever up to 38.9°C, blood pressure of 100/74 mmHg, heart rate of 107 beats/min, and tachypnea of 28/min. She had history of tooth extraction 30 days ago and advanced tooth abscess after extraction. The transthoracic echocardiography, performed with suspicion of infective endocarditis, revealed an intraatrial mobile mass (vegetation and thrombus) (Fig. 1, Video 1. See corresponding video/movie images at www.anakarder.com). The transesophageal echocardiography showed mitral-aortic intervalvular abscess having septas and blood flow in it (Fig. 2, 3, Video 2-4. See corresponding video/movie images at www.anakarder.com). We empirically started broad spectrum antibiotics,

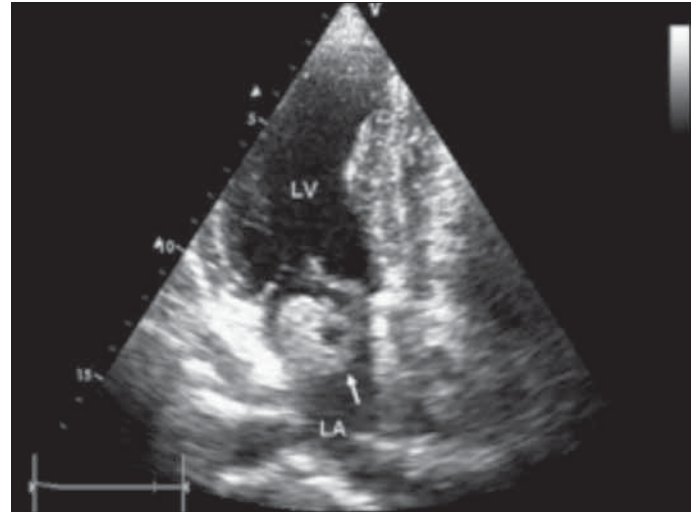


Figure 1. Transthoracic echocardiography view demonstrating an intraatrial mobile mass (arrows)

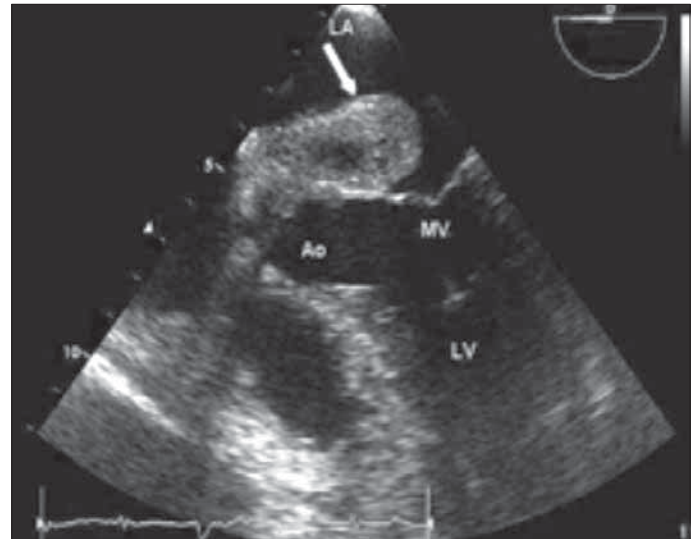


Figure 2. Transesophageal echocardiography view showing mitral-aortic intervalvular abscess (arrows) and blood flow in it

penicillin G in combination with gentamycin. Blood cultures tested positive with *Staphylococcus aureus*. Because of the uncertain diagnosis, we planned computerized tomography (CT) of the chest. Computerized tomography revealed a pseudoaneurysm of the ascending aorta (Fig. 4). The patient underwent emergency aortic surgery. Although, intensive management and antimicrobial therapy was given, she developed multiple organ failure and died in the postoperative period. The present case demonstrates a mycotic aortic aneurysm, which is a rarely considered but serious complication of bacterial endocarditis. Mycotic aneurysm is an infrequent complication of arterial infection. Infected aortic aneurysm occurs about 0.7%-2.6% of all aortic aneurysms. Awareness and recognition of imaging features

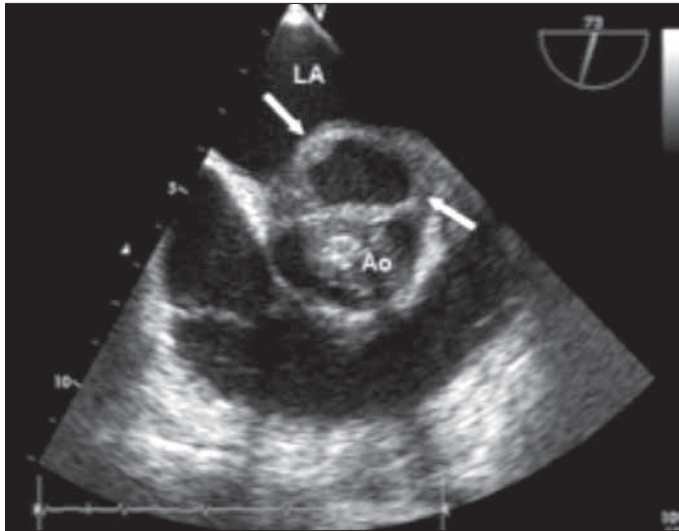


Figure 3. Transesophageal echocardiography view showing mitral-aortic intervalvular abscess (arrows) and blood flow in it

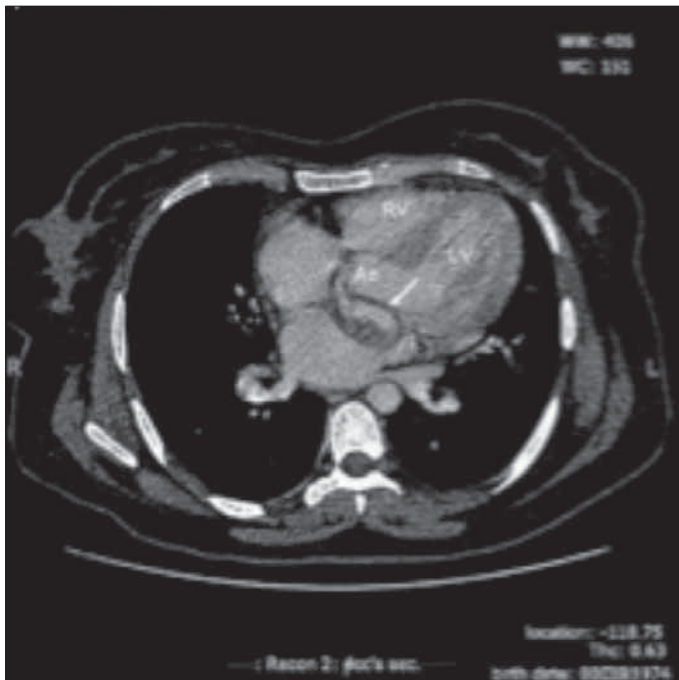


Figure 4. An axial computed tomography image demonstrates a pseudoaneurysm extending from the aorta to the left ventricle measuring 3cm (arrow). A thrombus is surrounding the lesion

associated with infected aneurysms are all important for early diagnosis and institution of adequate therapy. Infected aneurysms are likely to rupture, with reported rupture rates of 53% to 75%. Urgent surgical intervention followed by long-term antibiotic therapy is the preferred treatment approach.

İdris Ardıç, Mehmet Güngör Kaya, Bahadır Şarlı, Ertuğrul Mavili*, İbrahim Özdoğru
Departments of Cardiology and *Radiology, Erciyes University, Faculty of Medicine, Kayseri, Turkey

Address for Correspondence/Yazışma Adresi: Dr. İdris Ardıç, Department of Cardiology, Erciyes University School of Medicine, 38039 Kayseri, Turkey
Phone: +90 352 437 49 37/27792 Fax: +90 352 437 34 08
E-mail: idrisardic@yahoo.com

Available Online Date/Çevrimiçi Yayın Tarihi: 11.01.2011

©Telif Hakkı 2011 AVES Yayıncılık Ltd. Şti. - Makale metnine www.anakarder.com web sayfasından ulaşılabilir.

©Copyright 2011 by AVES Yayıncılık Ltd. - Available on-line at www.anakarder.com
doi:10.5152/akd.2011.021

Two giant coronary artery aneurysms accompanying aortic aneurysms

Aort anevrizmalarına eşlik eden iki dev koroner arter anevrizması

A 72-year-old woman was admitted to our institution with the symptoms of back pain and fatigue. Ten years earlier, she had undergone open surgery for abdominal aortic aneurysm. Coronary angiography at that time had demonstrated mild aneurysmal dilatation of left anterior descending artery (LAD) (Fig. 1a) and right coronary artery (RCA) (Fig. 1b).

At her examination, thoracoabdominal computed tomography (CT) demonstrated one giant aneurysm of the descending thoracic aorta and fusiform aneurysmal dilatation of the abdominal aorta beginning from infrarenal segment through both common iliac arteries (Fig. 2). Furthermore, her CT images revealed two giant coronary artery aneurysms (CAA) at the proximal segments of LAD and RCA with maximum diameters of 6.9 and 6.6 cm, respectively (Fig. 3). Conventional angiography confirmed both of the CAA's (Video 1, 2. See corresponding video/movie images at www.anakarder.com). Since the anatomic loca-

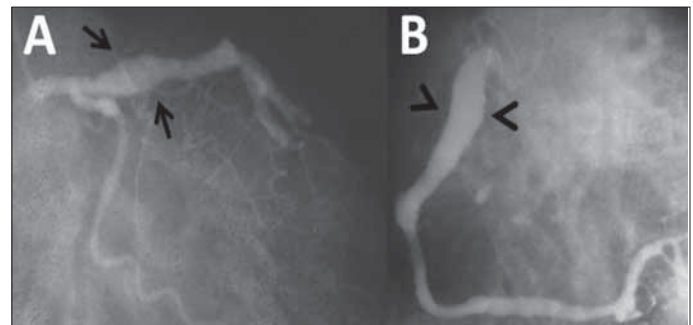


Figure 1. Coronary angiography view of aneurysmal dilatation of the LAD and RCA performed ten years earlier

LAD - left anterior descending artery, RCA - right coronary artery