



Research Article

Ankara Med J, 2020;(3):707-718 // doi 10.5505/amj.2020.98624

OUR SINGLE CENTER EXPERIENCE IN TREATING PATIENTS WITH MASSIVE HEMOPTYSIS MASİF HEMOPTİZİLİ HASTALARIN TEDAVİSİNDE TEK MERKEZ DENEYİMİMİZ

 Gokhan Yuce¹,  Serhan Eren¹

¹Ankara City Hospital, Interventional Radiology Department

Yazışma Adresi / Correspondence:
Gökhan Yüce (e-mail: drgkhann85@gmail.com)

Geliş Tarihi (Submitted): 17.07.2020 // Kabul Tarihi (Accepted): 24.08.2020



Öz

Amaç: Hemoptizi hayatı tehdit eden ve hızlı tanı konulup tedavi edilmesi gereken bir durumdur. Bizim bu çalışmadaki amacımız merkezimizin masif hemoptizi vakalarında uyguladığı süperselektif arteriyel embolizasyonun başarısını değerlendirmek, bu tür hastaların demografik ve klinik özelliklerini belirlemek, yapılan işlemin etkinliğini ve komplikasyonlarını belgelemektir.

Materyal ve Metot: Çalışmaya, merkezimizin acil servis veya göğüs hastalıkları bölümüne hemoptizi ile başvuran ve endovasküler tedavi yapılmış olan 72 hasta dahil edilmiştir. Bu hastaların demografik, klinik ve radyolojik verileri retrospektif olarak analiz edilmiştir

Bulgular: Hastaların ortanca yaşı 55'ti (min-maks; 22-78). Hastaların 25'i (%34,70) kadın 47'si erkekti (%65.30). Hastalardan 16'sının işlem öncesi tanısı akciğer kanseri, 7'sinin alveolar hemoraji, 1'nin malign melanoma bağlı akciğer metastazı, 2'nin histopatolojisi belirsiz hiler ve mediastinal kitle, 4'nün tüberküloz, 4'nün pulmoner tromboemboli, 1'nin sarkoidoz, 2'nin pnömoni, 1'nin siroza bağlı hepatopulmoner sendrom ve 34'ninki bronşiektaziydi. Embolize edilen damar 32 vakada sağ bronşiyal arter, 9 vakada sol bronşiyal arter, 15 vakada bilateral bronşiyal arter, 10 vakada kostobronşiyal arter ve 6 vakada bronşiyal dışı arterdi. En sık saptanan üç anjiyografik görünüm vasküler hipertrofi, vasküler iregülerite ve kontrast madde akümüasyonu idi. Kısa vadeli klinik başarı oranı %100'dü. 12 vakada ilk bir ay içinde tekrar kanama izlendi. En sık görülen komplikasyon geçici göğüs ağrısıydı.

Sonuç: Deneyimli ellerde masif hemoptizin en iyi minimal invaziv tedavi yöntemi selektif arteriyel embolizasyondur. Çalışmamız bu yöntemin etkinliğini ve güvenilirliğini doğrulamıştır.

Anahtar Kelimeler: Masif hemoptizi, embolizasyon, anjiyografi.

Abstract

Objectives: Hemoptysis is a life-threatening condition and requires immediate diagnosis and treatment. Here in this study, our aim was to demonstrate our single-center experience of super-selective arterial embolization in cases of massive hemoptysis, to describe the demographic and clinical data of those patients, to evaluate the success rate of the intervention, and to document the complications.

Materials and Methods: In this study, a total of 72 patients admitted to our tertiary center's emergency service or chest diseases department and underwent endovascular treatment were enrolled. The demographic and clinical data were analyzed retrospectively.

Results: The median age was 55 years (min-max; 22-78). 25 patients (34.70%) were female whereas 47 (65.30%) were male. 16 patients were diagnosed with lung cancer (squamous cell / adeno cancer), 7 alveolar hemorrhages, 1 pulmonary metastasis of malign melanoma, 2 mediastinal and hilar mass of unknown origin, 4 tuberculosis, 4 pulmonary thromboembolism, 1 sarcoidosis, 2 pneumonia, 1 cirrhosis, and hepatopulmonary syndrome and 34 patients with bronchiectasis. The embolized vessel was right bronchial in 32 cases, left bronchial in 9, bilateral in 15, costo-bronchial trunk in 10, and non-bronchial in 6 patients. The most common angiographic pattern was vascular hypertrophy followed by vascular irregularity and blush. The immediate clinical success was 100%. Rebleeding occurred in 12 patients due to recanalization of the vessel. The most common complication was chest pain.

Conclusion: In experienced hands, arterial embolization is the most effective and minimally invasive procedure to treat massive and recurrent hemoptysis. This study confirms the efficacy and safety of the intervention.

Keywords: Massive hemoptysis, embolization, angiography.

Introduction

Hemoptysis which is defined as the expectoration of blood from the lower airways mostly occurs in adults. In most cases, it is self-limiting and resolves without any intervention. However, in less than 5% of the cases, it is life-threatening and requires immediate investigation for detecting the bleeding site and treatment.¹The definition of massive hemoptysis varies in the literature and there is no specific volume cutoff which is universally accepted. Mild hemoptysis is generally defined as less than 50-100 cc, moderate 100-300 cc and severe/massive or life-threatening as more than 300 cc per day.²However, the severity of bleeding cannot be evaluated with volume alone since the amount of blood that causes symptoms such as hypotension and tachycardia may vary between the patients. Moreover, even a small amount of blood can flood the airways in diseased lungs with a diminished reserve and cause asphyxia. In some studies bleeding that reduces Hb > 1 gr/dl or hematocrit > 5% or causing low saturation (SapO₂ < 60%) and hypotension (systolic blood pressure lower than 90 mmHg) is also considered as massive hemoptysis regardless of the amount of blood loss.³

Hemoptysis is caused by many different etiologies that are subclassified as parenchymal disease, airway, or vascular diseases. The source of the bleeding can be either small or large vessels. The small vessel hemorrhages usually result in alveolar hemorrhage due to immunologic, vasculitis, cardiovascular, or coagulation abnormalities whereas large vessel bleedings are usually caused by infectious, cardiac, congenital, or neoplastic disorders.

Lungs receive their arterial supply from pulmonary and bronchial arteries. Pulmonary arteries provide almost 99% of the arterial blood whereas bronchial arteries maintain the rest.⁴In cases of massive hemorrhage that require intervention the source of bleeding is pulmonary or bronchial arteries in 90% and 5%, respectively.⁵The remaining portion takes origin from non-bronchial systemic arteries.⁵The diagnostic workup includes computed tomography (CT), bronchoscopy, and angiography.⁶ In the case of massive bleeding active intervention is indicated regardless of the hemodynamic instability. The treatment options include bronchial artery embolization (BAE), bronchoscopy guided bronchial occlusion, surgery, and anti-tuberculosis or anti-fungal medications if required.⁷ BAE is an effective and minimally invasive option. It controls and stops bleeding by angiography guided injection of embolic substances into the bleeding artery.⁸

Herein this study our aim was to demonstrate our single-center experience of super-selective arterial embolization in various cases of massive hemoptysis. Our secondary objectives were to describe the demographic and clinical data of the patients with massive hemoptysis, to evaluate the success rate of the intervention, and to document the complications that we came across in the routine clinical practice.

Materials and Methods

In this study, a total of 72 patients who were admitted to our tertiary center's emergency service or chest diseases department and underwent endovascular treatment in the interventional radiology unit between December 2017 and October 2019 were enrolled. The demographic and clinical data together with the images of the procedures were analyzed retrospectively. Our local ethics committee approved the study protocol in accordance with the principles of the Declaration of Helsinki. All patients gave written informed consent before the procedure. The patients whose records were absent or not complete and who had contact loss of follow-up were excluded. The decision of selective arterial embolization was based on the summation of the clinical and radiologic findings and physical examination by the radiologist and chest disease specialist. Contraindications for the intervention were abnormal coagulopathy caused by disorders related to coagulation factors, abnormal platelet count or function, and usage of antiplatelet or anticoagulant medications. The intervention was postponed until the patient received blood products to correct those deficiencies. The other contraindications were having renal insufficiency or contrast media allergy. All patients had either conventional CT or CT angiography and most had bronchoscopy as part of the diagnostic workup before the procedure.

After the supportive measures such as fluid resuscitation, maintaining the airway, oxygenation, and hemodynamic stability, the selective arterial embolization was applied. Super selective embolization was performed by the same interventional radiologist in all cases. The standard technique was used during BAE under sedation or local anesthesia. Five French catheters (Terumo, Japan) was used to gain arterial access mostly from the femoral artery and less frequently brachial artery. The catheter was passed into the descending thoracic aorta and a descending thoracic aortogram was performed in all patients. After visualizing the bronchial arteries, a microcatheter (Prowler select plus, Cardiva, Spain) was introduced coaxially into the angiographic catheter and advanced through the bleeding site. Diagnostic digital subtraction angiography (DSA) (Infinix, Canon Medical Systems, Japan) was performed in all patients when they applied to our interventional radiology division. The signs and clues about the bleeding site were defined as extravasation, blush, visible abnormalities such as tortuosity, arteriovenous malformation (AVM), aneurysms, dilation, and hypertrophy. Selective subclavian arteriograms were obtained when there was no abnormal bronchial artery to reveal aberrant bronchial vessels or non-bronchial arterial supply to the pulmonary system that might have been responsible for hemoptysis. Other non-bronchial systemic arteries selected were internal mammary, inferior phrenic, intercostal, internal thoracic, thyrocervical trunk, and lateral thoracic arteries. Embolization was performed with polyvinyl alcohol (PVA) or microspheres (Embosphere, Merit Medical, USA). Coil was used when bronchial or systemic non-bronchial arterial embolization failed to stop hemoptysis and in patients with CT findings suggested pulmonary artery AVM. Embolization was performed with mechanical coils in the pulmonary arterial bed only if any abnormalities were detected. Embolization was ended when there was no detected antegrade filling in the bleeding vessel.

Statistical Analysis

The Statistical Package for the Social Sciences, version 25 (SPSS Inc., Chicago, IL, USA) was used for the statistical analysis. Descriptive analysis was made to identify the baseline characteristics of the patients. Mean, standard deviation, and range were used to describe continuous variables. Categorical variables were described as number and percentage Median was used to describe non-parametric variables.

Ethical considerations

Ethical approval was taken from the local ethics committee on 16.07.2020 with a number of E1-20-959.

Results

A total of 72 patients were enrolled in this study. The median age was 55 years (min-max; 22-78). Twenty-five patients (34.70%) were female whereas forty-seven (65.30%) were male. 16 patients had lung cancer (squamous cell / adeno cancer), 7 had an alveolar hemorrhage, 1 patient had pulmonary metastasis of malign melanoma, 2 patients with a mediastinal and hilar mass of unknown origin, 4 patients had tuberculosis, 4 had pulmonary thromboembolism, 1 had stage 3 sarcoidosis, 2 had pneumonia, 1 had cirrhosis and hepato-pulmonary syndrome and the rest 34 patients had bronchiectasis. 2 of 4 tuberculosis patients were receiving anti-tuberculosis treatment. 17 patients had only high-resolution CT (HRCT) whereas the remaining 55 had multidetector CT angiographies (MDCT). All patients had bronchial arteriograms and 10 had additional pulmonary arteriograms (Table 1). Flexible bronchoscopy was performed in 56 of 72 patients. The preprocedural mean Hb level was 10.32 ± 3.43 gr/dl and the mean hematocrit was 40.80 ± 11.22 gr/dl. CT and angiographic images of patients with sarcoidosis, squamous cell lung cancer, metastatic malignant melanoma, tuberculosis, and bronchiectasis were shown in Figure 1, 2, 3, 4 and 5, respectively.

The embolized vessel was right bronchial in 32 cases, left bronchial in 9, bilateral bronchial in 15, costo-bronchial trunk in 10, and non-bronchial in 6 patients (5 intercostal and 1 vertebral arteries). When the branching pattern of the bronchial arteries was considered; in 46 of 72 patients, there were two left bronchial arteries taking origin from the aorta and 1 right bronchial taking origin from the intercostobronchial trunk, in 5 patients there were single bronchial arteries bilaterally, in 15 patients there was a common bronchial artery trunk for both left and right bronchial arteries and in 6 there was an ectopic origin. Regarding the angiographic characteristic patterns suggesting bleeding, the most common finding was vascular hypertrophy followed by vascular irregularity, blush, pseudoaneurysm, contrast extravasation, and bronchial artery- pulmonary artery shunting in 50, 9, 6, 4, 2 and 1 patients, respectively (Table 2). The substance used for embolization was

microsphere in 66 patients whereas PVA in 6. Two patients required detachable coil replacement. Gelatin foam or n-Butyl-2-cyanoacrylate (NBCA) was not used in any of the patients in this study.

Table1. Demographic and clinical data of the patients underwent selective arterial embolization

Age (median: min-max) years	55 (22-78)
Sex (Male/Female) number and percentage	47(65.30%)/25 (34.70%)
Preprocedural mean Hb g/dl	10.32±3.43
Preprocedural mean Htc g/dl	40.80±11.22
Preprocedural clinical diagnosis	34 with bronchiectasis 16 with lung cancer (SCC or Adeno ca) 7 with alveolar hemorrhage 1 with metastasis of malignant melanoma 1 with a mediastinal mass of unknown histopathology 1 with a hilar mass of unknown histopathology 4 with tuberculosis 4 with PTE 1 with sarcoidosis 2 with pneumonia 1 with cirrhosis and hepato-pulmonary syndrome
Preprocedural diagnostic workup	72 had Chest X-ray 17 had HRCT only 55 had contrast-enhanced CT angiography 72 had a bronchial arteriogram 10 had bronchial+ pulmonary arteriogram 56 had flexible bronchoscopy

The immediate clinical success, which was defined as lack of rebleeding within the first 24 hours of selective arterial embolization, was 100%. Rebleeding occurred in 12 patients due to recanalization of the vessel. Nine of rebleeding cases resolved after the second embolization and 3 patients resolved after the third intervention. Rebleeding developed in the first month after embolization in all 12 patients.

Regarding the complications, two patients died in the first three days of bleeding due to respiratory failure and cardiac collapse. There was no intervention-related severe complication. The most common technical challenges were difficult cannulation due to the sharp angle of the targeted artery, tortuosity, vasospasm, ostial narrowing, unexpected multiple branching, and uncooperative patient. The most common recorded complication after embolization was chest or back pain and dysphagia occurred in 22 and 8 patients, respectively. Postembolization syndrome which is defined as fever, leukocytosis, and pain were recorded in 11 patients. Dissection and perforation with the wire occurred in 2 patients. All the complications were asymptomatic and self-limiting and did not affect the technical success of the intervention. Major and debilitating complications such as transverse myelitis, paraparesis, or cortical blindness did not occur in any of the patients.

Table 2. Details of selective bronchial embolization

Name of the embolized vessel	Right bronchial: 32 Left bronchial: 9 Bilateral:15 Costobronchial:10 Nonbronchial:6
Branching pattern	In 46; 2 left bronchial and 1 right bronchial artery In 5; single bronchial arteries bilaterally In 15; Right and left had a common trunk In 6; Ectopic origin
Abnormal angiographic Finding	Hypertrophy (vessel diameter>3mm) in 50 Vascular irregularity in 9 Blush in 6 Pseudoaneurysm in 4 Contrast extravasation in 2 Shunting between bronchial and pulmonary arteries in 1
Embolization Material	Microsphere in 66 PVA in 6 Additional Coil in 2

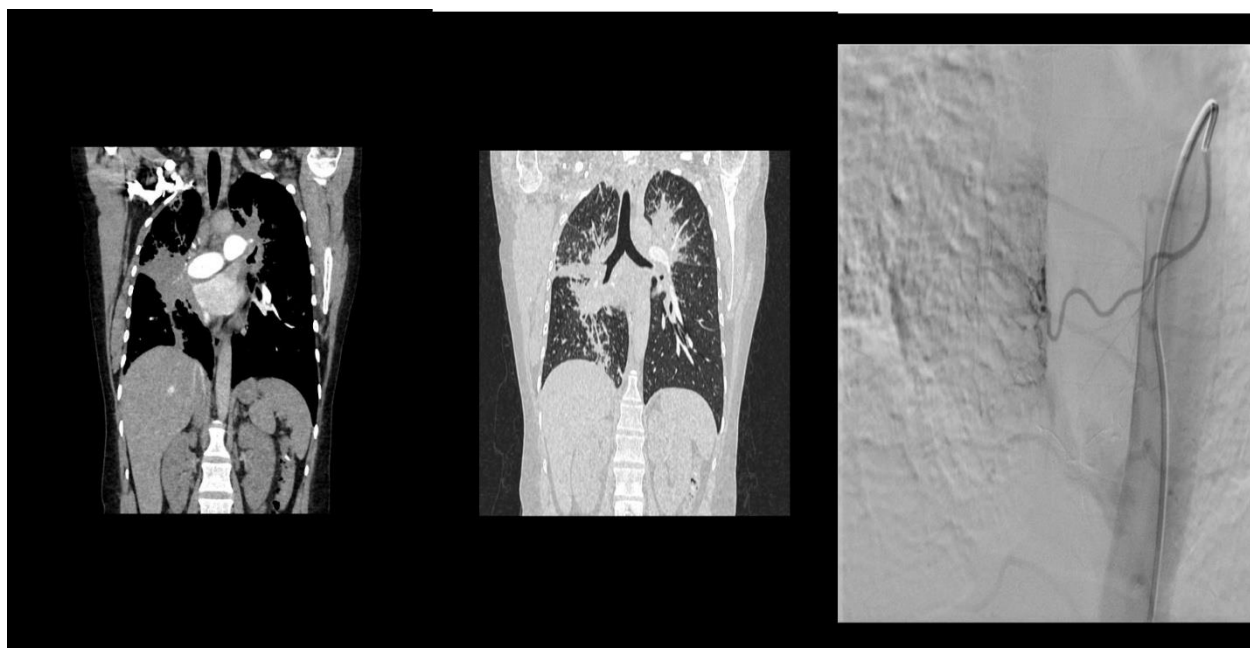


Figure 1. CT and angiographic images of patients with sarcoidosis

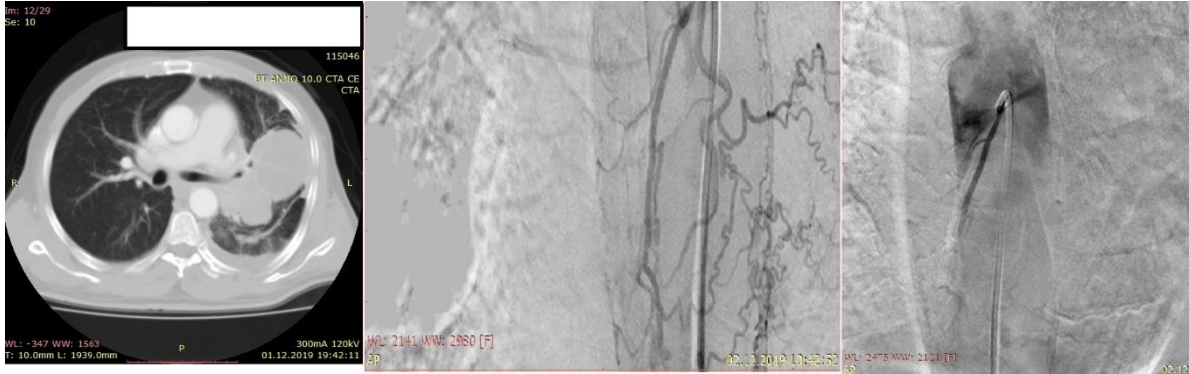


Figure 2. CT and angiographic images of patients with squamous cell lung cancer

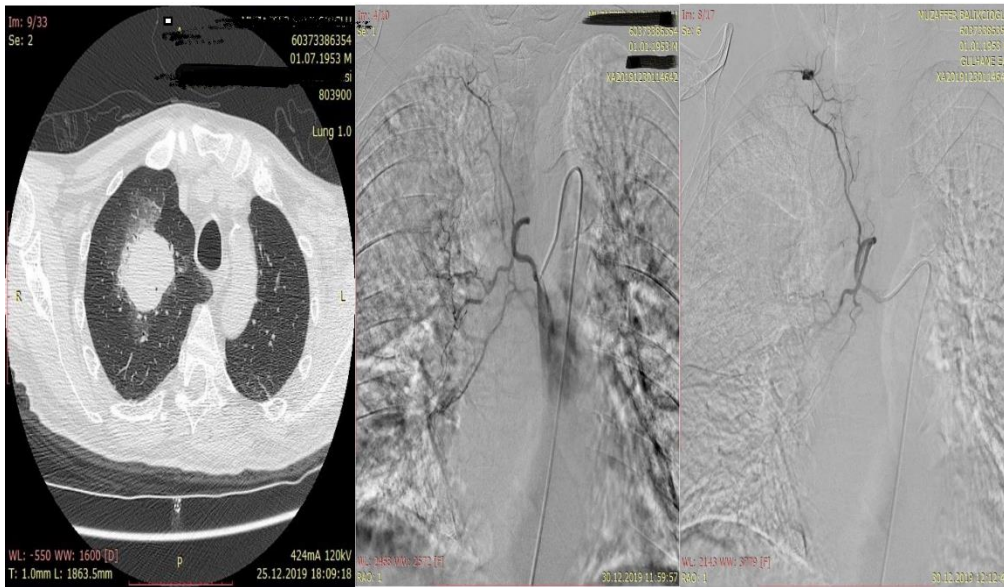


Figure 3. CT and angiographic images of patients with metastatic malignant melanoma

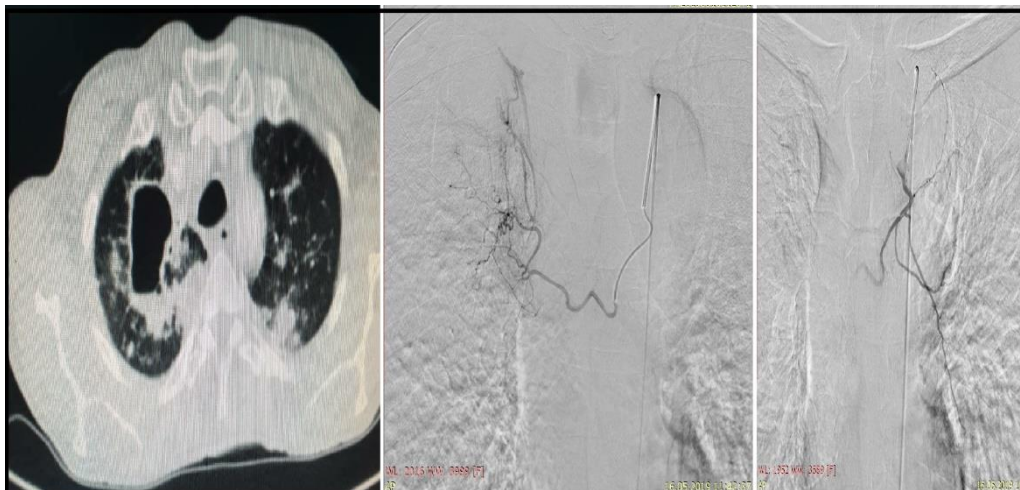


Figure 4. CT and angiographic images of patients with tuberculosis

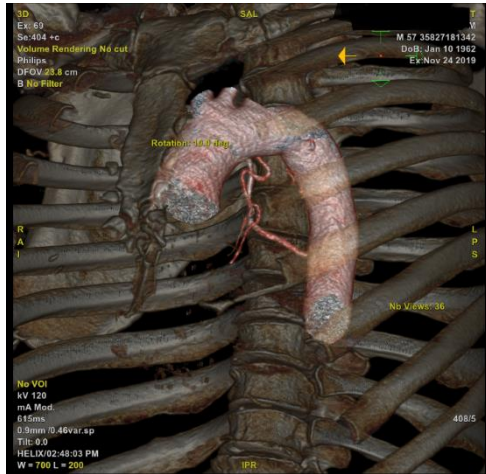


Figure 5. CT and angiographic images of patients with bronchiectasis

Discussion

Massive hemoptysis is a potentially lethal condition that deserves to be investigated thoroughly and brought under control promptly. The mortality rate depends mainly on the underlying etiology and the magnitude of bleeding.⁶ Detecting the bleeding source and possible etiology determines the best management strategy. Super selective arterial embolization is the treatment of choice in most of the cases unless there is chest trauma or iatrogenic pulmonary rupture that warrants surgical treatment.^{9,10} In this study our objective was to evaluate the success of selective arterial embolization with respect to our own experience and determine the demographic profile of our study cohort.

The differential diagnosis of hemoptysis is broad, and the relative frequency may depend on the study population and geographic localization. In our study, the most common underlying disorder was bronchiectasis which was present in 47% (34 of 72) of the patients. The prevalence of tuberculosis is lower compared with previous reports from developing countries which can be explained with unconfirmed tuberculosis cases that were recorded as bronchiectasis in our study.¹¹ In a French nationwide study by Abdulmalak C, the prevalence of bronchiectasis among patients who were admitted with hemoptysis was 6.8 % which is far less than our cohort.¹² In intensive care units in developed countries, the most prevalent etiology of hemoptysis were bronchiectasis and malignancy.¹³

In the literature, most of the massive hemoptysis cases occur in adults between five and seven decades which is compatible with our study. In our study, the male/female ratio was 1.9 in accordance with the previous reports.¹²

In our study, multidetector CT angiography (MDCT) was the most preferred noninvasive diagnostic technique. It includes thick and thin sectional images, two-dimensional maximum intensity projection, and three-dimensional volumetric images. It can provide detection of the location, source, mechanism, and severity of the bleeding and it modifies the management strategy.¹⁴ A recent study indicated that the diagnostic accuracy in showing the bleeding site is between 63-100%.¹⁵ This technique can show the distal airways beyond the level of the bronchoscope and its sensitivity of detecting endobronchial lesions is 90%.¹⁶

In our study, a bronchial arteriogram was performed in all cases before embolization. It demonstrates the bronchial artery anatomy and systemic collaterals. The most common pathological angiography finding in our study was the enlarged diameter of the bleeding artery followed by vascular irregularity and blush. Although extravasation of the contrast agent is considered as the specific sign it was uncommon in our study (2.7%) in accordance with the two previous reports in which the prevalence of that finding was detected as 3-10%.^{5,17} We performed pulmonary aortogram and selective subclavian arteriograms in patients who had no abnormality in bronchial arteriogram or in cases with early recurrent hemoptysis following selective arterial embolization. Pulmonary angiography is especially advocated in patients with tuberculosis to show Rasmussen's aneurysm.¹⁸ In our study, the second most common branching pattern of bronchial arteries was taking origin from a common trunk instead of type II variation (one right bronchial artery from ICBT and one left bronchial artery from the aorta) that was clearly different from the previous reports.¹⁰

The immediate technical success rate of selective arterial embolization in our study was 100%. In previous reports, immediate bleeding control was reported as 70-100%.^{3,8,19} The factors that determine the success rate are the expertise of the interventional radiologist, the choice of the embolic material, ectopic or nonbronchial origin, and patient-related factors such as the presence of vasospasm.²⁰ Rebleeding occurred in 12 patients (16.6) in our study which was compatible with the previous reports that detected recurrence rate between 1-27%.^{2,10,21} All rebleeding events occurred within the first month after the initial embolization. Selective embolization was performed maximum three times. In a previous reports mean number of required embolization per patient was given as 1.8-2.1.^{22,23}

In our study, we mostly used microsphere and less frequently PVA as the embolic agent. Microspheres are hydrophilic and are more uniform in size compared with PVA and thus less prone to clumping within catheters. Experimental studies showed that embospheres tend not to clump within the vessel and catheter and are more successful than distal embolization compared to PVA.²⁴

In our cohort, the most common complication was transient chest pain and dysphagia which was previously reported to occur in 24-90% and 1-20% of the patients, respectively.^{8,10} We did not experience a severe complication. The rate of severe complications is less than <1% in previous reports. The most serious

complication is accidental embolization of the anterior spinal artery, which arises from the right or left intercostal arteries. Accidentally embolizing this vessel causes serious neurological accidents such as Brown-Sequard syndrome or paraplegia. The frequency of this complication is estimated to be between 1.4% and 6.5%.²⁵ Other rare severe complications are cerebrovascular accidents, myocardial necrosis, gastrointestinal infarct, and splenic hematoma.²⁶

The limitations of our study were the limited number of patients and retrospective nature. There is also a lack of long term follow up results. We did not compare the success of this technique between patients with different underlying pathologies.

In conclusion, appropriate management of hemoptysis in different clinical settings is critical, especially in case of massive bleeding, which represents a life-threatening condition. Currently, arterial embolization is the most effective and minimally invasive procedure for treating massive and recurrent hemoptysis. This study confirms its efficacy and safety.

Conflict of interest

The authors declare that there is no conflict of interest.

References

1. Ittrich H, Bockhorn M, Klose H, Simon M. The Diagnosis and Treatment of Hemoptysis. *Dtsch Arztebl Int.* 2017;114(21):371-81 (doi:10.3238/arztebl.2017.0371).
2. Panda A, Bhalla AS, Goyal A. Bronchial artery embolization in hemoptysis: a systematic review. *Diagn Interv Radiol.* 2017;23(4):307-17 (doi:10.5152/dir.2017.16454).
3. Yoo DH, Yoon CJ, Kang SG, Burke CT, Lee JH, Lee CT. Bronchial and nonbronchial systemic artery embolization in patients with major hemoptysis: safety and efficacy of N-butyl cyanoacrylate. *AJR Am J Roentgenol.* 2011;196(2):W199-204 (doi:10.2214/AJR.10.4763).
4. Cauldwell EW, Siekert RG, et al. The bronchial arteries; an anatomic study of 150 human cadavers. *Surg Gynecol Obstet.* 1948;86(4):395-412.
5. Larici AR, Franchi P, Occhipinti M, et al. Diagnosis and management of hemoptysis. *Diagn Interv Radiol.* 2014;20(4):299-309 (doi:10.5152/dir.2014.13426).
6. Jean-Baptiste E. Clinical assessment and management of massive hemoptysis. *Crit Care Med.* 2000;28(5):1642-7 (doi:10.1097/00003246-200005000-00066).
7. Ishikawa H, Hara M, Ryuge M, et al. Efficacy and safety of super selective bronchial artery coil embolisation for haemoptysis: a single-centre retrospective observational study. *BMJ Open.* 2017;7(2):e014805 (doi:10.1136/bmjopen-2016-014805).
8. Woo S, Yoon CJ, Chung JW, et al. Bronchial artery embolization to control hemoptysis: comparison of N-butyl-2-cyanoacrylate and polyvinyl alcohol particles. *Radiology.* 2013;269(2):594-602 (doi:10.1148/radiol.13130046).
9. Haponik EF, Fein A, Chin R. Managing life-threatening hemoptysis: has anything really changed? *Chest.* 2000;118(5):1431-5 (doi:10.1378/chest.118.5.1431).
10. Chun JY, Morgan R, Belli AM. Radiological management of hemoptysis: a comprehensive review of diagnostic imaging and bronchial arterial embolization. *Cardiovasc Intervent Radiol.* 2010;33(2):240-50 (doi:10.1007/s00270-009-9788-z).
11. Bhalla A, Pannu AK, Suri V. Etiology and outcome of moderate-to-massive hemoptysis: Experience from a tertiary care center of North India. *Int J Mycobacteriol.* 2017;6(3):307-10 (doi:10.4103/ijmy.ijmy_54_17).
12. Abdulmalak C, Cottenet J, Beltramo G, et al. Haemoptysis in adults: a 5-year study using the French nationwide hospital administrative database. *Eur Respir J.* 2015;46(2):503-11 (doi:10.1183/09031936.00218214).
13. Lee BR, Yu JY, Ban HJ, et al. Analysis of patients with hemoptysis in a tertiary referral hospital. *Tuberc Respir Dis (Seoul).* 2012;73(2):107-14 (doi:10.4046/trd.2012.73.2.107).

14. Bruzzi JF, Remy-Jardin M, Delhaye D, Teisseire A, Khalil C, Remy J. Multi-detector row CT of hemoptysis. *Radiographics*. 2006;26(1):3-22 (doi:10.1148/rg.261045726).
15. Mori H, Ohno Y, Tsuge Y, et al. Use of multidetector row CT to evaluate the need for bronchial arterial embolization in hemoptysis patients. *Respiration*. 2010;80(1):24-31 (doi:10.1159/000253882).
16. Sirajuddin A, Mohammed TL. A 44-year-old man with hemoptysis: a review of pertinent imaging studies and radiographic interventions. *Cleve Clin J Med*. 2008;75(8):601-7 (doi:10.3949/ccjm.75.8.601).
17. Ramakantan R, Bandekar VG, Gandhi MS, Aulakh BG, Deshmukh HL. Massive hemoptysis due to pulmonary tuberculosis: control with bronchial artery embolization. *Radiology*. 1996;200(3):691-4 (doi:10.1148/radiology.200.3.8756916).
18. Sbano H, Mitchell AW, Ind PW, Jackson JE. Peripheral pulmonary artery pseudoaneurysms and massive hemoptysis. *AJR Am J Roentgenol*. 2005;184(4):1253-9 (doi:10.2214/ajr.184.4.01841253).
19. Earwood JS, Thompson TD. Hemoptysis: evaluation and management. *Am Fam Physician*. 2015;91(4):243-9.
20. Wielputz MO, Heussel CP, Herth FJ, Kauczor HU. Radiological diagnosis in lung disease: factoring treatment options into the choice of diagnostic modality. *Dtsch Arztebl Int*. 2014;111(11):181-7 (doi:10.3238/arztebl.2014.0181).
21. Sopko DR, Smith TP. Bronchial artery embolization for hemoptysis. *Semin Intervent Radiol*. 2011;28(1):48-62 (doi:10.1055/s-0031-1273940).
22. Shin BS, Jeon GS, Lee SA, Park MH. Bronchial artery embolisation for the management of haemoptysis in patients with pulmonary tuberculosis. *Int J Tuberc Lung Dis*. 2011;15(8):1093-8 (doi:10.5588/ijtld.10.0659).
23. Bhalla A, Kandasamy D, Veedu P, Mohan A, Gamanagatti S. A retrospective analysis of 334 cases of hemoptysis treated by bronchial artery embolization. *Oman Med J*. 2015;30(2):119-28 (doi:10.5001/omj.2015.26).
24. Tom LM, Palevsky HI, Holsclaw DS, et al. Recurrent Bleeding, Survival, and Longitudinal Pulmonary Function following Bronchial Artery Embolization for Hemoptysis in a U.S. Adult Population. *J Vasc Interv Radiol*. 2015;26(12):1806-13 e1 (doi:10.1016/j.jvir.2015.08.019).
25. Vanni S, Bianchi S, Bigiarini S, et al. Management of patients presenting with haemoptysis to a Tertiary Care Italian Emergency Department: the Florence Haemoptysis Score (FLHASc). *Intern Emerg Med*. 2018;13(3):397-404 (doi:10.1007/s11739-017-1618-8).
26. Labbe V, Roques S, Boughdene F, et al. Shock complicating successful bronchial artery embolization for severe hemoptysis. *Chest*. 2009;135(1):215-7 (doi:10.1378/chest.08-0491).