



### A Nicolau Syndrome Confused with Cellulite

#### ABSTRACT

Nicolau syndrome, also known as embolia cutis medicamentosa or livedoid dermatitis, emerges as a rare complication following intramuscular, subcutaneous, or intraarticular injections. This condition may result in severe pain, erythematous lesions, livedoid and hemorrhagic plaques, as well as necrosis affecting the skin, fat, and muscle layers post-injection. Notable causative agents encompass non-steroidal anti-inflammatory drugs (NSAIDs), etanercept, and antibacterial agents. While there's no definitive cure for Nicolau syndrome, available treatment options range from wound care, bed rest, and pain management to antibiotics for secondary infections, topical, intralesional, and systemic corticosteroids. Moreover, vasoactive agents like alprostadil and pentoxifylline, anticoagulants, and hyperbaric oxygen therapy can be utilized. In severe cases marked by necrosis, surgical interventions become imperative. This report presents a case where a female patient developed Nicolau syndrome following a diclofenac sodium injectio.

**Keywords:** Cellulite, intramuscular injection, Nicolau syndrome, treatment

Nicolau syndrome (NS), also known as embolia cutis medicamentosa or livedo dermatitis, is a rare complication that arises after intramuscular, subcutaneous, or intraarticular injections. This condition can result in intense pain, erythematous lesions, livedoid and hemorrhagic plaques, and necrosis of the skin, fat, and muscle layers following an injection (1). This case discusses a female patient who developed NS after a diclofenac sodium injection.

#### CASE REPORT

A 58-year-old female patient with hypertension and diabetes mellitus had been monitored with a preliminary diagnosis of cellulitis for 10 days before being referred to a dermatology clinic. Her anamnesis revealed that she experienced a sudden onset of pain and redness in the left gluteal area following an intramuscular diclofenac injection 11 days prior. She had been treated with intravenous antibiotics, non-steroidal anti-inflammatory drugs (NSAIDs), and enoxaparin. However, her pain did not subside, and there was no improvement in the lesion. While the bacterial culture came back negative, laboratory studies showed an elevated CRP level, which subsequently decreased with antibiotic treatment. Upon examination, a large erythematous plaque was observed on the upper lateral aspect of her left gluteal region, displaying necrotic and livedoid areas and encircled by an erythematous ring (Figure 1). A punch biopsy was taken, suspecting NS as a preliminary diagnosis. The histopathology reported cutaneous-subcutaneous tissue signs of ischemia, characterized by epidermal necrosis and interpreted as consistent with NS (Figure 2). A combination of topical-systemic corticosteroids, pentoxifylline, and topical antibiotics were prescribed as treatment. Additionally, debridement and hyperbaric oxygen therapy were recommended.

#### DISCUSSION

Nicolau Syndrome (NS) is a rare complication arising after intramuscular, subcutaneous, or intraarticular injections. It progresses through initial, acute, and necrotic phases. During the initial phase, individuals may experience sudden intense pain at the injection site, which is then accompanied by redness, hemorrhage, and occasionally conditions like peroneal neuropathy and syncope. The acute phase is characterized by the appearance of livedoid plaques and violaceous patches, while the necrotic phase presents with enduring necrotic

Tuğba Atak<sup>1</sup>

Oğuz Kaan Yılmaz<sup>1</sup>

Filiz Canpolat<sup>1</sup>

Selda Pelin Kartal<sup>1</sup>

Ünsal Han<sup>2</sup>

<sup>1</sup>Dermatology Clinic, Ankara Etilik City Hospital, Ankara, Türkiye

<sup>2</sup>Pathology and Cytology Clinic, Ankara Dışkapı Training and Research Hospital, Ankara, Türkiye

#### Corresponding author:

Tuğba Atak  
✉ tugba.atak@dr.com

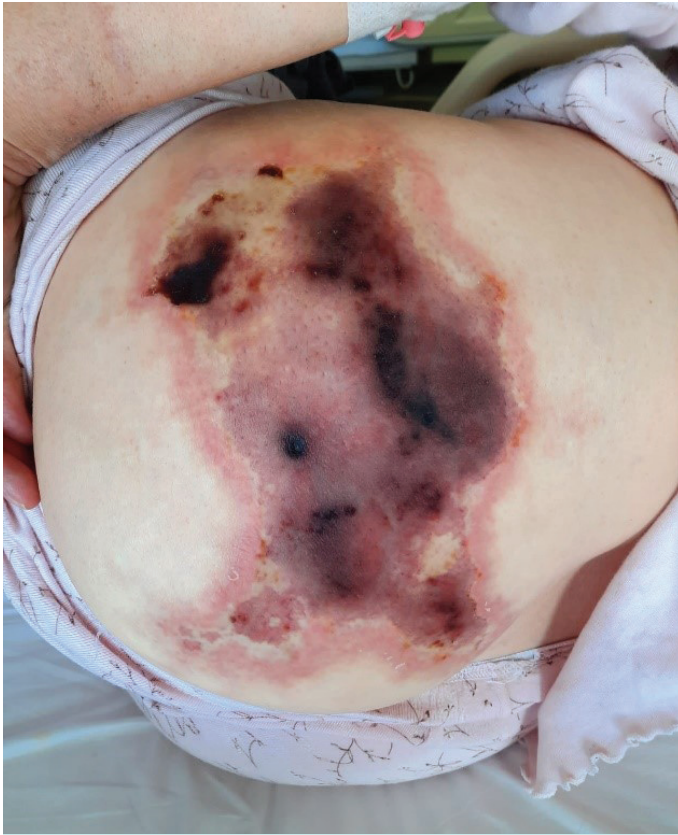**Received:** September 10, 2023

**Accepted:** September 18, 2023

**Cite this article as:** Atak T, Yılmaz OK, Canpolat F, Kartal SP, Han Ü. A Nicolau syndrome confused with cellulite. Acad J Health 2023;1(1):31-32.

DOI: 10.14744/ajh.2023.32042



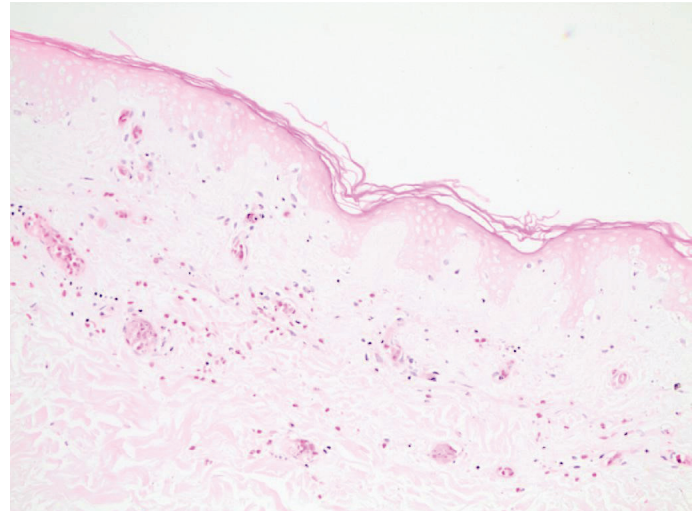


**Figure 1.** Large, erythematous plaque with necrotic and livedoid areas on it, surrounded by an erythematous ring, and hard compared to the surrounding tissue.

plaques and ulcers. Common causative agents include NSAIDs, etanercept, and antibacterial agents. The gluteal region is most frequently affected, but cases have been reported involving the thigh, knee, and ankle (1). The patient in our case study developed symptoms after an intramuscular injection of diclofenac sodium.

The exact pathogenesis remains unclear, but primary mechanisms involve thromboembolic occlusion in arterioles, arterial inflammation, and acute vasospasm (1, 2). Histopathological findings are predominantly seen in the necrotic phase, showing inflammatory infiltration of the subcutaneous adipose tissue by eosinophils without signs of adipose tissue fibrosis, fat necrosis, vasculitis, or granuloma. Conditions like local toxic reactions, acute bleeding, acute compartment syndrome, vasculitis, fat embolism, cellulitis, and malignancies should be considered in the differential diagnosis. Misdiagnosing NS as cellulitis can lead to unnecessary antibiotic use and further progression of the condition (1).

While no specific treatment exists for NS, conservative and localized treatments are recommended during the acute stage. When necrosis is evident, surgical intervention becomes necessary. Conservative measures encompass wound care, bed rest, pain management, antibiotics to combat secondary infections, topical, intralesional, and systemic corticosteroids to mitigate acute tissue inflammation, vasoactive agents such as alprostadil and pentoxifylline to counteract vasospasm, anticoagulants like heparin, and hyperbaric oxygen therapy. Early wound debridement is crucial in



**Figure 2.** Skin-subcutaneous tissue showing signs of ischemia characterized by epidermal necrosis (H-E x 100).

preventing the escalation of necrosis. Despite treatments, patients might still be left with atrophic scars (3,4). In rare instances, these scars can evolve into soft tissue sarcomas (5). To prevent NS, it's advisable to use the correct needle length, perform negative aspiration before injection, maintain a constant injection velocity, and employ the Z-track technique (2).

In conclusion, we presented this case to highlight NS, emphasizing the critical role of patient history in diagnosis. With early detection, complications can be mitigated through conservative measures, potentially avoiding the need for extensive surgical interventions.

**Informed Consent:** Written informed consent was obtained from the patient for the publication of the case report and the accompanying images.

**Peer-review:** Externally peer-reviewed.

**Conflict of Interest:** The authors have no conflict of interest to declare.

**Funding:** The authors declared that this study has received no financial support.

## REFERENCES

1. Kim KK, Chae DS. Nicolau syndrome: A literature review. *World J Dermatol* 2015;4(2):103-7. [\[CrossRef\]](#)
2. Koller S, Kränke B. Nicolau syndrome following subcutaneous glatiramer-acetate injection. *J Am Acad Dermatol* 2011;64(2):e16-7. [\[CrossRef\]](#)
3. Nischal K, Basavaraj H, Swaroop M, Agrawal D, Sathyanarayana B, Umashankar N. Nicolau syndrome: an iatrogenic cutaneous necrosis. *J Cutan Aesthet Surg* 2009;2(2):92-5. [\[CrossRef\]](#)
4. Kılıç İ, Kaya F, Özdemir AT, Demirel T, Çelik İ. Nicolau syndrome due to diclofenac sodium (Voltaren®) injection: a case report. *J Med Case Rep* 2014;8(1):404. [\[CrossRef\]](#)
5. Mayrink M, Mendonça AC, da Costa PR. Soft-tissue sarcoma arising from a tissue necrosis caused by an intramuscular injection of diclofenac. *Plast Reconstr Surg* 2003;112(7):1970-1. [\[CrossRef\]](#)