



DOI: 10.5505/anatoljfm.2023.12599  
Anatol J Family Med 2023;6(1):48–49

## A Rare Case of Pretibial Dystrophic Epidermolysis Bullosa: A Scientific Letter

✉ Nirma Joy, ✉ Surajit Nayak

Department of Dermatology, Mkcg Medical College, Berhampur, India

Dear Editor,

We would like to mention our epidermolysis bullosa case. A 15-year-old female patient presented to our dermatology department with cutaneous lesions distributed over both lower legs and dorsum of hands and feet, along with nail dystrophy since birth. The patient is the youngest daughter of a non-consanguineous marriage, and her elder sister has similar complaints but of milder grades. The patient has normal intellectual ability, currently studying in 9th standard with average academic performance. At the time of birth, her parents noticed a single fluid-filled lesion over her right lower leg, which gradually grew bigger in size and ruptured within 3–4 days, leaving an atrophic scar. The toenails of both feet and four fingernails of the left hand, sparing the left ring finger, have been absent since birth. The patient had several similar episodes of cutaneous lesions associated with itching over both shins and dorsum of feet and developed a contracture in the dorsum of the right foot leading to hyperextension of the right big toe. There is no history of photosensitivity, mucosal lesions, joint pain, or other significant systemic complaints. On clinical examination, there are multiple sclerotic depigmented plaques, a few plaques with the rim of hyperpigmentation distributed over both lower legs, dorsum of both hands and feet with mild scaling and yellowish crust over the right leg (Figs. 1 and 2). Old lesions healed with atrophic scars and post-inflammatory hypopigmentation with hyperextension of the right metatarsophalangeal joint of the right big toe. There are erosions over the anterior surface of the right lower leg, and right knee with no signs of secondary infection and single tense bullae of size 2 × 2 cm over the right leg with Nikolsky's sign negative and rounded border on bullae spread sign. The scalp, all mucosae, teeth, hair, palms, and soles are looking normal. The clinical differential diagnoses were dystrophic epidermolysis bullosa (DEB), lichen planus pemphigoid, and bullous lupus erythematosus. The routine blood and urine investigations were found to be normal. Serum anti-nuclear antibody was normal, hence ruling out the possibility of bullous lupus erythematosus. The potassium hydroxide microscopy from nail clippings was done to rule out fungal pathology. Histopathological examination showed a subepidermal cleft with significant inflammatory infiltrate just below the basement membrane zone along with dermal fibrosis. Specific immune deposits were not detected in the direct immunofluorescence study, and the lupus band test was negative. The presence of recurrent episodes of fluid-filled lesions associated with itching and nail dystrophy localized over both lower legs and dorsum of feet and hands with histopathology and immunofluorescence findings pointing toward the diagnosis of a rare pretibial variant of DEB. The patient was given emollients, antihistamines, and topical antibiotics and was explained the prognosis and course of the disease. The patient was advised to take proper protection to



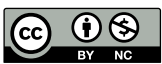
Please cite this article as:  
Joy N, Nayak S. A Rare Case of Pretibial Dystrophic Epidermolysis Bullosa: A Scientific Letter. Anatol J Family Med 2023;6(1):48–49.

**Address for correspondence:**  
Dr. Nirma Joy, Department of Dermatology, Mkcg Medical College, Berhampur, India  
**Phone:** 9400508101  
**E-mail:** nirmajoy@gmail.com

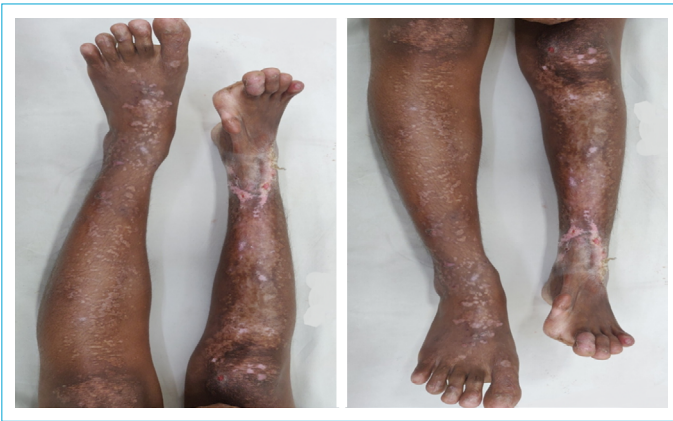**Received Date:** 23.03.2022  
**Revision Date:** 01.07.2022  
**Accepted Date:** 15.03.2023  
**Published online:** 28.04.2023

©Copyright 2023 by Anatolian Journal of Family Medicine - Available online at [www.anatoljfm.org](http://www.anatoljfm.org)

OPEN ACCESS



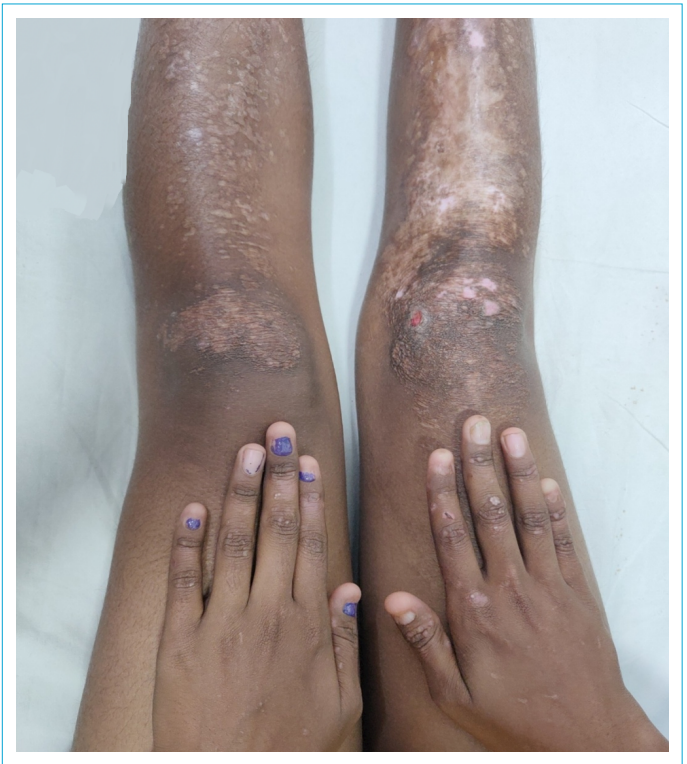This work is licensed under a Creative Commons Attribution-NonCommercial 4.0 International License.



**Figure 1.** Multiple depigmented sclerotic plaques with old atrophic scars, post-inflammatory hypopigmentation over both legs, hyperextension of right metatarsophalangeal joint with complete nail dystrophy, single tense bullae and erosion with crusting over the right leg.

prevent trauma and friction, like wearing well-fitting footwear, leather shoes with lining and wearing two pairs of socks.

DEB can be autosomal recessive or dominant, and irrespective of genotype, it results from a mutation in a single gene, COL7A1, located in chromosome 3 (3p21.1), which encodes Type VII collagen, which is the major component of anchoring fibril structures beneath the lamina densa.<sup>[1]</sup> Dominant DEB is subdivided into six subtypes: generalized, acral, pretibial, pruriginous, nails only and bullous dermolysis of newborns. This rare pretibial variant of DEB was first described by Kuske in 1946, and it has a prevalence of <1/10.00.000. It is distinguished from other forms by milder phenotype, more localized lesions with blisters and erosions, scarring, milia formation with frequent pruritus and nail dystrophy. Apart from histology, the level of blister formation can be determined using antigen immunomapping, which shows deposition of fluorescence on the roof of the blister (epidermal side) with the presence of four main antibodies against collagen Type IV, bullous pemphigoid antigen, laminin, collagen Type VII demonstrating cleavage in sublamina densa. Unfortunately, there is no effective treatment for epidermolysis bullosa.<sup>[2]</sup> The mainstay of treatment includes the prevention of trauma and local wound care. Cyclosporine, thalidomide, and topical tacrolimus can be given in cases with refractory pruritus. Recent advances in the treatment of epidermolysis bullosa, including Gene therapy, protein replacement therapy, and cell-



**Figure 2.** Nail dystrophy of left hand sparing left ring finger.

based therapies like injecting purified human recombinant Type VII collagen into circulation, are being under trial.<sup>[3]</sup>

#### Disclosures

**Informed Consent:** Verbal and written consent taken from the patient.

**Conflicts of Interest:** None.

**Peer-Review:** Externally peer-reviewed.

**Financial Disclosure:** None.

#### REFERENCES

1. Callegaro EAC, Nappi F, Lazzarini R, Lellis RF. Pretibial dystrophic epidermolysis bullosa: case report. *An Bras Dermatol* 2017;92(5 Suppl 1):126–8. [\[CrossRef\]](#)
2. Vijaya B, Narahari SR, Deka P, Manjunath GV. Pretibial dystrophic epidermolysis bullosa pruriginosa: A rare case report in a child with low intelligent quotient. *Indian J Paediatr Dermatol* 2016;17(1):32–4. [\[CrossRef\]](#)
3. Soro L, Bartus C, Purcell S. Recessive dystrophic epidermolysis bullosa a review of disease pathogenesis and update on future therapies. *J Clin Aesthet Dermatol* 2015;8(5):41–6.