



CASE REPORT

A rare cause of pelvic pain: Osteitis pubis treated with steroid injection under fluoroscopy guidance

Nadir bir pelvik ağrı nedeni: Floroskopi rehberliğinde steroid enjeksiyonu ile tedavi edilen osteitis pubis

Hamit GÖKSU, Şeref ÇELİK, Erkan Yavuz AKÇABOY

Summary

Osteitis pubis (OP) is a rare, inflammatory disorder that affects the pubic bone, symphysis, and adjacent structures. OP is reported after urological and gynecological surgeries and documented in athletes. OP is a self-limiting condition, but sometimes symptoms may persist for a long time. Conservative modalities are generally able to treat OP. Here we report a patient treated with a steroid injection under fluoroscopy guidance. A 63-year-old male patient developed pelvic pain after prostate surgery, and the pain was intractable to non-steroidal anti-inflammatory drugs. He underwent a steroid injection under fluoroscopy, and his pain affecting daily living activities and walking was eased for three months.

Keywords: Fluoroscopy; osteitis pubis; prostate surgery; steroid injection.

Özet

Osteitis pubis (OP), pubik kemiği, simfizisi ve komşu yapıları etkileyen nadir görülen inflamatuvar bir hastalıktır. OP, ürolojik ve jinekolojik cerrahi sonrası ve sporcularda bildirilmiştir. OP kendi kendini sınırlayan bir durumdur ancak bazen semptomlar uzun süre devam edebilir. OP genellikle konservatif yöntemler ile tedavi edilebilir. Burada floroskopi rehberliğinde steroid enjeksiyonu ile tedavi edilen bir hastayı bildirdik. 63 yaşındaki erkek hastada prostat cerrahisi sonrası nonsteroid antiinflamatuvar ilaçlara dirençli pelvik ağrı gelişmişti. Floroskopi altında steroid enjeksiyonu yapılan hastanın günlük yaşam aktivitelerini ve yürümeyi etkileyen ağrıları üç ay boyunca hafifletildi.

Anahtar sözcükler: Floroskopi; osteitis pubis; prostat cerrahisi; steroid enjeksiyonu.

Introduction

Osteitis pubis (OP) is a rare, painful, noninfectious inflammatory condition that involves the pubic bone, symphysis, and surrounding structures.^[1] OP can be seen after urological surgery, gynecological procedures, and birth. The majority of case series were reported in athletes.^[2,3] The exact cause is unclear, but overuse injury is believed to be the most probable factor in many studies.^[4,5]

Patients with OP commonly present with pelvic pain. Diagnosis of OP is mainly based on clinical and radiological findings. OP is generally self-limiting, but symptoms may persist; thus, treatment of OP primarily consists of conservative modalities.^[6,7] For

patients unresponsive to conservative treatments, surgery may be necessary.^[8] Here we aimed to report a patient with OP secondary to robotic transurethral resection of the prostate (TUR-P) surgery, whose pain was resistant to conservative treatments and was treated with a steroid and local anesthetic injection under fluoroscopy guidance.

Case Report

A 63-year-old man came to our clinic with pubic and groin pain. He had a robotic TUR-P surgery for prostate adenocarcinoma two months ago. On the fifth day after the surgery, his pain started in the groin and pelvic region. After the surgery, he had a urinary tract infection that was cured with broad-

Department of Algology, Ankara City Hospital, Ankara, Türkiye

Submitted (Başvuru): 15.05.2021 Accepted (Kabul): 15.11.2021 Available online (Online yayımlanma): 05.07.2024

Correspondence: Dr. Hamit Göksu. Ankara Şehir Hastanesi, Algoloji Kliniği, Ankara, Türkiye.

Phone: +90 - 532 - 777 64 91 **e-mail:** hamitgoksu@yahoo.com

© 2024 Turkish Society of Algology

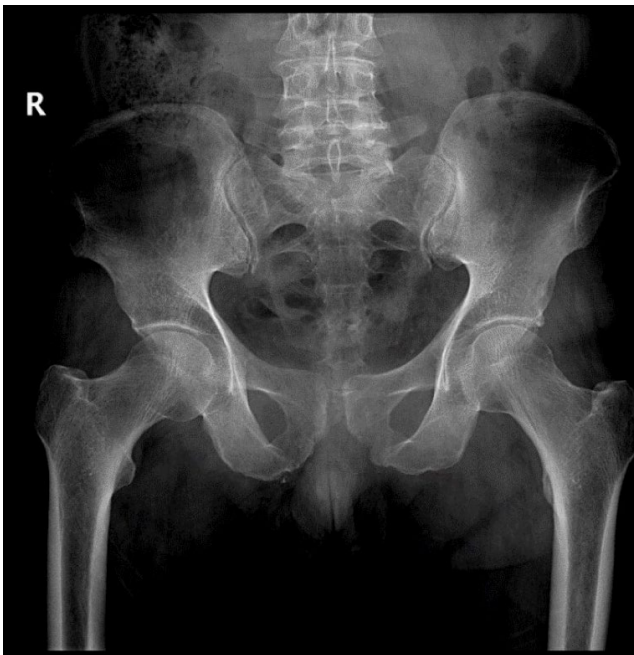

Figure 1. Anteroposterior radiograph of pelvis showing joint border irregularities and joint space widening.

spectrum antibiotics. Due to pubic and groin pain, Magnetic Resonance Imaging (MRI) and Electroneuromyography (ENMG) tests were performed before he came to our clinic. The MRI of the lumbar spine detected no nerve or cord compression, and Electroneuromyography tests were within normal limits. His pain was resistant to non-steroidal anti-inflammatory drugs. When he was admitted to our clinic, his pain was especially on the pubis, with minimal pain on the inner surface of the thigh. The Visual Analog Scale (VAS) score was 8 for the pubis and 4 for the thigh on a 10-cm scale. When he was standing and walking, his pain was aggravated, and he had great difficulty walking alone. In his physical examination, the left hip range of motion was limited for abduction and adduction. FABERE and FADIR tests were positive on the left side. He had severe tenderness on the pubis. Adductor muscle palpation was minimally painful. Lumbar spine, sacroiliac joint, and other lower extremity joint examinations were normal. No sensorial anomaly was found, and deep tendon reflexes were normal. We took a pelvic MRI and X-ray from the patient with the pre-diagnosis of OP. The pelvic X-ray showed irregularities in the pubic symphysis and minimal joint distance widening (Fig. 1). Pelvic MRI demonstrated that the pubic symphysis distance was increased, there was bone marrow edema in the pubic bones, and a low-grade strain in the muscles adjacent to the pubic and effusion between the pectineus and adductor brevis

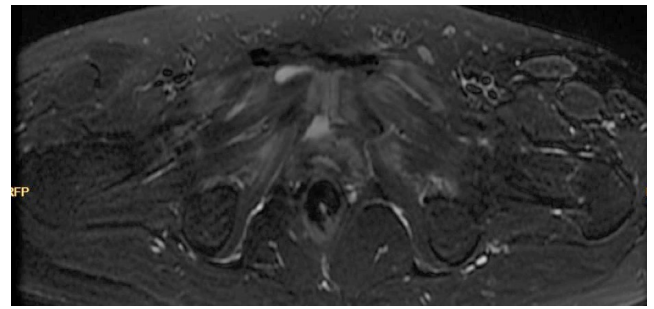


Figure 2. Axial T2-section of MRI showing bilateral bone marrow edema, periarticular edema and low grade adductor strain.

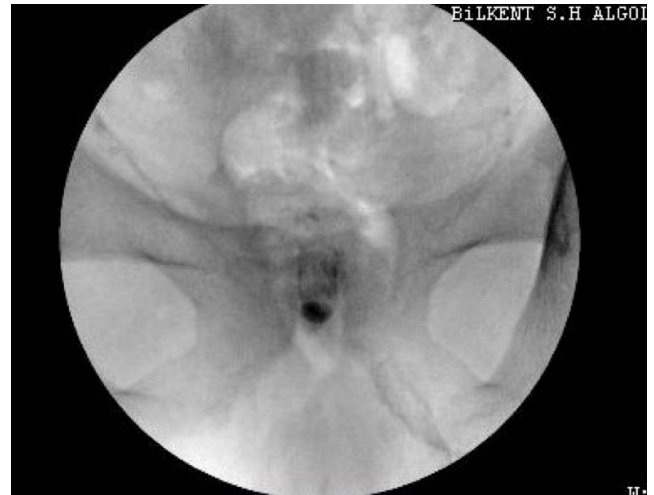

Figure 3. Contrast dye pattern at symphysis under fluoroscopy.

(Fig. 2). Complete blood count, sedimentation, C-RP, renal and liver function tests, urinary analysis, and culture were normal. After the diagnosis of OP, the patient underwent steroid injection treatment under fluoroscopic guidance. Using sterile techniques and a cutaneous local anesthetic injection with 3 cc lidocaine, a 22-gauge needle was inserted into the middle of the symphysis pubis under fluoroscopy. When we felt the sensation of reaching the disc, the needle was moved forward 1 cm away. Then, 1 cc non-ionic contrast was injected, and discal involvement of contrast was seen. So, 4 mg dexamethasone and 1 cc bupivacaine were injected (Fig. 3). For inner thigh pain and effusion between adductor muscles, we suggested ice and topical drugs because the pain was not severe. At one month, his pain had decreased significantly; the VAS score for pubic pain was 4. Inner thigh pain was absent. The range of motion was normal, and pubic symphysis tenderness was decreased. At three months, his pubic pain was better, and the VAS score was 3. Due to the improvement and the absence of severe pain that made daily living activities difficult, no further treatment was planned.

Discussion

TUR-P surgery is one of the most common factors for OP. Mechanical trauma during surgery, urinary system infection, and senility may cause bone irritation and venous congestion, resulting in OP. In our patient, these factors may play a role in the etiopathogenesis as well. Also, pelvic instability and insufficiency fractures may accompany OP, but these were not seen in our patient.^[9] Athletic pubalgia, osteomyelitis (OM), adductor and rectus femoris strain, hip pathologies, lower back pain referring to the groin, nerve compression, genitourinary and pubic infection must be considered in differential diagnosis.^[1,10,11] Especially patients with fever and resistant to therapy must be investigated for osteomyelitis. Osteomyelitis (OM) generally begins as unilateral and then becomes bilateral, with bone destructions being progressive. Abnormal levels of CRP, sedimentation, and leukocyte count suggest OM. Aggressive antibiotherapy and, if necessary, early surgical debridement must be considered. For patients unresponsive to conservative treatment, with clinical radiologic and laboratory findings worsened, aspiration biopsy or an open biopsy should be planned.^[12] Adductor strain is another entity that may coexist with OP and must be considered. Diagnosis of adductor strain is made by clinical suspicion. Physical examination may reveal focal swelling, spasm along the adductors, and decreased adductor muscle strength. In our patient, adductor strain accompanied OP, but pain was decreased in the adductor muscle with non-steroidal anti-inflammatory drugs and ice therapy. Athletic pubalgia is another common cause of chronic groin and adductor pain in athletes, secondary to disruption of the rectus tendon insertion to the pubis and weakness of the posterior inguinal wall.^[13]

The management of OP includes conservative and surgical options. Therefore, OP primarily should be treated conservatively since OP is a self-limiting condition, albeit symptoms may persist up to a year.^[10] Conservative treatment modalities consist of ice, rest, and anti-inflammatory drugs. Physical therapy improves symptoms and facilitates the return to activities.^[14,15] Other alternatives are steroid injection, prolotherapy, and anticoagulant thera-

py.^[8,10,16] Surgical treatment may be necessary for 5-10% of patients when conservative modalities fail to treat.^[17] Many surgical approaches like open or endoscopic curettage of the symphysis pubis, arthrodesis of the symphysis with or without bone graft, and wedge resection have been reported in the literature.^[18,19]

OP patients may benefit from steroid injection, as in our patient. There are few reports, and the dosage and frequency of injection are controversial.^[10,16,20] O'Connell et al.^[20] reported that symphyseal cleft injection is a useful technique for the diagnosis and treatment of OP in athletes. At 2 months after the procedure, five (31.2%) of the 16 patients were completely symptom-free, and all patients had less pain at the 6-month follow-up. Holt et al.^[16] found that steroid injection improves symptoms and shortens the duration to return to activities in 12 athletes. In their systematic review, Choi et al.^[10] reported that a majority (58.6%) of athletes treated with corticosteroid injections were able to return to sport; however, a significant non-responder rate (20.7%) was present. In our patient, pain was moderately decreased at the beginning after injection, and at 3 months, his pain was minimal, not diminishing daily activities. Because these case series mainly consist of athletes, we don't have information about OP associated with urological procedures like TUR-P in our patient. Therefore, since etiopathogenesis and radiological and clinical findings are similar, patients with OP secondary to urological procedures may benefit from steroid injection, as in our patient.

Conclusion

As a conclusion, OP should be considered in patients with groin and pelvic pain secondary to prostate surgery. Conservative treatments, including steroid injection, may be helpful for most patients after excluding other disorders.

Conflict-of-interest issues regarding the authorship or article: None declared.

Informed Consent: Written informed consent was obtained from patients who participated in this study.

Use of AI for Writing Assistance: Not declared.

Peer-review: Externally peer-reviewed.

References

1. Dirkx M, Vitale C. Osteitis Pubis. In: StatPearls. Treasure Island (FL): StatPearls Publishing; 2024.
2. Beatty T. Osteitis pubis in athletes. *Curr Sports Med Rep* 2012;11:96–8. [\[CrossRef\]](#)
3. Angoules AG. Osteitis pubis in elite athletes: Diagnostic and therapeutic approach. *World J Orthop* 2015;6:672–9.
4. Fricker PA, Taunton JE, Ammann W. Osteitis pubis in athletes. Infection, inflammation or injury? *Sports Med* 1991;12:266–79. [\[CrossRef\]](#)
5. Johnson R. Osteitis pubis. *Curr Sports Med Rep* 2003;2:98–102. [\[CrossRef\]](#)
6. Lynch TS, Bedi A, Larson CM. Athletic hip injuries. *J Am Acad Orthop Surg* 2017;25:269–79. [\[CrossRef\]](#)
7. Ekstrand J, Ringborg S. Surgery versus conservative treatment in soccer players with chronic groin pain: A prospective randomised study in soccer players. *Eur J Sports Traumatol Relat Res* 2001;23:141–5.
8. Williams PR, Thomas DP, Downes EM. Osteitis pubis and instability of the pubic symphysis. When nonoperative measures fail. *Am J Sports Med* 2000;28:350–5. [\[CrossRef\]](#)
9. Topol GA, Reeves KD, Hassanein KM. Efficacy of dextrose prolotherapy in elite male kicking-sport athletes with chronic groin pain. *Arch Phys Med Rehabil* 2005;86:697–702. [\[CrossRef\]](#)
10. Choi H, McCartney M, Best TM. Treatment of osteitis pubis and osteomyelitis of the pubic symphysis in athletes: A systematic review. *Br J Sports Med* 2011;45:57–64. [\[CrossRef\]](#)
11. Morelli V, Smith V. Groin injuries in athletes. *Am Fam Physician* 2001;64:1405–14.
12. Degheili JA, Mansour MM, Nasr RW. Symphysis pubis osteomyelitis: An uncommon complication after robotic assisted radical prostatectomy—case description with literature review. *Case Rep Urol* 2018;2018:5648970. [\[CrossRef\]](#)
13. Elattar O, Choi HR, Dills VD, Busconi B. Groin injuries (athletic pubalgia) and return to play. *Sports Health* 2016;8:313–23. [\[CrossRef\]](#)
14. Henning PT. The running athlete: Stress fractures, osteitis pubis, and snapping hips. *Sports Health* 2014;6:122–7. [\[CrossRef\]](#)
15. Via AG, Frizziero A, Finotti P, Oliva F, Randelli F, Maffulli N. Management of osteitis pubis in athletes: Rehabilitation and return to training - A review of the most recent literature. *Open Access J Sports Med* 2018;10:1–10. [\[CrossRef\]](#)
16. Holt MA, Keene JS, Graf BK, Helwig DC. Treatment of osteitis pubis in athletes. Results of corticosteroid injections. *Am J Sports Med* 1995;23:601–6. [\[CrossRef\]](#)
17. Volpi P. Football traumatology – Current concepts: From prevention to treatment. 1st ed. Milano: Springer; 2006.
18. Hechtman KS, Zvijac JE, Popkin CA, Zych GA, Botto-van Bemden A. A minimally disruptive surgical technique for the treatment of osteitis pubis in athletes. *Sports Health* 2010;2:211–5. [\[CrossRef\]](#)
19. Gupta A, Redmond JM, Hammarstedt JE, Suarez-Ahedo C, Martin TJ, Matsuda DK, et al. Endoscopic pubic symphysectomy for recalcitrant osteitis pubis. *Arthrosc Tech* 2015;4:e115–7. [\[CrossRef\]](#)
20. O’Connell MJ, Powell T, McCaffrey NM, O’Connell D, Eustace SJ. Symphyseal cleft injection in the diagnosis and treatment of osteitis pubis in athletes. *AJR Am J Roentgenol* 2002;179:955–9. [\[CrossRef\]](#)