

“Figure of four” position and long-axis sciatic nerve scan with ultrasound facilitates sciatic perineural catheter placement

“Dört pozisyonu” ve ultrasonografi ile uzun aks siyatik sinir görüntüsü siyatik perinöral kateter yerleşimini kolaylaştırır

Levent ŞAHİN,¹ Yavuz GÜRKAN²



Summary

Continuous plexus and peripheral nerve blocks offer the potential benefits of prolonged analgesia and faster functional recovery after surgery in pediatric patients. We report the feasibility of a new patient position and long-axis nerve scan with ultrasound (US) for controlling perineural catheter placement for continuous mid-femoral sciatic nerve block in a pediatric case. We think that long-axis view of the sciatic nerve with US during placement of perineural catheters in a child is an effective technique.

Key words: Catheter; sciatic nerve; long axis.

Özet

Pediyatrik hastalarda cerrahi sonrası devamlı pleksus ve periferik sinir blokları daha hızlı fonksiyonel iyileşme ve uzamış analjezi için faydalıdır. Biz bir pediyatrik olguda devamlı mid-femoral siyatik sinir bloğu için kontrollü perinöral kateter yerleştirilmesini, yeni bir hasta pozisyonu ve uzun aks ultrasonografi görüntüsü ile uygulanabileceğini rapor ettik. Biz çocukta perinöral kateter yerleştirilmesi sırasında ultrasonografi ile siyatik sinirin uzun aks görüntüsünün etkili bir teknik olduğunu düşünüyoruz.

Anahtar sözcükler: Kateter; siyatik sinir; uzun aks.

Introduction

Postoperative analgesia is generally limited to less than 24 hours after single-injection regional nerve blocks. Continuous peripheral nerve blocks (CPNBs) provide sustained limb-specific analgesia beyond the duration of single-injection peripheral nerve blocks. Continuous plexus and peripheral nerve blocks offer the potential benefits of prolonged analgesia and faster functional recovery after surgery in pediatric patients. Direct visualization of nerves

and surrounding structures may improve the quality and success rate of nerve blocks and avoid complications. US allows visualization of in plane needle insertion toward a nerve and the perineural spread of local anesthetic (LA) solution. However, advancement and final positioning of perineural catheters is difficult to visualize. Unfortunately no controlled study associated with CPNB is available in the literature and there are only case reports in pediatrics currently.

¹Department of Anesthesiology and Reanimation, Gaziantep University Faculty of Medicine, Gaziantep;

²Department of Anesthesiology and Reanimation, Kocaeli University Faculty of Medicine, Kocaeli, Turkey

¹Gaziantep Üniversitesi Tıp Fakültesi, Anesteziyoloji ve Reanimasyon Anabilim Dalı, Gaziantep

²Kocaeli Üniversitesi Tıp Fakültesi, Anesteziyoloji ve Reanimasyon Anabilim Dalı, Kocaeli

Submitted - July 14, 2010 (Başvuru tarihi - 14 Temmuz 2010) Accepted after revision - August 16, 2010 (Düzeltilme sonrası kabul tarihi - 16 Ağustos 2010)

Correspondence (İletişim): Levent Şahin, M.D. Gaziantep Üniversitesi Tıp Fakültesi Hastanesi Anesteziyoloji ve Reanimasyon Kliniği, Ameliyathane, 27310 Gaziantep, Turkey.

Tel: +90 - 342 - 360 60 60 / 7950 **Fax (Faks):** +90 - 342 - 360 22 44 **e-mail (e-posta):** drlsahin@hotmail.com

We reported the feasibility a new patient position and long axis nerve scan with US for controlling perineural catheter placement for continuous mid-femoral sciatic nerve blocks in a pediatric case.

Case Report

An ASA physical status I, ten years old female patient, weighing 22 kg, height 134 cm, undergoing left foot surgery for pes equinovarus sequel under general anesthesia and continuous sciatic nerve block for postoperative pain relief. The patient was premedicated with midazolam 2 mg intravenous (i.v.) before induction of anesthesia and propofol 2 mg.kg⁻¹ and fentanyl 1 µg.kg⁻¹ were administered i.v. to facilitate laryngeal mask airway insertion. Anesthesia was then maintained with sevoflurane concentration 1.5%–2% in N₂O and oxygen (2:1 ratio). For the mid-femoral approach to the sciatic nerve, the child was positioned in “figure of four” in prone position (Fig. 1). “Figure of four” (FOF) position was described by Gurkan et al.^[1] as the leg to be examined is flexed and abducted to allow the foot to rest on the ankle of the contralateral leg on roller. After disinfection and sterile draping, sterile gel was applied to the procedure area. A linear 10-18 MHz ultrasound transducer (Esaote Mylab30, Florence, Italy) was placed transverse plane to popliteal fossa. After the sciatic nerve was viewed, transducer was aligned slowly toward proximal thigh until mid-

femoral region. In this region transducer was rotated 90 degrees to obtain long axis view without loss of image. An 18-gauge 50 mm insulated CPNB needle (PlexoLong Nanoline Pajunk, Geisingen, Germany) was inserted tangentially to the nerve and the correct tip position was confirmed with seen dorsiflexion by neurostimulator 0.5 mA with pulse duration of 0.1 ms and visually by 2 ml of LA injection. Finally catheter was inserted under the transducer’s long plane and advanced 3 cm into the desired perineural position. LA (10 ml 0.5% levobupivacaine) was then injected through the catheter and the spread was confirmed both on long axis and short axis scans (Fig. 2a, b). In operation lateral colon extending, peroneal tendon extending and Grice-Green surgeries were performed by surgeons. Postoperative analgesia was administered using a patient controlled analgesia (PCA) infusion with levobupivacaine 0.5% at a bolus dose of 4 ml, lock out time 30 min, and limit of 4 hours 20 ml (Abbott Pain. Manager, Chicago, IL, USA). Forty-eight hours after surgery, the catheter was removed without problem and started oral analgesics. She was very pleased with CPNB of sciatic nerve because of pain free postoperative period and discharged 4 days after the surgery.

Discussion

We reported a catheter placement for continue mid-femoral sciatic nerve block with US guidance at

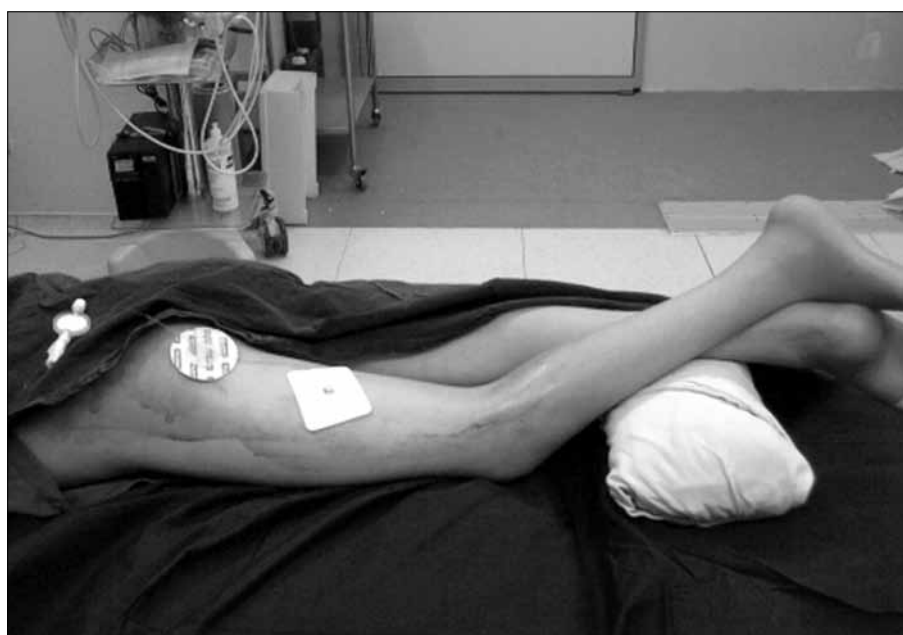

Fig. 1. “Figure of four” position and fixed catheter.

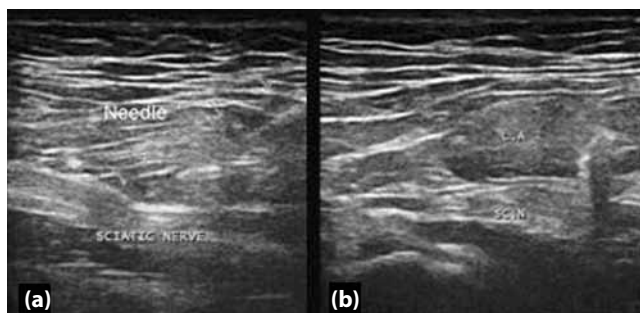


Fig. 2. (a) Needle and sciatic nerve at long axis plane. (b) Local anesthetic and sciatic nerve at short axis plane.

long axis nerve scan in a child. We applied two new approaches present in the literature. One of them is "FOF" patient position described by Gurkan et al.^[1] and the other one is catheter placement at long axis nerve scan described by Koscielniak-Nielsen et al.^[2]

The potential benefits of utilizing US for continuous peripheral nerve blocks include the ability to directly visualize the neural and perineural anatomy, especially in the setting of normal anatomical variations and in cases where conventional nerve stimulation guided techniques may not be feasible. US for peripheral nerve blocks has been shown to improve the efficiency of single-injection peripheral nerve blocks by decreasing the procedural time, the number of needle passes, and the onset time of the sensory blockade as well as increasing the overall success rate. Theoretically, US has the potential to confirm catheter tip location (direct visualization of the catheter tip or indirectly by visualizing LA spread).^[3]

Infants and children have larger total body water content than adults, which gives their tissue a unique ultrasonographic characteristic. Moreover, because of the superficial location of most nerves in children, the nerves to be targeted are readily visualized and excellent ultrasound images can be obtained.^[4] Subgluteal and popliteal approaches are commonly used for sciatic nerve blockade in children. We preferred mid-femoral approach to sciatic nerve for placement catheter and "FOF" position under general anesthesia. We think that FOF position is an appropriate

approach for placement of perineural catheter to sciatic nerve with US guidance because this position diminishes strain of sciatic nerve.

The sciatic nerve appears predominantly hyperechoic and is often elliptical in a short-axis view. The probe is typically used to view the nerves in short-axis (cross-sectional, transversely), but occasionally a long-axis (longitudinal) view is helpful to nerve blocks.^[5] We believe that patient position is as important as the axis of the studied nerves for placement of perineural catheter.

Koscielniak-Nielsen et al.^[2] first used long-axis views of the nerves with US during placement of perineural catheters in two children (mid-femoral sciatic and popliteal blocks). They were able to view the rigid epidural catheter exiting the needle tip and during advancement while using long-axis views of the nerves. The authors observed that the catheters were positioned properly with the help of to-and-fro movements and the rotation of the Tuohy needle and viewing the tip of a catheter, rather than some cross-sectional point, will require some surrogate marking (movement or fluid injection). We experienced that long-axis view of the sciatic nerve with US during placement of perineural catheters in a child a more effective technique than short-axis view according to our experiences previously.

References

1. Gürkan Y, Sarisoy HT, Çağlayan C, Solak M, Toker K. "Figure of four" position improves the visibility of the sciatic nerve in the popliteal fossa. *Agri* 2009;21(4):149-54.
2. Koscielniak-Nielsen ZJ, Rasmussen H, Hesselbjerg L. Long-axis ultrasound imaging of the nerves and advancement of perineural catheters under direct vision: a preliminary report of four cases. *Reg Anesth Pain Med* 2008;33(5):477-82.
3. Capdevila X, Ponrouch M, Choquet O. Continuous peripheral nerve blocks in clinical practice. *Curr Opin Anaesthesiol* 2008;21(5):619-23.
4. Rapp HJ, Grau T. Ultrasound-guided regional anesthesia in pediatric patients. *Tech Reg Anesth Pain Manage* 2004;8:179-98.
5. Tsui BC, Suresh S. Ultrasound imaging for regional anesthesia in infants, children, and adolescents: a review of current literature and its application in the practice of neuraxial blocks. *Anesthesiology* 2010;112(3):719-28.