



CASE REPORT

Intravenous methylprednisolone as a transition treatment in red ear syndrome: A case report

Kırmızı kulak sendromunun geçiş tedavisinde intravenöz metilprednizolon: Bir olgu sunumu

Serdar KOKAR,^{1*} Uğur UYGUNOĞLU²

Summary

Red ear syndrome (RES) is a rare condition of unknown etiology characterized by episodic attacks of unilateral ear pain, redness, and burning sensation. A 31-year-old male patient was admitted to our clinic with a severe headache reaching up to 5 h, presenting with short bursts of electric shock-like sensation, burning, and tingling in the left side of his face. The patient was unresponsive to previous medical treatments. Lidocaine 10% through the intranasal route for sphenopalatine ganglion and stellate ganglion blockade under the guidance of fluoroscopy also failed. Given that the Red-Ear syndrome shares similar pathophysiological pathways with trigeminal autonomic cephalalgias, the patient was treated with high-dose intravenous methylprednisolone, and since then, he has been symptom-free for 6 months. High-dose steroid therapy might be a good alternative in late-onset RES as a transition treatment.

Keywords: Facial pain; headache disorders; sphenopalatine ganglion; stellate ganglion; steroid.

Özet

Kırmızı kulak sendromu; epizodik tek taraflı kulak ağrısı, kızarıklık ve yanma hissi ile karakterize, etyolojisi tam olarak bilinmeyen nadir bir bozukluktur. Otuz bir yaşındaki erkek hasta sol yüz yarımında yanma, karıncalanma ve elektrik çarpması şeklinde ortaya çıkan ve beş saate kadar uzayabilen baş ağrısı şikayeti ile kliniğimize başvurdu. Önceki medikal tedavilere yanıt vermemiş olan hastaya intranasal yolla lidokain %10 ve floroskopi rehberliğinde stellat ganglion blokajı tedavileri sırasıyla uygulandı. Hasta bahsi geçen girişimsel ağrı tedavilerine de yanıt vermedi. Kırmızı kulak sendromunun trigeminal otonomik sefaljilerle benzer patofizyolojik özellikleri paylaştığı görüşünden yola çıkarak, hasta yüksek doz intravenöz metilprednizolon ile tedavi edildi ve takip eden altı ay süresince ağrısız olarak izlendi. Geç başlangıçlı kırmızı kulak sendromunun geçiş tedavisinde, yüksek doz steroidler iyi birer alternatif olarak değerlendirilebilir.

Anahtar sözcükler: Baş ağrısı; yüz ağrısı; steroid; stellat ganglion; sfenopalatin ganglion.

Introduction

Red ear syndrome (RES), a rare condition of unknown etiology, was first described by Lance in 1994.^[1] It is characterized by episodic attacks of unilateral ear pain, redness, and burning sensation.^[2] These episodes can occur spontaneously or be induced by heat or cold, hair brushing, tooth brushing, touching, neck movements, or exertion.^[3] RES can be idiopathic, presenting as a symptom in primary headaches, or it may develop as a part of a syndrome, secondary to headache dis-

orders. Additionally, in some patients, it has been reported that it accompanies primary headache disorders, but it presents with separate attacks independent of these primary headaches.^[4] In light of these data, there is no single treatment for RES due to its causal and distinct pathophysiological processes.

In this article, we report a case of RES treated with different treatment modalities in the light of the literature data.

*The current affiliation of the author: Division of Pain Management, Department of Physical Medicine and Rehabilitation, Marmara University Faculty of Medicine, İstanbul, Türkiye

¹Department of Algology, Şanlıurfa Training and Research Hospital, Şanlıurfa, Türkiye

²Department of Neurology, İstanbul University-Cerrahpaşa, Cerrahpaşa Faculty of Medicine, İstanbul, Türkiye

Submitted (Başvuru) 03.03.2021 Revised (Revizyon) 30.03.2021 Accepted (Kabul) 12.04.2021 Available online (Online yayımlanma) 16.10.2023

Correspondence: Dr. Serdar Kokar. Şanlıurfa Eğitim ve Araştırma Hastanesi, Algoloji Kliniği, Şanlıurfa, Türkiye.

Phone: +90 - 541 - 641 51 43 **e-mail:** srdrkkrr@hotmail.com

© 2023 Turkish Society of Algology

Case Report

A 31-year-old male patient was admitted to our outpatient clinic with a severe headache in February 2019. His medical history revealed headaches for about 8 years characterized by short bursts of electric shock-like sensation, burning, and tingling with a pain sensation in the left side of his face up to one minute. He was diagnosed elsewhere with trigeminal neuralgia and initiated carbamazepine. However, the patient could not tolerate treatment, and experienced sedation and dizziness. Gabapentin was then titrated in increments of 300 mg to 1,800 mg dose. Subsequently, amitriptyline 25 mg daily and duloxetine 60 mg daily doses were initiated, respectively. Although he used these treatments alternately for 2 years, no significant benefit could be achieved. At the end of 2 years, he experienced a different course of pain with reduced short bursts of electric shock-like sensation. However, a burning sensation increased, and redness on the face and left ear was observed. The pain was unilateral in nature, affecting the left side of the face. Indomethacin and levetiracetam had been started elsewhere; however, no response to treatment was achieved.

At the time of his admission to our clinic, he had complaints of burning sensation and redness on his face and left ear, nasal congestion, lacrimation, and rarely nausea (Fig. 1). He had no aura symptoms or photophobia, phonophobia, osmophobia, or ptosis. He reported a prolonged duration of episodes of severe headache for the last couple of years, reaching up to 7–8 h. The shortest duration of an episode was about 1 h and sometimes increased up to 12 h. The episodes of headache persisted for the whole year and became more severe in the winter season. According to the Numeric Rating Scale (NRS), the pain severity score was 4–5 in the summer and 9–10 in the winter season, indicating more severe pain. His medical history was unremarkable, except for type 1 diabetes. The patient previously underwent magnetic resonance imaging and magnetic resonance angiography for more than 10 times. These scans were retrospectively analyzed, and no abnormal findings were observed. Trigeminal somatosensory evoked potentials and eye-blink reflex responses were bilaterally symmetric and within normal ranges. Based on physi-

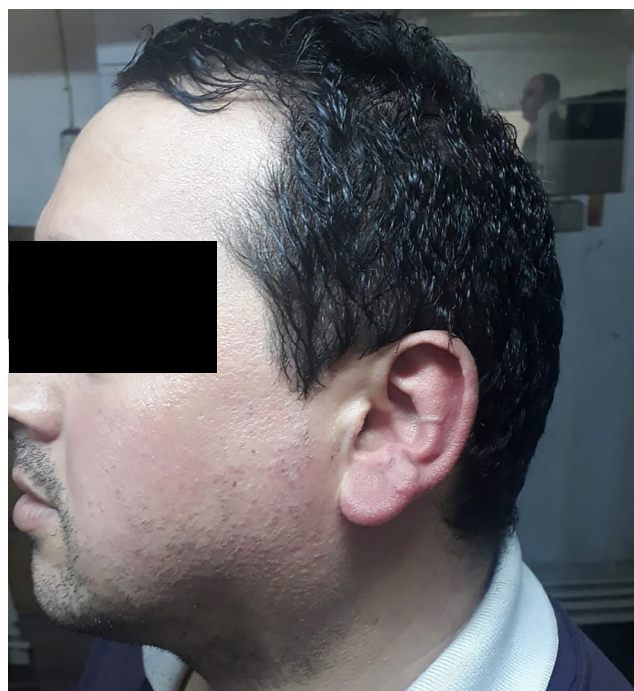

Figure 1. Redness on the face and left ear.

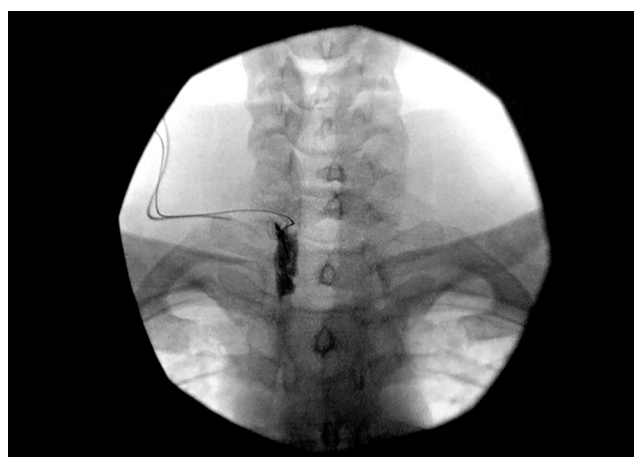


Figure 2. Stellate ganglion block with contrast spread.

cal examination and imaging modality findings, he was diagnosed with RES. As he was unresponsive to previous oral medical treatment, lidocaine 10% was administered through the intranasal route for sphenopalatine ganglion (SPG), considering autonomic findings.^[5] However, analgesia could not be achieved and therefore, stellate ganglion blockade was performed under the guidance of fluoroscopy, as described previously (Fig. 2).^[6] After the procedure, Horner syndrome developed with an increased body temperature, indicating that the procedure was successful.^[7] At 1 h of the procedure, no symptomatic relief was achieved. The patient had no procedure-related complications and was discharged with scheduled hospitalization for pulse steroid therapy at a later date.

One week after the stellate ganglion blockade, the patient was hospitalized. He had persistent complaints, including redness in the face and ears with a burning sensation. According to the NRS, the pain severity score was 10/10. Treatment with intravenous methylprednisolone (IVMP) 500 mg/day was initiated for 3 days. On Day 3, the NRS pain severity score decreased to 2/10 with reduced burning sensation and face and ear redness. Given the fact that RES and trigeminal autonomous cephalalgias (TACs) potentially share a similar pathophysiology, verapamil 80 mg P.O. 3 times daily was initiated, and the patient was uneventfully discharged.

The patient was scheduled for follow-up visits at 1 week, 1, 3, and 6 months, and pain control was achieved. According to the NRS, the pain severity score was 2, 2, 3, and 5, respectively, without any autonomic signs and symptoms.

A written informed consent was obtained from the patient for all the diagnostic and therapeutic procedures.

Discussion

Although the exact pathophysiology of RES still remains to be elucidated, objective signs and symptoms such as red ears and dysesthesia during painful episodes rule out a subjective diagnosis. In the majority of cases, a burning sensation is present, which suggests that RES should be considered a distinct headache disorder. However, RES has not been included as a distinct entity in the third edition of the International Classification of Headache Disorders.^[8] This can be attributed to the fact that proposed pathophysiological mechanisms and treatment options are still controversial. In the present case, no response to previous medical treatments could be achieved and, therefore, we used different modalities and achieved successful results. We believe that this case report provides additional information to the body of knowledge on this topic.

In the literature, early-onset RES has been shown to be associated with migraine, while late-onset RES has been associated with TACs.^[9,10] In our case, late-onset RES can be considered, and the absence of photophobia, phonophobia, osmo-

phobia, or ptosis and the presence of autonomic signs and symptoms support this opinion. Furthermore, our patient did not benefit much from medicines used in the treatment of migraines, while he responded well to steroids and verapamil, which are used in the treatment of cluster headache (CH). Nonetheless, it is still controversial whether RES is a distinct entity from TAC or an extension of TAC.

In our case, an effective temporary analgesia could not be achieved through SPG block, which seems to be a controversy. However, this can be partly explained by the fact that some parts of the ear are innervated by the greater auricular nerve, which branches from the third cervical spinal nerve.^[9] It should also be kept in mind that the SPG block has no high level of recommendation in TACs and mostly case reports exist in the literature.

In a case series, it was reported that pulse IVMP at a dose of 250–500 mg per infusion was used in the treatment of CH, and patients benefited from this treatment.^[11] Similarly, Cianchetti et al.^[12] reported that a patient with CH whose pain did not decrease with prednisone 100 mg daily for 2 weeks benefited from 500 mg IVMP. Based on our own clinical experience and these supportive views, we used high-dose IVMP as a transition treatment for our patient. We obtained an effective treatment response due to the possible common pathophysiology.^[13]

Conclusion

In conclusion, high-dose steroid therapy for episodic attacks of late-onset RES and prophylactic verapamil yields satisfactory results. Since our patient did not respond to previous conservative and interventional treatments, it is valuable to report this case of RES. However, further studies are warranted to gain a better understanding of the pathophysiology of RES and to establish the optimal treatment.

Informed Consent: *Written informed consent was obtained from the patient who participated in this study.*

Conflict-of-interest issues regarding the authorship or article: *None declared.*

Peer-review: *Externally peer-reviewed.*

References

1. Lance JW. The mystery of one red ear. *Clin Exp Neurol* 1994;31:13–8.
2. Raieli V, D'Amelio M, Brighina F. The mystery of "Red Ear Syndrome": Sign or Syndrome. *Headache* 2019;59:624–5.
3. Boulton P, Purdy RA, Bosch EP, Dodick DW. Primary and secondary red ear syndrome: Implications for treatment. *Cephalalgia* 2007;27:107–10. [\[CrossRef\]](#)
4. Raieli V, Compagno A, D'Amelio M. Red ear syndrome. *Curr Pain Headache Rep* 2016;20:19. [\[CrossRef\]](#)
5. Piagkou M, Demesticha T, Troupis T, Vlasis K, Skandalakis P, Makri A, et al. The pterygopalatine ganglion and its role in various pain syndromes: From anatomy to clinical practice. *Pain Pract* 2012;12:399–12. [\[CrossRef\]](#)
6. Rathmell JP. *Atlas of image-guided intervention in regional anesthesia and pain medicine*. 2nd ed. Philadelphia: Lippincott Williams & Wilkins; 2011.
7. Gunduz OH, Kenis-Coskun O. Ganglion blocks as a treatment of pain: Current perspectives. *J Pain Res* 2017;10:2815–26. [\[CrossRef\]](#)
8. Headache Classification Committee of the International Headache Society (IHS) *The International Classification of Headache Disorders*, 3rd edition. *Cephalalgia* 2018;38:1–211. [\[CrossRef\]](#)
9. Evans RW, Lance JW. The red ear syndrome: An auriculo-autonomic cephalgia. *Headache* 2004;44:835–6. [\[CrossRef\]](#)
10. Uca AU, Kozak HH. Coexistence of migraine headache and red ear syndrome. *Noro Psikiyatrs Ars* 2014;51:294.
11. Kawada S, Kashihara K, Imamura T, Ohno M. High-dose intravenous methylprednisolone for the prophylactic treatment of cluster headache. *Springerplus* 2013;2:156. [\[CrossRef\]](#)
12. Cianchetti C, Zuddas A, Marchei F. High dose intravenous methylprednisolone in cluster headache. *J Neurol Neurosurg Psychiatry* 1998;64:418. [\[CrossRef\]](#)
13. Antonaci F, Costa A, Candeloro E, Sjaastad O, Nappi G. Single high-dose steroid treatment in episodic cluster headache. *Cephalalgia* 2005;25:290–5. [\[CrossRef\]](#)