



CASE REPORT / OLGU SUNUMU

Awake hand surgery under ultrasound-guided infraclavicular block is possible for cooperative children

Kooperere çocuklarda ultrason rehberliğinde infraklavikular blok ile uyanık el cerrahisi mümkündür

Hülya YANAL, Yavuz GÜRKAN, Alparslan KUŞ, Onur BALABAN, Mine SOLAK, Kamil TOKER

Summary

In recent years, brachial plexus anesthesia techniques for upper limb surgery have been used more and more commonly on children; however, the patient is typically under deep sedation or general anesthesia. For eligible, cooperative children, surgery can also be performed using regional blocks while the patient is awake. We present 5 cases in which Ultrasound (US)-guided infraclavicular brachial plexus blocks (ICB) were used on children for hand or forearm surgery. Surgical anesthesia was achieved in all patients and surgery was completed uneventfully using brachial plexus anesthesia, without need for deep sedation.

Keywords: Children; infraclavicular block; ultrasound guided.

Özet

Son yıllarda, brakial pleksus anestezi teknikleri çocukların üst ekstremitte cerrahisinde daha sık kullanılmaktadır. Rejyonal bloklar ile kooperasyon kurulabilen çocuklarda sedasyon eşliğinde cerrahi uygulanabilmektedir. Bu yazıda, ultrason (US) rehberliğinde infraklavikular blok ile el ve ön kol cerrahisi geçiren uyanık beş olgu sunuldu. Tüm hastalarda cerrahi anestezi sağlandı ve cerrahi sadece brakial pleksus anestezisi ile tamamlandı. Sonuç olarak, US rehberliğinde brakial pleksus anestezişinin uygun çocuk hastalarda genel anestezi olmaksızın ameliyat için başarılı bir anestezi sağlayabileceğini düşünüyoruz.

Anahtar sözcükler: Çocuklar; infraklavikular blok; ultrason rehberliği.

Introduction

Brachial plexus anesthesia techniques for upper limb surgery have been used more and more commonly on children in recent years.^[1,2] Ultrasound (US) guidance improved the quality and success rate of nerve blocks, and reduced the incidence of complications.^[3–7]

Most pediatric regional blocks are performed under general anesthesia or deep sedation where signs of block failure or complications cannot be immediately recognized. Yet in cooperative children, surgery can also be performed using regional blocks while

the child is awake. There are few case reports about surgery on children under regional anesthesia. This article is a report of use of US-guided infraclavicular brachial plexus blocks (ICB) on 5 awake children.

Case Report

Presented are 5 cases in which US-guided ICB were performed on awake children for hand or forearm surgery. Routine preoperative assessment was done for all patients. Patients and families were informed about the procedure and their consent was obtained before surgery.

Department of Anesthesiology and Reanimation, Kocaeli University Faculty of Medicine, Kocaeli, Turkey

Submitted (Başvuru tarihi) 02.03.2014 Accepted after revision (Düzeltilme sonrası kabul tarihi) 24.07.2015

Correspondence (İletişim): Dr. Alparslan Kuş, Kocaeli Üniversitesi Tıp Fakültesi, Anesteziyoloji ve Reanimasyon Anabilim Dalı, Kocaeli, Turkey.

Tel: +90 - 262 - 303 75 75 e-mail (e-posta): alparslankus@gmail.com

© 2016 Türk Algoloji Derneği

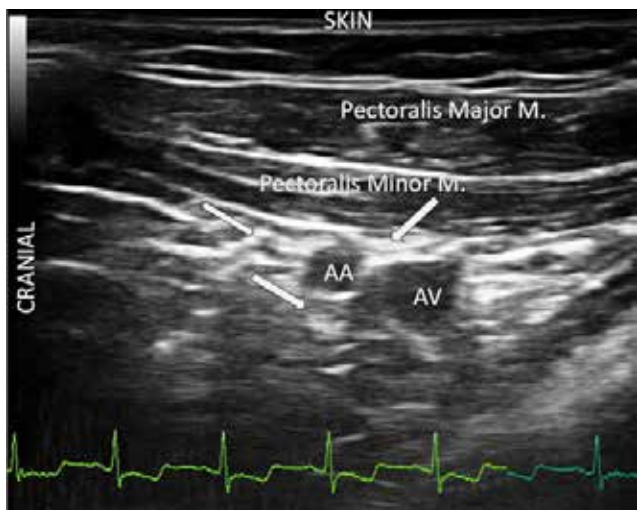

Fig. 1. Cords of the brachial plexus appear hyper-echoic. Arrows indicate lateral, posterior, and medial cords. AA: Axillary artery; AV: Axillary vein.

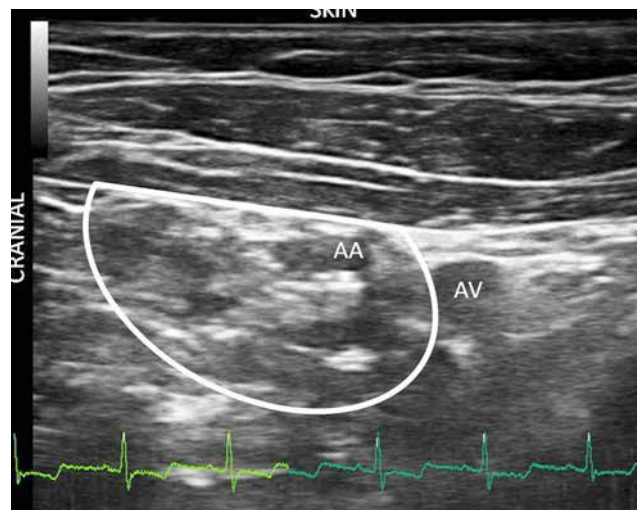


Fig. 2. White line indicates diffusion of local anesthetic around artery and cords. AA: Axillary artery; AV: Axillary vein.

Prerequisites for using awake block included cooperation of the child and insertion of venous cannula in non-injured hand before block technique was applied.

On arrival to pre-anesthesia waiting area where block was performed, standard monitoring was conducted (electrocardiogram, pulse oximetry and non-invasive blood pressure). All patients received midazolam 0.05–0.1 mg kg⁻¹ intravenously for sedation and infusion of Ringer’s lactate was initiated before block was performed.

Patients were placed in supine position with relaxed shoulders. The arm to be blocked was adducted and hand placed on abdomen. Head was rotated to contralateral side. The point where clavicle meets coracoid process was palpated. Puncture site was immediately adjacent to most medial point of coracoid process and anterior surface of clavicle. Because skin puncture was the most painful part of the process, after antiseptic preparation of the

area, we infiltrated subcutaneous tissue with 0.5 mL of lidocaine 1%. US probe was placed just below clavicle inferior to site of needle entry. Esaote My Lab 30 US system (Florence, Italy) with wide bandwidth, multi-frequency linear probe (8–18 MHz) was used while performing the block. A 5 cm sonovisible nerve block needle (Pajunk, Geisingen, Germany) was inserted using in-plane technique. Following identification of axillary artery and cords needle was advanced posterior to axillary artery. Mixture of levobupivacaine 0.5% and lidocaine 2% total 0.5 ml.kg⁻¹ was then injected at the site after frequent negative aspiration and distribution of local anesthetic around cords, and axillary artery was confirmed with ultrasound imaging.

Motor block was assessed 30 minutes after block performance. Good block was defined as completely limp hand; block was satisfactory if patient was capable of minor movements of the fingers, and block result was considered poor if there was normal movement.

Table 1. Patient demographics and type of surgery

Case	Gender	Age (year)	Weight (kg)	Surgery	Surgery time (min)
1	Male	5	30	Tendon injury	70
2	Male	12	35	Tendon tm	40
3	Female	6	28	Polydactily	60
4	Male	10	37	Hemangiom removal	45
5	Female	8	32	Tendon injury	90

Blocks were successful in all patients and surgical anesthesia with complete motor block was achieved. Demographic data of patients are presented in Table 1. Duration of surgery ranged from 30 to 90 minutes. Intraoperative sedation was provided with doses of 1 mg midazolam bolus when required. In all cases, surgery was completed uneventfully with brachial plexus block. Following surgical procedure, patients were transferred to recovery room.

Discussion

After a case report published by Bromage and Benumof in 1998 about paraplegia result in an adult patient on whom central block was performed while under general anesthesia, controversy ensued. Many pediatric anesthesiologists believed that general anesthesia or heavy sedation was necessary to ensure maximum safety against potential complications.^[8,9] Pediatric Regional Anesthesia Network (PRAN) reported a preliminary evaluation comparing regional anesthesia in awake, sedated, and anesthetized children that indicated no difference in similar transient complication rates.^[10,11] Mossetti and Ivani^[12] confirmed that pediatric regional anesthesia, when performed following strict guidelines, is at least as safe as general anesthesia.

Although in the majority of cases, blocks are performed to provide analgesia only, if length of surgery is reasonable, cooperative patients can be operated on while awake and without general anesthesia. Once the block is performed, an appropriate level of sedation should be provided during surgery to improve patient tolerance and comfort. Different regimens or drugs can be used to provide intraoperative sedation according to demands of the surgery and patient characteristics.

Some conditions should be satisfied before considering awake surgery under block in children. The most important criterion is that eligible patients for awake surgery under ICB should be cooperative in order to communicate well when evaluating subjective and objective parameters. All patients and parents should be informed about effects of the block and their consent should be obtained. Another prerequisite is presence of venous cannula in non-injured hand before block performance in order to administer sedation, fluid or any other drug necessary.

US allows visualization during ICB of target structures, such as cords of brachial plexus, as well as relevant anatomy (axillary artery and vein, pleura).

In addition, multiple punctures to optimize position of stimulating needle, which increases the overall burden of pain, are eliminated with use of US. Direct visualization of plexus offers shorter sensory onset time, thus decreasing period in which pain is felt.^[3,6] Acute pain caused by nerve stimulator due to muscle contraction is also eliminated with use of US.

Axillary route is still the most commonly used approach in pediatric population due to safety considerations. ICB produces more complete anesthesia with a single injection compared to multiple injection axillary block technique. Another advantage of ICB is that it can be performed in any position, which avoids pain. Due to ease of performance and high success rate, use of ICB on children is gaining popularity. It can be performed with a single needle insertion, which makes the technique more acceptable for the child. The technique is easy to perform due to distinct landmarks, and can be performed in awake children under sedation.^[2,7,13]

Most case reports and studies on pediatric patients have shown that ICB can be performed successfully in children under general anesthesia. There are not many reports about awake surgery under brachial plexus anesthesia on children. Vanessa et al.^[13] placed an ultrasound-guided infraclavicular brachial plexus catheter in a 9-year-old child without any sedation; only 1% lidocaine was used for skin infiltration.

Marhofer^[7] performed ICB on 40 children under midazolam sedation. Low doses of propofol were given to 24 of the children who were younger. It is the opinion of the authors that in many cooperative children midazolam sedation alone is enough to perform ICB. In cases where immobility is required during needle puncture, a small dose of propofol may be sufficient.

In conclusion, successful surgical anesthesia can be obtained with US-guided ICB in eligible pediatric patients under sedation without general anesthesia.

Conflict-of-interest issues regarding the authorship or article: None declared.

Peer-review: Externally peer-reviewed.

References

1. Giaufré E, Dalens B, Gombert A. Epidemiology and morbidity of regional anesthesia in children: a one-year prospective survey of the French-Language Society of Pediatric Anesthesiologists. *Anesth Analg* 1996;83(5):904–12. [Crossref](#)
2. Gürkan Y, Ozdamar D, Solak M, Toker K. Lateral sagittal infraclavicular block is a clinically effective block in children. *Eur J Anaesthesiol* 2008;25(11):949–51. [Crossref](#)
3. Gürkan Y, Acar S, Solak M, Toker K. Comparison of nerve stimulation vs. ultrasound-guided lateral sagittal infraclavicular block. *Acta Anaesthesiol Scand* 2008;52(6):851–5. [Crossref](#)
4. Koscielniak-Nielsen ZJ. Ultrasound-guided peripheral nerve blocks: what are the benefits? *Acta Anaesthesiol Scand* 2008;52(6):727–37. [Crossref](#)
5. Antonakakis JG, Ting PH, Sites B. Ultrasound-guided regional anesthesia for peripheral nerve blocks: an evidence-based outcome review. *Anesthesiol Clin* 2011;29(2):179–91. [Crossref](#)
6. Marhofer P, Schrögender K, Koinig H, Kapral S, Weinstabl C, Mayer N. Ultrasonographic guidance improves sensory block and onset time of three-in-one blocks. *Anesth Analg* 1997;85(4):854–7. [Crossref](#)
7. Marhofer P, Sitzwohl C, Greher M, Kapral S. Ultrasound guidance for infraclavicular brachial plexus anaesthesia in children. *Anaesthesia* 2004;59(7):642–6. [Crossref](#)
8. Bernardis CM, Hadzic A, Suresh S, Neal JM. Regional anesthesia in anesthetized or heavily sedated patients. *Reg Anesth Pain Med* 2008;33(5):449–60. [Crossref](#)
9. Mossetti V, Ivani G. Controversial issues in pediatric regional anesthesia. *Paediatr Anaesth* 2012;22(1):109–14. [Crossref](#)
10. Polaner DM, Martin LD; PRAN Investigators. Quality assurance and improvement: the Pediatric Regional Anesthesia Network. *Paediatr Anaesth* 2012;22(1):115–9. [Crossref](#)
11. Taenzer A, Bosenberg A, Krane E, Martin L, Polaner D, Suresh S, et al. Asleep versus sedated versus awake. Regional block complications by patient state at the time of the block. A report from the pediatric regional anaesthesia network. *Society of Pediatric Anaesthesia* 2011:S83.
12. Mossetti V, Ivani G. Controversial issues in pediatric regional anesthesia. *Paediatr Anaesth* 2012;22(1):109–14. [Crossref](#)
13. Loland VJ, Ilfeld BM, Abrams RA, Mariano ER. Ultrasound-guided perineural catheter and local anesthetic infusion in the perioperative management of pediatric limb salvage: a case report. *Paediatr Anaesth* 2009;19(9):905–7. [Crossref](#)