



## CASE REPORT

# Ultrasound-guided greater auricular nerve block for surgical anesthesia of the external ear

## *Kulak cerrahisinde ultrason rehberliğinde auricularis magnus sinir bloğu*

Mete MANİCİ,<sup>1</sup> İlayda KALYONCU,<sup>1</sup> Hüseyin ERDOĞAN,<sup>1</sup> Muzaffer Ozan ALTUNTAŞ,<sup>2</sup> Yavuz GÜRKAN<sup>1</sup>

### Summary

The Greater Auricular Nerve (GAN), a branch of the cervical plexus, is used to provide anesthesia or pain relief in the ear and neck region. This case report details the use of a GAN block in a 71-year-old male patient with basal cell carcinoma on his right auricular helix. Due to multiple comorbidities (myocardial infarction resulting in a cardiac stent, hypertension), regional anesthesia was preferred. We aim to share our experience with the GAN block for ear surgery.

Keywords: External ear surgery; GAN block; greater auricular nerve.

### Özet

Bu olgu raporunda, kulak cerrahisi geçirecek olan hastada ultrason eşliğinde Nervus Auricularis Magnus sinir bloğu deneyimimizi paylaşmak istedik. Sinir bloğu; 71 yaşında, sağ dış kulakta basal hücreli karsinomu bulunan hastaya uygulandı. Hastanın birçok komorbiditesi vardı (kalpte stent, hipertansiyon gibi). Bu nedenle bölgesel anestezi tercih edildi.

Anahtar sözcükler: Auricularis magnus; dış kulak cerrahisi; GAN blok.

### Introduction

The GAN, a significant sensory branch of the cervical plexus, originates from the C2 and C3 spinal nerves. While cervical plexus blocks have been traditionally used for ear surgery anesthesia, selectively blocking the GAN alone can suffice for external ear procedures.<sup>[1]</sup> The GAN innervates the lower part of the ear, skin over the mastoid process, parotid gland, and angle of the mandible. It is well-suited for local anesthesia.<sup>[2,3]</sup>

### Case Report

A 71-year-old, 83 kg, ASA III male presented with a right auricular skin lesion (Fig. 1). Due to an increased risk of complications from general anesthesia, a selective nerve block was chosen. The patient received 0.05 mg/kg midazolam intravenously in the preoperative area. In the operating room, standard monitors were placed, and a GAN block was performed using a high-frequency (8–18 MHz) lin-

ear probe (GE Logiq S7, General Electric Healthcare, United Kingdom). The probe was positioned transversely at the thyroid cartilage's superior pole and moved along the sternocleidomastoid muscle border to identify the GAN (Fig. 2). A 50 mm 22G block needle (BBraun, Melsungen, Germany) was used for an in-plane approach, with 4 ml of 0.5% bupivacaine injected around the nerve. The block's success was confirmed with a pinprick test. The surgery, lasting 45 minutes, was completed using only the nerve block, without additional analgesics. The patient's hemodynamic parameters remained stable, and he was discharged two hours post-operation, reporting no pain in the recovery area or within the first 24 hours post-surgery.

### Discussion

The ultrasound-guided GAN block, a relatively new technique for surgeries involving the outer

<sup>1</sup>Department of Anesthesiology and Reanimation, Koç University, İstanbul, Türkiye

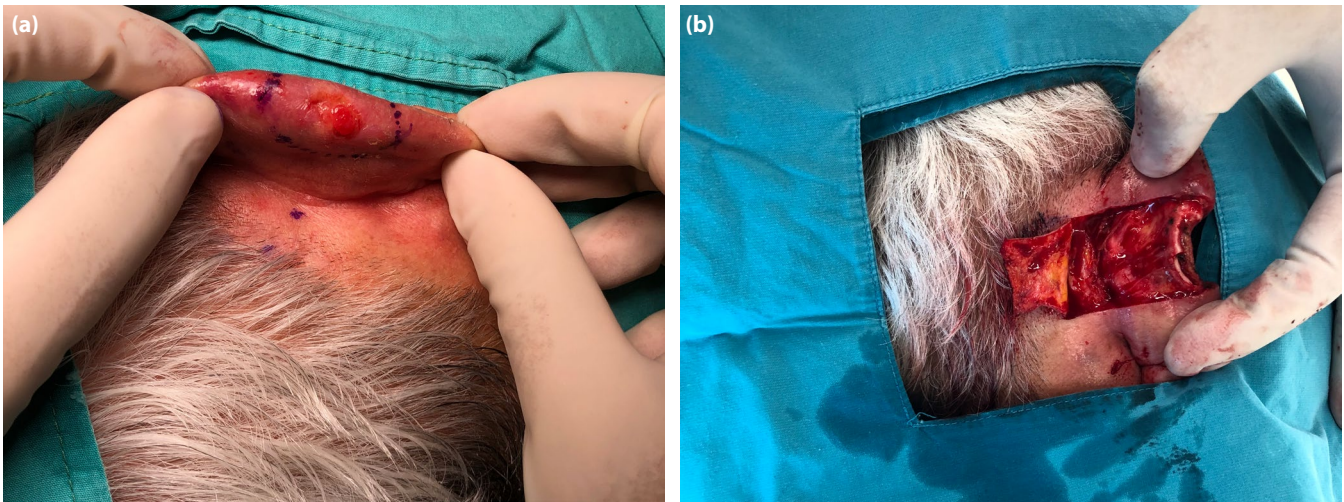
<sup>2</sup>Department of Otolaryngology & Head and Neck Surgery, Koç University, İstanbul, Türkiye

Submitted (Başvuru) 09.12.2021 Revised (Revizyon) 24.01.2022 Accepted (Kabul) 27.01.2022 Available online (Online yayımlanma) 28.12.2023

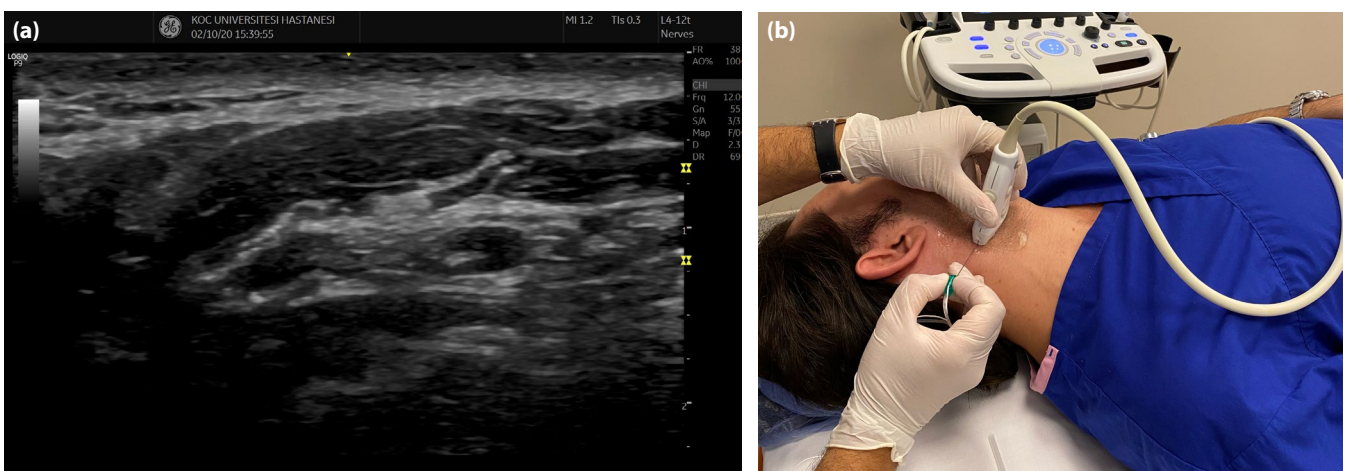
Correspondence: Dr. İlayda Kalyoncu. Koç Üniversitesi Tıp Fakültesi, Anesteziyoloji ve Reanimasyon Anabilim Dalı, İstanbul, Türkiye.

Phone: +90 - 532 - 510 50 14 e-mail: ilaydaakalyoncu@gmail.com

© 2024 Turkish Society of Algology



**Figure 1. (a)** Basal carcinoma located at the helix of right ear. **(b)** Picture showing removed lesion from area.



**Figure 2. (a)** Ultrasound image of GAN block. **(b)** Schematic presentation of GAN block.

ear, mastoid, and mandibular angle, was effectively demonstrated in Thallaj et al.'s<sup>[2]</sup> observational study, which confirmed successful blockade in all 27 volunteers.<sup>[2,4]</sup> Despite its effectiveness, the GAN block remains underutilized. We advocate for its use as a reliable anesthesia technique for external ear surgery, facilitated by high-resolution linear ultrasound probes.

**Conflict-of-interest issues regarding the authorship or article: None declared.**

**Peer-review: Externally peer-reviewed.**

## References

1. Türkyılmaz N, Aksu C, Gürkan Y. Superficial cervical plexus block in ear surgery: A case report. *Agri* [Article in Turkish] 2020;32:106–8.
2. Thallaj A, Marhofer P, Moriggl B, Delvi BM, Kettner SC, Almajed M. Great auricular nerve blockade using high resolution ultrasound: A volunteer study. *Anaesthesia* 2010;65:836–40. [\[CrossRef\]](#)
3. Christ S, Kaviani R, Rindfleisch F, Friederich P. Brief report: Identification of the great auricular nerve by ultrasound imaging and transcutaneous nerve stimulation. *Anesth Analg* 2012;114:1128–30. [\[CrossRef\]](#)
4. Thallaj A. Ultrasound guidance of uncommon nerve blocks. *Saudi J Anaesth* 2011;5:392–4. [\[CrossRef\]](#)