



## REVIEW

# Percutaneous and endoscopic adhesiolysis

## Perkütan ve endoskopik adezyolizis

Hüseyin Utku YILDIRIM,<sup>1</sup> Mert AKBAŞ<sup>2</sup>

### Summary

Low back and leg pain may be due to many causes including scarring in the epidural space. Scar tissue often causes irritated swollen and inflamed nerves, which can cause pain. Adhesiolysis eliminate the pain-causing effects of scar tissue by releasing or decompression of a nerve from scar tissue. Percutaneous adhesiolysis is a safe and effective procedure, while epiduroscopy is a minimally invasive technique that offers diagnostic and therapeutic advantages in cases of chronic low back pain and radiculopathy. The aim of this review is to describe the comparison of percutaneous and endoscopic procedures in the lysis of adhesions in epidural fibrosis in terms of indications, contraindications, complications, technique, and efficacy.

Keywords: Epidural fibrosis; epiduroscopic adhesiolysis; neuroplasty; percutaneous adhesiolysis; scar tissue.

### Öz

Bel ve bacak ağrısı epidural boşlukta oluşan skar dokusu da dahil olmak üzere birçok sebepten kaynaklanabilir. Skar dokusu sıklıkla hassas, ödemli ve enflamasyonlu sinirlere neden olur ve bu da ağrıya neden olabilir. Epidural adezyolizis, skar dokusundan sinirin serbestlenmesi veya dekompresyonu ile skar dokusunun ağrıya neden olan etkilerini ortadan kaldırır. Perkütan adezyolizis güvenli ve etkili bir prosedür iken, epiduroskopik adezyolizis kronik bel ağrısı ve radikülopati vakalarında tanısıl ve terapötik avantajlar da sunan minimal invaziv bir tekniktir. Bu derlemenin amacı epidural fibroziste adezyolizis yöntemi olan perkütan ve endoskopik prosedürlerin endikasyonlar, kontrendikasyonlar, komplikasyonlar, teknik ve etkinlik açısından karşılaştırılmasını tanımlamaktır.

Anahtar sözcükler: Epidural fibrosis; epiduroskopik adezyolizis; nöroplastisi; perkutan adezyolizis; skar dokusu.

## Percutaneous Adhesiolysis

### History

The first epidurography was performed incidentally in 1921.<sup>[1]</sup> Payne and Rupp<sup>[2]</sup> used hyaluronidase with local anesthetic for caudal anesthesia in 1950. In 1960, Brown injected 40–199 mL of normal saline followed by 80 mg of methylprednisolone for fibrotic lesions in patients with sciatica. He reported resolution of sciatica pain for during 2 months in the four patients.<sup>[3]</sup> Hitchcock<sup>[4]</sup> used the first intrathecal hypertonic saline injection in 1967 to relieve chronic pain, whereas epidural hypertonic saline injection was administered by Racz and Holubec<sup>[5]</sup> in 1989, first time.

### Epidural scar tissue

Epidural fibrosis (Fig. 1) results from the proliferation of fibroblasts, transformation of fibroblasts to myo-

blasts, and accumulation of the disorganized extracellular matrix proteins.<sup>[6]</sup> Epidural fibrosis can occur following surgery, infection, hematoma and intrathecal contrast agent and leakage of nucleus pulposus material into the epidural space.<sup>[7,8]</sup> The scarring tissue itself is normally not tender. Scar tissue can frequently result in irritated swollen and inflamed (Fig. 2) nerves, which can cause pain that radiates from the low back into the legs.<sup>[9]</sup> A trapped nerve root is susceptible to tension and compression and lack of nutrition. In additionally, epidural scarring often obstructs epidural veins and increase the edema. This compressive phenomenon's further increase pain.

In epiduroscopy, Bosscher,<sup>[10]</sup> identified two levels of epidural fibrosis: Non-resistant loose or continuous strings and sheets of fibrous material and dense, resis-

<sup>1</sup>Department of Pain, University of Health Sciences, Antalya Training and Research Hospital, Antalya, Turkey

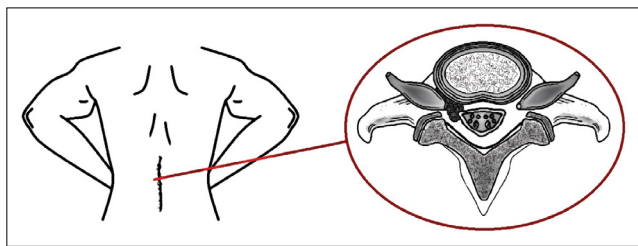
<sup>2</sup>Department of Algology, Akdeniz University Faculty of Medicine Hospital, Antalya, Turkey

Submitted: 28.11.2019 Accepted after revision: 29.06.2020 Available online date: 05.07.2021

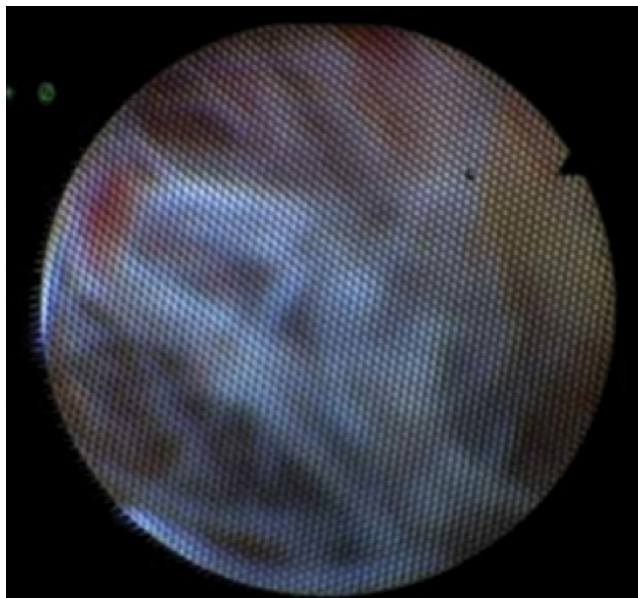
**Correspondence:** Dr. Mert Akbaş Akdeniz Üniversitesi Tıp Fakültesi Hastanesi, Algoloji Kliniği, Antalya, Turkey.

**Phone:** +90 - 242 - 227 44 00 **e-mail:** akbasmert@akdeniz.edu.tr

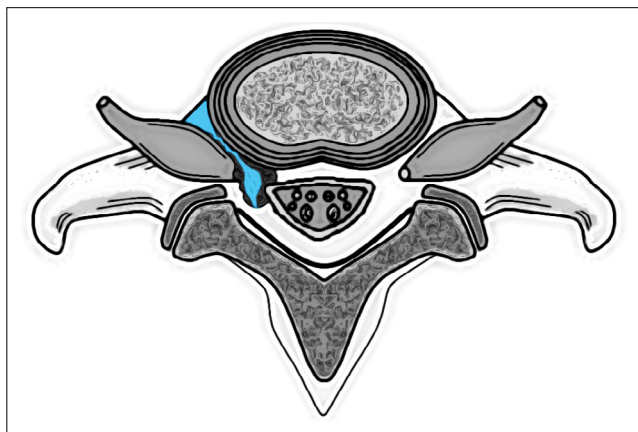
© 2021 Turkish Society of Algology



**Figure 1.** Scar tissue in epidural space.



**Figure 2.** Image of inflamed scar tissue in epiduroscopy.

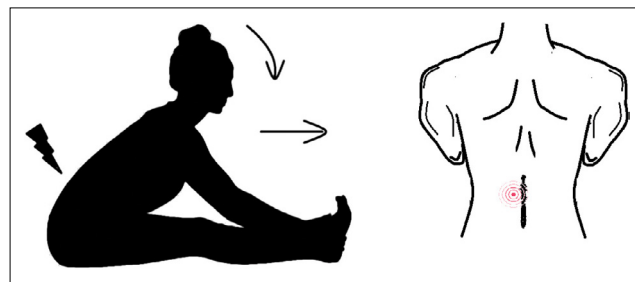


**Figure 3.** Pressure effect of the liquid providing a partial passageway through into the foramina.

tant fibrous material which could be penetrated with difficulty or not at all. The level of fibrosis and vascular changes can be considered as one of the factors affecting the outcome of the neuroplasty procedure.

### Fluid foraminotomy

In fluid foraminotomy, the pressure effect of the fluid (Fig. 3) provides a partial passageway through into the foramina, opening venous runoff, reducing foraminal stenosis and edema.<sup>[11]</sup>



**Figure 4.** Dural Tug Maneuver and localized low back pain.

### Diagnosis

#### Physical examination

- Stable vital sign
- Musculoskeletal examination
- Neurologic examination
- Straight leg raise: At less than 60 degrees (+)
- Provocative dural tug test: To perform the test, the patient should be sit up with a straight leg, bend forward flexing the lumbar spine until their back pain starts to become evident and the head and neck flexed rapidly forward. During this maneuver, the movement of the dura occur the localized low back pain<sup>[11]</sup> (Fig. 4)
- Elvey maneuver (helps to diagnose cervical radiculopathy)<sup>[12]</sup>
- Spurling maneuver (helps to diagnose cervical radiculopathy). Spurling test had low sensitivity (30%) but a high specificity (94%)<sup>[12]</sup>
- Cervical active/passive range of motion examination.

#### Radiologic examination

- Magnetic resonance imaging
- Computed tomography (CT)-CT myelography
- Epidurogram (epidural fibrosis is best diagnosed by epidurogram compared to other methods)

#### Indications

- Failed back or neck surgery syndrome
- Epidural fibrosis
- Cervical or lumbar radiculopathy
- Spinal stenosis
- Cervical or lumbar disc bulges
- Thoracic disk related chest wall and abdominal pain
- Metastatic carcinoma of the spine leading to compression fracture
- Multilevel degenerative arthritis
- Pain unresponsive to spinal cord stimulation
- Pain unresponsive to spinal opioid.

### Contraindications

- Local infection
- Sepsis
- Coagulopathies
- Unstable spine
- Inability to lie in prone position
- Patient refusal
- Syring formation.

### Equipment

- 25 gauge infiltration needle
- 18 gauge needle
- 15 or 16 gauge epidural needle (curved and beveled radiopaque needle)
- 24 cm epidural catheter (Suitable for 15 or 16 gauge epidural needle) (fluoropolymer-coated radiopaque epidural catheter made of stainless steel with spiral tip)
- Loss of resistance syringe
- 3 mL syringe
- Two 10 mL syringes
- Needle holder
- 3–0 nylon on cutting needle
- Scissors.

### Drugs

- 1% lidocaine for local anesthesia
- 2% preservative free lidocaine
- 0.25% preservative free levobupivacaine, bupivacaine, or 0.2% ropivacaine
- 0.9% preservative free saline
- 10% preservative free hypertonic saline.
- Steroids
- 1500U hyaluronidase.

In 1967, Hitchcock<sup>[4]</sup> used hypertonic saline injection for chronic pain treatment. Animal studies show that high chloride ion concentration of hypertonic saline causes selective C fiber blockade, reduces spinal cord water content and changes the sodium concentration of cerebrospinal fluid.<sup>[13–15]</sup> Injections of hypertonic saline can be quite painful; therefore, local anesthetics are generally injected before the saline. The intrathecal injection of hypertonic saline can produce a variety of complications. Clinical complications of hypertonic saline consist of cardiac (hypertension, tachycardia, and arrhythmia), respiratory (pulmonary edema), pain in the ear, vestibular disturbances, hemiplegia and loss of sphincter control.<sup>[16]</sup>

Hyaluronic acid is a large-molecule glycosaminoglycan that binds ground substance proteins that form proteoglycans. Hyaluronidase transiently degrades hyaluronic acid, a glycosaminoglycan found extensively in the interstitial matrix and basement membrane. Its primary function is to depolymerize hyaluronic acid and to a lesser degree chondroitin-6-sulfate and chondroitin-4-sulfate.<sup>[17]</sup> Not only are these proteoglycans found between the ground substances between cells but they are also in cheloids (dense scar tissue) and epidural adhesions. Dura is consist collagen, elastin and surface fibroblast. Cause of this reason, dura is not affected by hyaluronidase.<sup>[18]</sup> Hyaluronidase is present in, venoms, toxins, bacteria, mammalian tissue, and spermatozoa.<sup>[19,20]</sup> There are two types of hyaluronidase in clinical use: Animal-derived hyaluronidase and human form produced using recombinant technology. When using hyaluronidase, clinicians should be alert about allergies. Anaphylactic-like reactions have been reported in publications.<sup>[19]</sup>

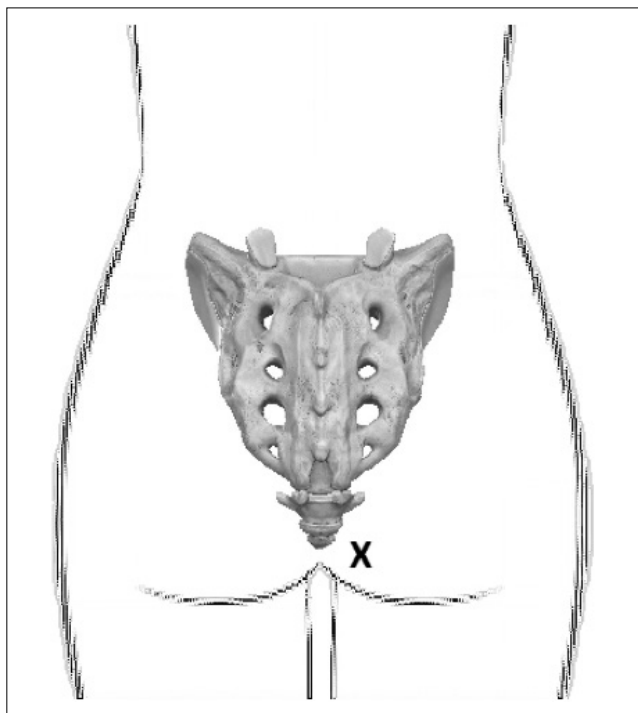
### Patient preparation

- Possible benefits and risks of the procedure should be discussed with the patient and informed consent forms should be obtained. In addition, the patient should be informed in detail about the target
- Anticoagulant drugs used by the patient should be questioned. If the patient's comorbid conditions are appropriate, these anticoagulants should be discontinued according to the guidelines<sup>[21]</sup>
- Drug allergy, problems with the previous anesthesia and interventional procedures should be questioned and noted
- Prothrombin time, partial thromboplastin time, bleeding time, white blood cell count, and platelet function tests should be reviewed
- Premedication is recommended for the patient's comfort (1–2 mg midazolam, 25–50 µg fentanyl and 1 g ceftriaxone by intravenous catheter)
- Patient should be monitored for safety (Automated blood pressure cuff, electrocardiogram, and pulse oximeter).

### Technique

#### Caudal approach


The patient is placed prone position with a pillow under the abdomen to correct the lumbar lordosis. The patient is asked to put his or her toes together



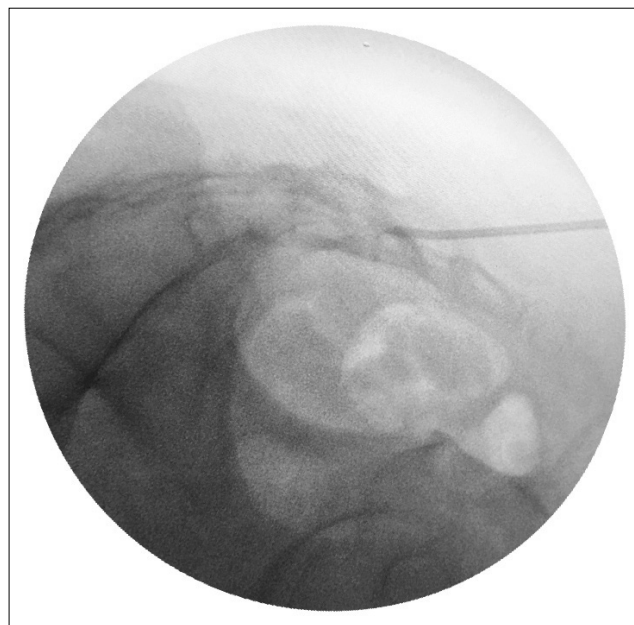
**Figure 5.** The site of entry in the gluteal fold for caudal neuroplasty.

for easier identification of the sacral hiatus. After sterile preparation and draping from the top of the iliac crest to the bottom, the sacral cornua and the sacral hiatus identified through palpation or with fluoroscopy. The entry point is approximately 1–2 cm lateral and 2–3 cm inferior to the sacral hiatus in the contralateral gluteal region (Fig. 5).

After skin infiltration with a local anesthetic such as 1% lidocaine, 16 gauge epidural needle is passed through entry point and then the sacrococcygeal ligament (sacral cornua is used as a landmark) (Fig. 6). The needle is not advanced higher than the S3 foramen to avoid damage to the sacral nerve root and to avoid dural puncture. Placement of the needle is confirmed by a lateral fluoroscopic imaging (Fig. 6a and Fig. 7) for determine that the needle is within the caudal canal and by a anteroposterior fluoroscopic imaging for verify that needle tip placement toward the affected side. After confirm a negative aspiration for blood or cerebrospinal fluid, an epidurogram is performed using 10 mL of non-ionic, water-soluble contrast agent. Ionic contrast agent should not be preferred because it may cause serious complications in accidental subarachnoid injection. If venous runoff is detected, the needle tip is moved until the venous escape of the contrast agent stops. Contrast agent is injected slowly and observed filling defects.



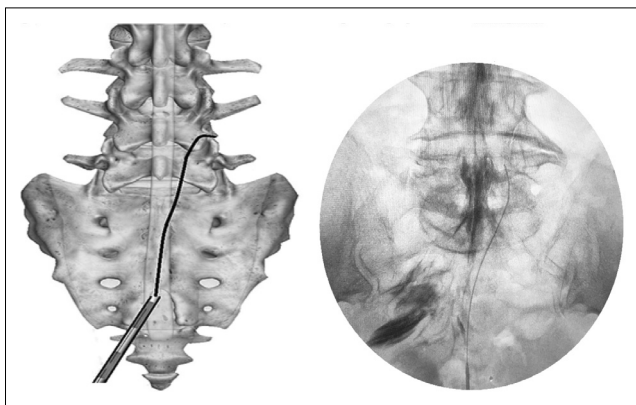
**Figure 6.** Position of needle and catheter with fluoroscopy.



**Figure 7.** Placement of the needle by a lateral fluoroscopic imaging in caudal neuroplasty.

A normal epidurogram will have an inverted “Christmas tree” pattern. Epidural adhesions will have a marked absence of dye, because of presumed scarring.

If the needle tip is subarachnoid, the contrast agent will centrally extends to several levels above L5. If the needle tip is subdural, contrast agent will spread circumferentially and longitudinally. It will have form linear streaks laterally along the thecal sac: So called “tram tracks.” On lateral views, it will have form a narrow, linear streak in the dorsal sac, and with a flat dorsal margin against the dura mater.<sup>[22]</sup> Unlike intrathecal spread, contrast medium injected into the subdural space will have persist longer. In addition, injection of local anesthetics into the subarachnoid or subdural space will have result in motor block. If cerebrospinal fluid is aspirated, the procedure should be canceled. If blood is aspirated, the needle is advanced caudally in the sacral canal until no blood can be aspirated.



**Figure 8.** Final placement of catheter by anteroposterior fluoroscopic imaging in caudal neuroplasty.

After the needle position has been confirmed and the distal opening is rotated (Fig. 6b, c), an epidural catheter that is bent at an angle of 15–30° from 2.5 cm of the distal tip is passed through the needle. Under continuous AP fluoroscopy, the tip of the catheter is advanced toward the ventral-lateral epidural space of the desired level (Fig. 6d). To avoid dural puncture, advancement of the catheter from the midline should be avoided. The catheter should be directed by turning it slightly clockwise or counterclockwise and avoiding pushing the tip of the catheter. Ideal location of the tip of catheter in the AP imaging is in the foramen just below the mid-portion of the pedicle and in the lateral imaging is in the ventral epidural space.

After final placement of the catheter (Fig. 8) and negative aspiration, 5 mL of non-ionic, water-soluble contrast agent is injected through the catheter. This additional contrast should be seen spreading into the previous filling defect. Subsequently, 1500 U of hyaluronidase in solution with 10 mL of preservative free normal saline is injected into the catheter. This injection should be administered slowly as it may disturb the patient. After observation of scar tissue opening at the nerve root, a 3 mL test dose of 10 mL of local anesthetic/steroid solution is administered. After 5 min, if there is no evidence of intrathecal or intravascular injection, and the remaining 7 mL of solution is injected. After the procedure is complete, the catheter may be withdrawn under continuous fluoroscopic guidance or secured for 3 days of treatment.

If the catheter is to be fixed, it should be sutured with non-absorbable suture, applied sterile dressing and a filter should be installed at the end of the catheter. To

prevent bacterial colonization during hospitalization, 1 g of ceftriaxone<sup>[23]</sup> is given daily and oral antibiotherapy should be recommended for 5 days to prevent the development of epidural abscess during discharge.

After the patient is taken recovery room, 10 mL of the 10% hypertonic saline is infused over 20–30 min. If the patients complain of severe burning pain, the infusion must be stopped and a 3–5 mL bolus of local anesthetics is injected. After 5 min of injection of local anesthetics, the hypertonic saline infusion can be restarted and after finish of hypertonic saline infusion, 1.5–2 mL of preservative free normal saline is used to clean down the catheter. The catheter is left in place for 3 days. On the 2<sup>nd</sup> and 3<sup>rd</sup> day, to the catheter is injected once a day with 10 mL of local anesthetic after negative aspiration. Fifteen minutes later from local anesthetics injection, 9 mL of 10% hypertonic saline is infused over 20 min. After finish of hypertonic saline infusion, 1.5–2 mL of preservative free normal saline is used to clean down the catheter. On the 3<sup>rd</sup> day, the catheter is removed 10 min after the last injection.

### Transforaminal approach

Transforaminal neuroplasty may be required of a second catheter when nerve roots are difficult to open or when approach to the anterior epidural space is needed. The patient is placed prone position. After sterile preparation and draping from just below the scapula to the lower margin of buttocks, fluoroscopy is prepared for full range of rotation. The angle is typically 15–30 degrees in caudocephalad and 15–30 degrees to affected side in oblique direction. The purpose of this position is to best visualization of the superior articular process that forms the inferoposterior portion of the targeted foramen. Entry point is the shadow of the tip of superior articular process. The epidural needle is felt the passed of tissues and carefully advanced to the tip of the superior articular process until bone contact is achieved. To facilitate passage of the needle past the articular process, the epidural needle is turned laterally to slide past the bone and stopped just after a “POP” is felt. The needle tip on a lateral view should be in the posterior aspect of the foramen. After the catheter is seen to exit from the needle tip, needle must be tilted at the hub laterally to aid entry of the epidural catheter into the anterior epidural space (Fig. 9). The catheter

placement must be confirmed to be in the anterior epidural space under lateral fluoroscopy imaging and the stylet is removed from catheter. Anatomically, the catheter is in the foramen above or below the exiting nerve root (Fig. 9). After confirmation of epidural spread with 1–2 mL of contrast medium, the total treatment dose (10 mL hyaluronidase, 14 mL local anesthetic + 1 mL steroid) is divided into both catheters. While 5 mL of the local anesthetic/steroid mixture and 5 mL of hyaluronidase are administered through the transforaminal catheter, the remaining volume is administered through the caudal catheter.

If the catheter is to be fixed, it should be sutured with non-absorbable suture, applied sterile dressing, and a filter should be installed at the end of the catheter. To prevent bacterial colonization during hospitalization, 1 g of ceftriaxone<sup>[23]</sup> is given daily and oral antibiotherapy should be recommended for 5 days to prevent the development of epidural abscess during discharge. After the patient is taken recovery room, the hypertonic saline solution is infused at a volume of 4–5 mL per transforaminal catheter and 8–10 mL per caudal catheter over 30 min. After finish of hypertonic saline infusion, 1–2 mL of preservative free normal saline is used to clean down the catheter. The catheter is left in place for 3 days. On the 2<sup>nd</sup> and 3<sup>rd</sup> day, transforaminal catheter position is checked under fluoroscopy. On the 3<sup>rd</sup> day, the catheter is removed 10 min after the last injection.

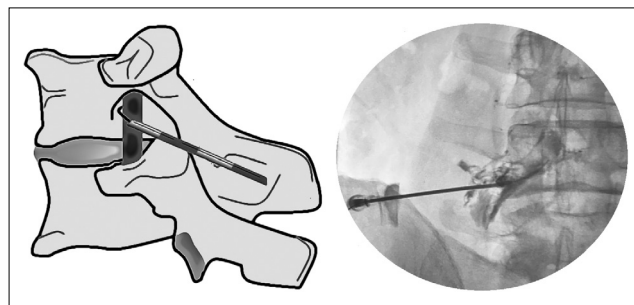
### S1 foraminal approach

This method can be preferred in patient with S1 radiculopathy or difficult caudal approach and S1 foraminal approach may be used to achieve lysis and fluid foraminotomy at this level.

### Cervical neuroplasty

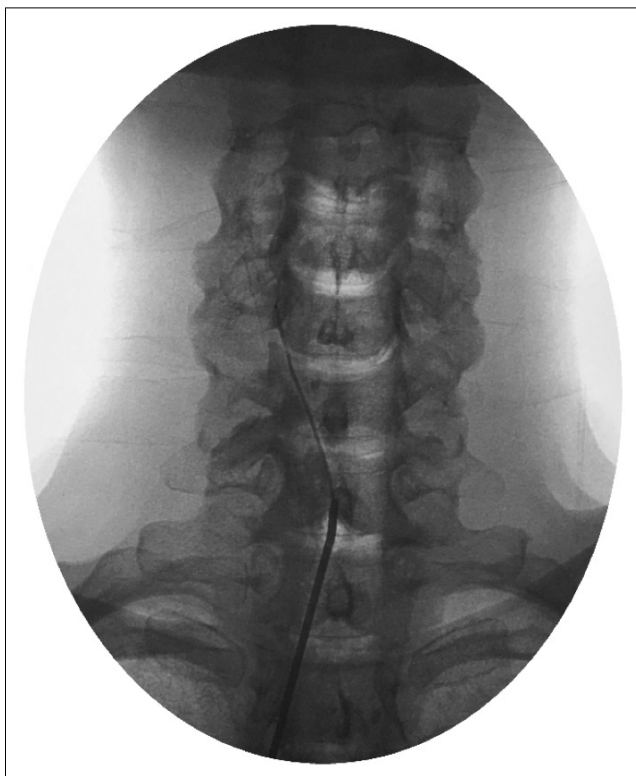Before starting the procedure, the patient's neck movements should be evaluated and if there is serious limitation in the movements, the procedure should be canceled. Passive neck movements during the procedure are helped reduce complications by reducing the pressure in the epidural space.

The procedure can be performed in the left lateral or prone position. Because of potential for dural puncture and spinal cord injury, the upper thoracic approach (T1-T2) is used. The entry point is 1–1.5 vertebral lev-



**Figure 9.** Following bony contact with SAP, the needle tip protruding blunt stylet will pass through the ligament and will be less likely to damage the nerve.

els below and 1 cm paramedian on the contralateral side. Using fluoroscopy in the anteroposterior view, 16 gauge epidural needles are inserted toward to T1-T2 with the tip of the needle directed to midline. At the skin the needle will appear to be progressing in a 70–80 degree angle owing to the lordosis of spine at that level. When the needle depth is reached 2–3 cm, the depth is checked in the lateral view. Depth is continuously controlled by AP and lateral imaging until it approaches the posterior border of the epidural space. The posterior border of the dorsal epidural space can be visualized by identifying the junction of the base of the spinous process of the vertebra with its lamina. The needle should be in the midline when the posterior border of the epidural space is reached. Using the loss of resistance technique (we are preferred approximately 1 mL of air and 9 mL preservative free normal saline to feel the loss of resistance more clearly in our clinic), the tip of the needle is placed in the epidural area and the needle tip is rotated to cephalad. Filling defect is detected after injecting 3–5 mL of contrast agent for the epidurogram. Passive cervical twisting movements during the epidurogram reduce the epidural pressure by increasing fluid flow through the foramina. Therefore, passive cervical twisting movements are proposed to reduce the complications. The 2.5–3 cm distal of the epidural catheter is bent at an angle of about 10 degrees and passed through the needle. As the target level is reached (Fig. 10), 0.5–1 mL of contrast agent is injected to visualize the target nerve root. Subsequently, a solution of 1500 U of hyaluronidase in 5 mL of protective free normal saline is injected into the catheter. To exclude intravascular and intrathecal injection, radiographic imaging is recommended during the injection of these agents. This is followed by 1–2 mL of additional contrast and the opening of the nerve root is observed. After observation of scar tissue opening at the nerve root, a 2 mL



**Figure 10.** Final placement of the catheter by anteroposterior fluoroscopic imaging in cervical neuroplasty.

test dose of 6 mL of local anesthetic/steroid solution is administered. After 5 min, if there is no evidence of intrathecal or intravascular injection, the remaining 4 mL of solution is injected.

If the catheter is to be fixed, it should be sutured with non-absorbable suture, applied sterile dressing, and a filter should be installed at the end of the catheter. To prevent bacterial colonization during hospitalization, 1 g of ceftriaxone is given daily and oral antibiotherapy should be recommended for 5 days to prevent the development of epidural abscess during discharge. If there is no evidence of intrathecal or intravascular injection, 5 mL of hypertonic saline solution is administered for 30 min. After finish of hypertonic saline infusion, 1–2 mL of preservative free normal saline is used to clean down the catheter. The second and third infusions are performed on the next day with 6 mL of local anesthetics and 5 mL of hypertonic saline using the same technique and precautions described for first infusion. After the procedure is complete, the catheter is removed.

### Complications of percutaneous adhesiolysis

As with any invasive procedure, complications are possible.<sup>[4,8,11,16,24–29]</sup>

Complications can be divided into three groups; catheter related, technique related, and drug related complications.

#### Catheter related complications


- Catheter obstruction (Contrast may obstruct the catheter due to density. The catheter should be flushed with normal saline after use)
- Catheter tearing
- Folding of the catheter
- Migration of catheter

#### Technique related complications

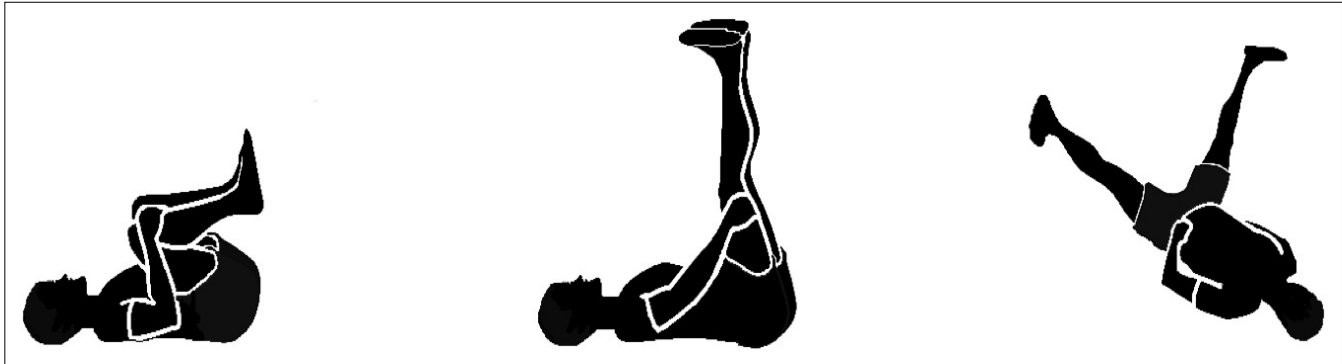- Subdural injection
- Subarachnoid injection
- Dural puncture
- Epidural hematoma
- Infection
- Arachnoiditis (Intrathecal injection)
- Cauda equina syndrome
- Transient paresthesia
- Paralysis
- Bruising at injection site
- Sexual dysfunction
- Spinal cord compression from injected fluids.

#### Drug related complications

- Hypertension (hypertonic saline)
- Tachycardia (hypertonic saline)
- Tachypnea (hypertonic saline)
- Pulmonary edema (hypertonic saline)
- Hemorrhagic dysfunction (hypertonic saline)
- Transient hypotension (contrast)
- Transient breathing difficulty (contrast)
- Headache (contrast)
- Seizures (contrast)
- Nausea-vomiting (contrast)
- Dizziness (contrast)
- Myalgias (contrast, steroids)
- Aseptic meningitis
- Allergic rxn (contrast, local anesthesia, and hyaluronidase)
- Local anesthetics toxicity
- Hypothalamic-pituitary-adrenal axis suppression (steroids)
- Hyperglycemia (steroids)
- Electrolyte-metabolic disturbance (steroids)
- Muscle wasting (steroids)
- Impaired wound healing (steroids)
- Impaired immunologic function (steroids)
- Arachnoiditis (steroids, hypertonic saline).



**Figure 11.** Cervical neural flossing.



**Figure 12.** Lumbar neural flossing.

### Post-procedure recommendations

Patients should be advised to exercise to mobilize nerve root movement after the procedure. If these exercises are done effectively 3 times per day for a few months, regeneration of scar tissue will be restricted.<sup>[11]</sup> These exercises are called “neural flossing” exercises.

### Cervical neural flossing exercises

The patient is stood parallel to the wall. The arm is opened to the side and pressure is applied to the wall to stretch the arm. Head is tilted on the other side. Finally, the chin is rotated toward the shoulder (Fig. 11).

### Lumbar neural flossing exercises

The patient lies on his/her back. Knees are brought to the chest with bent legs. Legs are raised to 90 degrees with straight knees. Finally, legs are spreaded in V shape (Fig. 12).

### Effectiveness and evidence level

Percutaneous adhesiolysis to relieve refractory low back and lower extremity pain is a technique whose efficacy has been showed by multiple randomized controlled trials. In a prospective observational study evaluating 66 patients with lumbar spinal stenosis which was performed percutaneous neuroplasty, improvement (including slightly healed, very healed, and no painless reports) was observed

in 49 participants (74.2%) at 2 weeks and in 45 participants (66.7%) at 6 months after the procedure. There was no statistically significant correlation between pain relief and dural sac cross-sectional area, age, or participant sex in this study.<sup>[30]</sup> Manchikanti et al.<sup>[31]</sup> compared epidural adhesiolysis and caudal epidural steroid injection in patients with lumbar central spinal stenosis in another study. This evaluation showed significant pain relief ( $\geq 50\%$ ) in 76% of the patients at 1 year follow-up in the adhesiolysis group compared to 4% of the patients in the control group.<sup>[32]</sup> In a study of 120 patients with chronic function limiting pain after lumbar surgery was revealed that significant pain relief ( $\geq 50\%$ ) in 73% of the patients and functional improvement ( $\geq 40\%$  reduction in Oswestry scores) in 77% undergoing adhesiolysis at 1-year follow-up. Significant differences were observed between control group and adhesiolysis group. In addition, percutaneous neuroplasty is thought to be more effective in patients who have not previously undergone lumbar surgery.<sup>[33]</sup>

In the literature review by Helm et al.<sup>[34]</sup> 1474 articles were found related to the effectiveness of percutaneous adhesiolysis from 1966 to 2012. Only five randomized, controlled trials and two observational studies met criteria for inclusion. These studies were indicated that there is fair evidence that percutaneous adhesiolysis is effective in relieving low back and/or leg pain caused by post-lumbar surgery syn-



drome and by spinal stenosis. This study was showed that the incidence of complications from percutaneous adhesiolysis was low and the complications were generally minimal and self-limited. When the procedure is performed by well-trained physicians, the risk for serious adverse events has been shown to be low. Further, there are publications in the literature comparing 1-day treatment and 3-day treatment to reduce the risk of complication. In 60 patients with failed back surgery syndrome who are treated 1 day procedure and 3 days Racz procedure showed that adhesiolysis was successful in 23 (76.7%) and 25 (83.3%) patients in 1 day and 3 days groups, respectively. In addition, this difference was not statistically significant. Therefore, Hossieni et al.<sup>[35]</sup> suggested using the 1 day technique due to the decreased duration of them procedure and hospital stay, which can be associated with less patient discomfort and treatment cost.

In addition, caudal, transforaminal, and S1 foraminal approaches were compared in 60 patients who underwent lumbar surgery. Akbas et al.<sup>[36,37]</sup> showed that the three anatomical approaches (caudal, S1 foraminal, and L5-S1 transforaminal) used in percutaneous neuroplasty have the same pain relief outcomes and complication rates.

In the American Society of Interventional Pain Physicians evidence-based guidelines, Epidural Adhesiolysis was at the level of evidence showing a strong correlation with the level of evidence 1B or 1C for post-lumbar surgery syndrome.<sup>[38]</sup> Furthermore, in the analysis of systematic review of Manchikanti et al.<sup>[39]</sup> the evidence for percutaneous adhesion was shown to be level I.

## Endoscopic Neuroplasty

### History

Bruman<sup>[40]</sup> used arthroscopic instruments in cadaver vertebral column in 1931. The first myeloscope used on patients was developed by Stern<sup>[41]</sup> and the first in vivo examination of the spinal canal was performed by Pool.<sup>[42,43]</sup> From 1967 to 1977, Ooi et al.<sup>[44]</sup> performed 208 myeloscopies with an instrument that combined a flexible light source with rigid optics. Epiduroscopic technology with flexible optics has been used in clinical application on patients since the early 1990s.<sup>[45]</sup>

## Diagnosis

### Physical and radiologic examination

Physical examination and radiological evaluation were discussed in "Percutaneous Adhesiolysis" chapter.

### Indications

- Failed back surgery syndrome
- Epidural fibrosis
- Lumbar radiculopathy
- Spinal stenosis
- Lumbar disc bulges.

### Contraindications

In 2006, the consensus committee of the World Initiative on Spinal Endoscopy defined the following contraindications:<sup>[46]</sup>

- Local infection
- Sepsis
- Coagulopathies
- Inability to lie in prone position
- Patient refusal
- Psychiatric disease
- Retinal disease
- Increase in intracranial pressure
- Pregnancy
- Bowel and bladder dysfunction
- Sensory disturbance in the S2-S4 area
- Congenital anomalies that do not permit safe endoscopy
- Cerebrovascular disease
- Renal or liver insufficiency
- Severe respiratory insufficiency
- High risk of cardiovascular disease
- Anal fistula
- Sacral osteomyelitis
- Meningeal cysts
- Meningoceles/meningomyeloceles
- Malignant tumors.

### Equipment

- 9 and 10 French central access catheter with dilators
- Guidewire
- 0.8–1.0 mm fiber optic scope
- 25 Gauge infiltration needle
- 18 Gauge needle
- No 11 blade scalpel
- 4–10 mL syringe
- IV T-piece extension

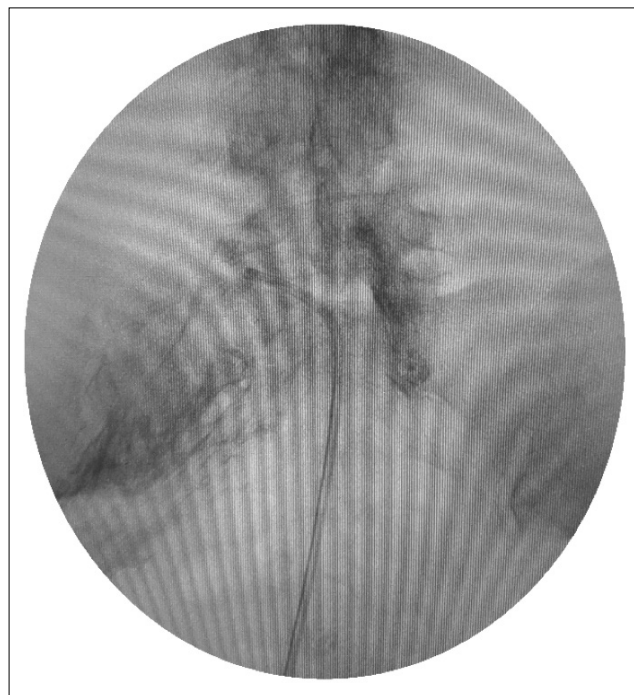- 16 Gauge epidural needle
- Needle holder
- 2-0 nylon suture
- 26 cm epidural catheter
- Epidural catheter connector
- 22 × 2 split sponges
- 3 mL syringe
- Transparent surgical dressing.

### Drugs

- 1% lidocaine for local anesthesia
- 0.25% preservative free levobupivacaine, bupivacaine, or 0.2% ropivacaine
- 0.9% preservative free saline
- 10% preservative free hypertonic saline
- 1500U hyaluronidase
- Steroids.

### Technique

Epiduroscopy is performed after preprocedure antibiotic administration in sterile conditions under conscious sedation with continuous hemodynamic and respiratory monitoring. In general, communication with the patient must be possible at all times during the intervention. With the patient lying prone on the operating table, a pillow is placed underneath the abdomen to straighten the lumbar lordosis. The patient is prepared and draped in a sterile manner. The area around the sacral hiatus is anesthetized with 1% lidocaine. A 16 gauge epidural needle is inserted through the sacral hiatus under lateral X-ray control. This may be verified in both the anteroposterior and lateral fluoroscopic views. An epidurogram is performed with 10 mL of water soluble non-ionic contrast agent. Next, a guidewire is threaded through the Tuohy needle under fluoroscopic guidance to L5 or S1 level. The epidural needle is then removed. A small incision is made. Using a Seldinger technique, an introducer is advanced over the guidewire into sacral epidural space. After the dilatation, the video-guided catheter containing the flexible epiduroscope is inserted. Fluoroscopy is necessary to verify the proper placement (Fig. 13). During the epiduroscopy procedure, injection rates of 0.9% saline should not exceed 30 ml/minute and total infused volume should not exceed 100 mL. The amount of irrigation solution used and the processing time must be monitored. It is generally recommended that the processing



**Figure 13.** Placement of the video guided catheter by anteroposterior fluoroscopic imaging.

time should not exceed 30 min. Pressure in the epidural space can be monitored. Although there is no support in the literature, it seems logical that the epidural pressure should not exceed the mean blood pressure.

The steerable fiberoscope allows for three dimensional direct observations. The video guided catheter with epiduroscope is steered cranially under direct vision in the epidural space to the level of expected pathology in combination with fluoroscopy. The procedure must also be discontinued in case the patient experiences severe paresthesias and/or pain, neck pain or headache. Once adhesions are identified, attempts are made to rupture them mechanically by gentle movements of the video guided catheter and by bolus injections of small amounts of saline. After neuroplasty procedure, an epidurogram is made to record the result. Finally, a mixture of local anesthetics and steroids is injected. After the intervention, patients are monitored at the recovery room.

### Complications

Complications are similar to percutaneous adhesiolysis.<sup>[47]</sup>

### Post-procedure recommendations

The exercise recommendations described above also apply to epiduroscopic adhesiolysis.

**Table 1.** Comparison of percutaneous and endoscopic adhesiolysis

	Percutaneous adhesiolysis	Endoscopic adhesiolysis
Evidence level	Level 1	Level II <sup>[29]</sup>
Efficiency	Effective	Effective
Sedation need	Rare	Frequent
Training level	Intermediate	Master
Complication	More rare	Rare
Additional equipment	Fluoroscopy	Fluoroscopy and video monitor
Assistant	None	At least one

### Effectiveness of epiduroscopic neuroplasty

The sensitivity of epiduroscopy in epidural diagnosis to be 91%, and the ability to detect a pathologic lesion to be 75%.<sup>[48]</sup> Although epiduroscopy provides both diagnosis and treatment, the complication rate and the need for experienced users should be kept in mind.

There are many publications in the literature on epiduroscopic adhesiolysis. Geurts et al.<sup>[49]</sup> Richardson et al.<sup>[50]</sup> and Igarashi et al.<sup>[51]</sup> have reported effectiveness of epiduroscopic adhesiolysis on chronic back and radicular pain. In a randomized, double-blind and controlled study in 83 patients by Manchikanti et al.<sup>[23]</sup> 80% of patients at 3 months, 56% of patients at 6 months, and 48% of patients at 12 months still showed improvement in their symptoms after epiduroscopic adhesiolysis. Takeshima et al.<sup>[52]</sup> reported that epiduroscopic adhesiolysis was an effective treatment in patients with lumbar surgery and that adhesiolysis of the nerve root may have long-term efficacy in patients who are experiencing pain. Ceylan et al.<sup>[48]</sup> compared 82 patients according to the type of stabilized and non-stabilized surgery for the efficacy of epiduroscopic adhesiolysis. This study showed that the combination of epiduroscopic adhesiolysis and hyaluronidase-steroid was more effective in pain control in patients without stabilization.

### Comparison of percutaneous and endoscopic neuroplasty

Percutaneous adhesiolysis to treat refractory low back and lower extremity pain is a technique whose efficacy has been documented by more than one randomized controlled trials, while endoscopic adhesiolysis is a technique with limited evidence.<sup>[29]</sup> Other differences are compared in Table 1.

Percutaneous adhesiolysis of epidural adhesions is a safe and effective procedure, with minimal complications when performed by experienced practitioners. Epiduroscopy is one of the best diagnostic and therapeutic tools for difficult spinal pain syndromes with wider uses in the coming days but should perform by trained practitioners. Inexperienced users increase the duration of the procedure and the volume of infusion, which increases the possibility of complications. The total volume, speed, and time infused should be limited to avoid complications.<sup>[53]</sup> Nevertheless, randomized controlled trials with high-quality data are needed to select procedure preferences and indications. Our advice is to choose that you are more experienced in the difficult cases.

**Conflict-of-interest issues regarding the authorship or article: None declared.**

**Peer-review: Externally peer-reviewed.**

### References

1. Botwin K, Natalicchio J, Brown LA. Epidurography contrast patterns with fluoroscopic guided lumbar transforaminal epidural injections: A prospective evaluation. *Pain Physician* 2004;7(2):211–5.
2. Payne JN, Rupp NH. The use of hyaluronidase in caudal block anesthesia. *Anesthesiology* 1951;12(2):164–72. [\[CrossRef\]](#)
3. Brown JH. Pressure caudal anesthesia and back manipulation. Conservative method for treatment of sciatica. *Northwest Med* 1960;59:905–9. [\[CrossRef\]](#)
4. Hitchcock E. Hypothermic subarachnoid irrigation for intractable pain. *Lancet (London, England)* 1967;1(7500):1133–5. [\[CrossRef\]](#)
5. Racz GB, Holubec JT. Lysis of adhesions in the epidural space. In: Racz GB, editor. *Techniques of Neurolysis*. Boston: Kluwer; 1989. p. 57–72. [\[CrossRef\]](#)
6. Turkoglu E, Dinc C, Tuncer C, Oktay M, Serbes G, Sekerci Z. Use of decorin to prevent epidural fibrosis in a post-laminectomy rat model. *Eur J Pharmacol* 2014;724:86–91. [\[CrossRef\]](#)
7. McCarron RF, Wimpee MW, Hudkins PG, Laros GS. The

- inflammatory effect of nucleus pulposus. A possible element in the pathogenesis of low-back pain. *Spine* 1987;12(8):760–4. [\[CrossRef\]](#)
8. Manchikanti L, Staats PS, Singh V, Schultz DM, Vilims BD, Jasper JF. Evidence-based practice guidelines for interventional techniques in the management of chronic spinal pain. *Pain Physician* 2003;6:3–81. [\[CrossRef\]](#)
  9. Kuslich SD, Ulstrom CL, Michael CJ. The tissue origin of low back pain and sciatica: A report of pain response to tissue stimulation during operations on the lumbar spine using local anesthesia. *Orthop Clin North Am* 1991;22:181–7.
  10. Bosscher HA, Heavner JE. Incidence and severity of epidural fibrosis after back surgery: An endoscopic study. *Pain Pract* 2010;10(1):18–24. [\[CrossRef\]](#)
  11. Racz GB, Heavner JE, Smith JP, Noe CE, Al-Kaisy A, Matsu-moto T, et al. *Epidural Lysis of Adhesions and Percutaneous Neuroplasty*. London: IntechOpen; 2014. [\[CrossRef\]](#)
  12. Iyer S, Kim HJ. Cervical radiculopathy. *Curr Rev Musculo-skelet Med* 2016;9(3):272–80. [\[CrossRef\]](#)
  13. Lake DA, Barnes CD. Effects of changes in osmolality on spinal cord activity. *Exp Neurol* 1980;68(3):555–67. [\[CrossRef\]](#)
  14. Racz GB, Heaver JE, Singleton W, Carline M. Hypertonic saline and corticosteroid injected epidurally for pain control. In: Racz GB, Heaver JE, editor. *Techniques of Neurolysis*. Boston: Kluwer; 1988. p. 73–86. [\[CrossRef\]](#)
  15. King JS, Jewett DL, Sundberg HR. Differential blockade of cat dorsal root C fibers by various chloride solutions. *J Neurosurg* 1972;36(5):569–83. [\[CrossRef\]](#)
  16. Lucas JT, Ducker TB, Perot PL Jr. Adverse reactions to intrathecal saline injection for control of pain. *J Neurosurg* 1975;42(5):557–61. [\[CrossRef\]](#)
  17. Watson D. Hyaluronidase. *Br J Anaesth* 1993;71(3):422–5.
  18. Racz GB, Noe CL. Pelvic spinal neuroaxial procedures. In: Raj PP, editor. *Interventional Pain Management: Image-Guided Procedures*. Philadelphia, PA: Elsevier; 2008. p. 405–28.
  19. Dunn AL, Heavner JE, Racz G, Day M. Hyaluronidase: A review of approved formulations, indications and off-label use in chronic pain management. *Exp Opin Biol Ther* 2010;10(1):127–31. [\[CrossRef\]](#)
  20. Gilson RL, Gondal AZ. *Hyaluronidase*. Treasure Island, FL: StatPearls Publishing; 2019.
  21. Horlocker TT, Vandermeulen E, Kopp SL, Gogarten W, Leffert LR, Benzon HT. Regional anesthesia in the patient receiving antithrombotic or thrombolytic therapy: American society of regional anesthesia and pain medicine evidence-based guidelines (fourth edition). *Reg Anesth Pain Med* 2018;43(3):263–309. [\[CrossRef\]](#)
  22. Patel AH, Giampetro DM. Fluoroscopic subdural contrast flow pattern in the lumbar spine. *Pain Med* 2018;19(12):2571–2. [\[CrossRef\]](#)
  23. Manchikanti L, Boswell MV, Rivera JJ, Pampati VS, Damron KS, McManus CD. A randomized, controlled trial of spinal endoscopic adhesiolysis in chronic refractory low back and lower extremity pain. *BMC Anesthesiol* 2005;5:10. [\[CrossRef\]](#)
  24. Fibuch EE. Percutaneous epidural neuroplasty: cutting edge or potentially harmful pain management? *Reg Anesth Pain Med* 1999;24(3):198–201. [\[CrossRef\]](#)
  25. Talu GK, Erdine S. Complications of epidural neuroplasty: A retrospective evaluation. *Neuromodulation* 2003;6(4):237–47. [\[CrossRef\]](#)
  26. Viesca CO, Racz GB, Day MR. Special techniques in pain management: Lysis of adhesions. *Anesthesiol Clin North Am* 2003;21(4):745–66, vi. [\[CrossRef\]](#)
  27. Chopra P, Smith HS, Deer TR, Bowman RC. Role of adhesiolysis in the management of chronic spinal pain: A systematic review of effectiveness and complications. *Pain Physician* 2005;8(1):87–100. [\[CrossRef\]](#)
  28. Trescot AM, Chopra P, Abdi S, Datta S, Schultz DM. Systematic review of effectiveness and complications of adhesiolysis in the management of chronic spinal pain: an update. *Pain Physician* 2007;10(1):129–46. [\[CrossRef\]](#)
  29. Helm S 2nd, Racz GB, Gerdesmeyer L, Justiz R, Hayek SM, Kaplan ED. Percutaneous and endoscopic adhesiolysis in managing low back and lower extremity pain: A systematic review and meta-analysis. *Pain Physician* 2016;19(2):E245–82. [\[CrossRef\]](#)
  30. Park CH, Lee SH, Jung JY. Dural sac cross-sectional area does not correlate with efficacy of percutaneous adhesiolysis in single level lumbar spinal stenosis. *Pain Physician* 2011;14(4):377–82. [\[CrossRef\]](#)
  31. Manchikanti L, Singh V, Cash KA, Pampati V, Datta S. A comparative effectiveness evaluation of percutaneous adhesiolysis and epidural steroid injections in managing lumbar post surgery syndrome: A randomized, equivalence controlled trial. *Pain Physician* 2009;12(6):E355–68. [\[CrossRef\]](#)
  32. Manchikanti L, Cash KA, McManus CD, Pampati V, Singh V, Benyamin R. The preliminary results of a comparative effectiveness evaluation of adhesiolysis and caudal epidural injections in managing chronic low back pain secondary to spinal stenosis: A randomized, equivalence controlled trial. *Pain Physician* 2009;12(6):E341–54. [\[CrossRef\]](#)
  33. Choi E, Nahm FS, Lee PB. Evaluation of prognostic predictors of percutaneous adhesiolysis using a Racz catheter for post lumbar surgery syndrome or spinal stenosis. *Pain Physician* 2013;16(5):E531–6. [\[CrossRef\]](#)
  34. Helm li S, Benyamin RM, Chopra P, Deer TR, Justiz R. Percutaneous adhesiolysis in the management of chronic low back pain in post lumbar surgery syndrome and spinal stenosis: A systematic review. *Pain Physician* 2012;15(4):E435–62.
  35. Hossieni B, Dadkhah P, Moradi S, Hashemi SM, Safdari F. The results of treating failed back surgery syndrome by adhesiolysis: Comparing the one and three-day protocols. *Anesthesiol Pain Med* 2017;7(5):e60271. [\[CrossRef\]](#)
  36. Akbas M, Elawamy AR, Salem HH, Fouad AZ, Abbas NA, Dagistan G. Comparison of 3 approaches to percutaneous epidural adhesiolysis and neuroplasty in post Lumbar surgery syndrome. *Pain Physician* 2018;21(5):E501–8. [\[CrossRef\]](#)
  37. Akbas M. Safe and secure approaches at lysis procedures. *Pain Physician* 2019;22(2):E141. [\[CrossRef\]](#)
  38. Manchikanti L, Abdi S, Atluri S, Benyamin RM, Boswell MV, Buenaventura RM, et al. An update of comprehensive evidence-based guidelines for interventional techniques in chronic spinal pain. Part II: Guidance and recommenda-

- tions. *Pain Physician* 2013;16(2 Suppl):S49–283. [\[CrossRef\]](#)
39. Manchikanti L, Soin A, Boswell MV, Kaye AD, Sanapati M, Hirsch JA. Effectiveness of percutaneous adhesiolysis in post lumbar surgery syndrome: A systematic analysis of findings of systematic reviews. *Pain Physician* 2019;22(4):307–22. [\[CrossRef\]](#)
  40. Burman MS. Myelography or the direct visualization of the spinal canal and its contents. *J Bone Joint Surg* 1931;13(4):695–6.
  41. Richardson J. Realizing visions. *Br J Anaesth* 1999;83(3):369–71. [\[CrossRef\]](#)
  42. Pool JL. Direct visualization of dorsal nerve roots of the cauda equina by means of a myeloscope. *Arch Neurol Psychiatry* 1938;39(6):1308–12. [\[CrossRef\]](#)
  43. Pool JL. Myelography: Intraspinous endoscopy. *Surg Clin North Am* 1957;37(5):1401–2. [\[CrossRef\]](#)
  44. Ooi Y, Satoh Y, Inoue K, Mikanagi K, Morisaki N. Myelography, with special reference to blood flow changes in the cauda equina during Lasegue's test. *Int Orthop* 1981;4(4):307–11.
  45. Saberski LR, Brull SJ. Spinal and epidural endoscopy: A historical review. *Yale J Biol Med* 1995;68(1–2):7–15.
  46. Beltrutti D, Groen GJ, Saberski L, Sandner-Kiesling A, Schütze G, Weber G. Epiduroscopy: Consensus decision March, 2006. *Pain Clin* 2007;19(2):47–50. [\[CrossRef\]](#)
  47. Avellanal M, Diaz-Reganon G, Orts A, Gonzalez-Montero L, De Andres J. Epiduroscopy: Complications and trouble-shooting. *Techniques in Regional Anesthesia and Pain Management*. 2014;18(1-2):35-39. [\[CrossRef\]](#)
  48. Ceylan A, Asik I, Ozgencil GE, Erken B. Evaluation of the efficacy of epiduroscopic adhesiolysis in failed back surgery syndrome. *Turk J Med Sci* 2019;49(1):249–57. [\[CrossRef\]](#)
  49. Geurts JW, Kallewaard JW, Richardson J, Groen GJ. Targeted methylprednisolone acetate/hyaluronidase/clonidine injection after diagnostic epiduroscopy for chronic sciatica: A prospective, 1-year follow-up study. *Reg Anesth Pain Med* 2002;27(4):343–52. [\[CrossRef\]](#)
  50. Richardson J, McGurgan P, Cheema S, Prasad R, Gupta S. Spinal endoscopy in chronic low back pain with radiculopathy. A prospective case series. *Anaesthesia* 2001;56(5):454–60. [\[CrossRef\]](#)
  51. Igarashi T, Hirabayashi Y, Seo N, Saitoh K, Fukuda H, Suzuki H. Lysis of adhesions and epidural injection of steroid/local anaesthetic during epiduroscopy potentially alleviate low back and leg pain in elderly patients with lumbar spinal stenosis. *Br J Anaesth* 2004;93(2):181–7. [\[CrossRef\]](#)
  52. Takeshima N, Miyakawa H, Okuda K, Hattori S, Hagiwara S, Takatani J. Evaluation of the therapeutic results of epiduroscopic adhesiolysis for failed back surgery syndrome. *Br J Anaesth* 2009;102(3):400–7. [\[CrossRef\]](#)
  53. Bellini M, Barbieri M. A comparison of non-endoscopic and endoscopic adhesiolysis of epidural fibrosis. *Anaesthesiol Intens Ther* 2016;48(4):266–71. [\[CrossRef\]](#)