



## ORIGINAL ARTICLE

# Does the application of pulse radiofrequency to the suprascapular nerve provide additional benefit in patients who have undergone glenohumeral intra-articular steroid injection and suprascapular nerve block?

*Glenohumeral eklem içi steroid enjeksiyonu ve supraskapuler sinir bloku uygulanan hastalarda supraskapuler sinire pulse radyofrekans uygulanması ek fayda sağlar mı?*

Halil ÇETİNGÖK,<sup>1</sup> Gökhan Işık SERÇE<sup>2</sup>

## Summary

**Objectives:** Shoulder pain is one of the most common musculoskeletal pain syndromes. Interventional treatments can be applied to patients who do not respond to conservative therapies. Intra-articular steroid injection and suprascapular nerve block are both short-acting and may sometimes be clinically inadequate. In this study, the answer to the question of whether pulse radiofrequency application to the suprascapular nerve provides additional benefit was investigated.

**Methods:** Patients who had shoulder pain and were injected between October 2016 and April 2018 were evaluated retrospectively. Totally 160 patients who underwent shoulder injections were included in the study. Patients were divided into two groups: 114 patients who underwent shoulder intra-articular steroid injection and suprascapular nerve block, as Group 1 and 46 patients who underwent pulse radiofrequency to the suprascapular nerve, in addition to shoulder intra-articular steroid injection and suprascapular nerve block, as Group 2.

**Results:** There was no statistical difference between the groups in pre-intervention numerical rating scale (NRS) scores. One month after the intervention, NRS scores of Group 2 were significantly lower than Group 1. In both groups, 1 month after the intervention NRS scores were significantly lower than pre-intervention. The duration of pain relief for Group 2 was longer than Group 1. The satisfaction percentages of patients for Group 2 were higher than Group 1.

**Conclusion:** In addition to glenohumeral intra-articular steroid injection and suprascapular nerve block, pulse radiofrequency application to the suprascapular nerve provides additional benefits in terms of NRS scores, duration of pain relief, and patient satisfaction.

Keywords: Intra-articular steroid injection; pulsed radiofrequency; shoulder pain; suprascapular nerve block.

## Özet

**Amaç:** Omuz ağrısı, kas iskelet sistemi ağrı sendromları arasında en sık görülenlerden biridir. Konservatif tedavilere yanıt vermeyen hastalarda girişimsel tedaviler uygulanabilir. Eklem içi steroid enjeksiyonu ve supraskapuler sinir blokunun her ikisi de kısa etkilidir ve bazı durumlarda klinik olarak yetersiz kalabilmektedir. Bu çalışmada, supraskapuler sinire pulse radyofrekans uygulamasının bu girişimlere ek fayda sağlayıp sağlamadığı sorusunun cevabı araştırılmıştır.

**Gereç ve Yöntem:** Ekim 2016 ile Nisan 2018 tarihleri arasında omuz ağrısı olan ve enjeksiyon yapılan hastalar geriye dönük olarak değerlendirildi. Toplamda omuz enjeksiyonu uygulanan 160 hasta çalışmaya dahil edildi. Hastalar iki gruba ayrıldı. Grup 1'e omuz içi steroid enjeksiyonu ve supraskapuler sinir bloku uygulanan 114 hasta; Grup 2'ye ise omuz eklem içi steroid enjeksiyonu ve supraskapuler sinir blokuna ek olarak supraskapuler sinire pulse radyofrekans uygulanan 46 hasta alındı.

**Bulgular:** Girişim öncesi NRS skorlarında gruplar arasında istatistiksel fark yoktu. Müdahaleden bir ay sonra grup 2'nin NRS skorları grup 1'den anlamlı derecede düşük bulundu. Her iki grupta da girişimden bir ay sonraki NRS skorları girişim öncesine göre anlamlı derecede düşüktü. Grup 2'de enjeksiyonun etki süresi grup 1'den daha uzundu. Grup 2'deki hastaların memnuniyet yüzdeleri grup 1'den istatistiksel olarak daha yüksek bulundu.

**Sonuç:** Glenohumeral eklem içi steroid enjeksiyonu ve supraskapuler sinir blokuna ek olarak supraskapuler sinire pulse radyofrekans uygulaması NRS skorları, etki süresi ve hasta memnuniyeti açısından ek fayda sağlamaktadır.

Anahtar sözcükler: Eklem içi steroid enjeksiyonu; puls radyofrekans; omuz ağrısı; supraskapuler sinir bloku.

<sup>1</sup>Division of Pain Medicine, Department of Anesthesiology, Istanbul University, Istanbul Faculty of Medicine, Istanbul, Türkiye

<sup>2</sup>Department of Pain Medicine, Tekirdağ Dr. İsmail Fehmi Cümaliolu Hospital, Tekirdağ, Türkiye

Submitted (Başvuru): 02.10.2022 Accepted (Kabul): 08.10.2022 Available online (Online yayımlanma): 18.10.2022

**Correspondence:** Dr. Halil Çetingök. İstanbul Üniversitesi, İstanbul Tıp Fakültesi, Anesteziyoloji Anabilim Dalı, Algoloji Bilim Dalı, İstanbul, Türkiye.

**Phone:** +90 - 212 - 531 31 47 **e-mail:** halilcetingok@yahoo.com

© 2022 Turkish Society of Algology

## Introduction

Shoulder pain affects the quality of life negatively, especially in the adult age group. The overall prevalence of shoulder pain is 18–26%, and it is one of the most common musculoskeletal pain syndromes.

<sup>[1]</sup> The shoulder joint is one of the most complex joints and includes these structures: bony structures (head of humerus, clavicle, and scapula), joints (glenohumeral, acromioclavicular, and sternoclavicular), rotator cuff muscles/tendons (supraspinatus, infraspinatus, teres minor, and subscapularis), bursas (subacromial, subdeltoid, and subcoracoid), and neuronal structures (suprascapular, axillary, lateral pectoral, and lower subscapular). Many different pathologies arising from these structures result in shoulder pain. Among them, the most common ones are rotator cuff disease, subacromial impingement syndrome, adhesive capsulitis (frozen shoulder), subacromial/subdeltoid bursitis, glenohumeral, or acromioclavicular joint osteoarthritis.<sup>[2]</sup>

Conservative treatments, interventional treatments, and surgical treatments are used in the treatment of chronic shoulder pain. Conservative treatments include rest, ice, physiotherapy, exercise, occupational therapy, laser, ultrasound, shock wave therapy, analgesic, and anti-inflammatory medications.<sup>[3]</sup> Regardless of the reason, interventional treatments can be applied to patients who do not respond to conservative therapies. Intra-articular steroid injection is one of the oldest and most frequently used interventional treatments for the shoulder region. Steroid injection has been found to be superior to conservative treatments and especially non-steroidal anti-inflammatory treatments.<sup>[4]</sup> However, this effect is short-lived (4–6 weeks) and may sometimes be clinically inadequate.<sup>[4]</sup> It has been suggested that the suprascapular nerve block, which is known to be responsible for 70% of the sensory innervation of the shoulder joint, may be effective in the treatment of chronic shoulder pain.<sup>[5]</sup> In addition to steroid injection, suprascapular nerve block may provide more benefits.<sup>[6]</sup> However, the effect of nerve blockade is short-lived, similar to steroid injection.<sup>[7]</sup>

Although pulse radiofrequency treatments are weaker than conventional radiofrequency in terms of potency, they can be applied to peripheral nerves because they do not cause neuronal damage and

related motor deficit.<sup>[8]</sup> Pulse radiofrequency applications to peripheral nerves have been used frequently in recent years because it generally provides effective analgesia for a much longer period than nerve blockade. In this study, we aimed to evaluate whether pulse radiofrequency application to the suprascapular nerve brings additional benefit in addition to glenohumeral intra-articular steroid injection and suprascapular nerve block in patients with chronic shoulder pain.

## Material and Methods

### Study design and study population

The institutional review board approved the study protocol in March 2019 (2018/1507). Following this, a retrospective review of data was obtained from the electronic medical follow-up record of patients who underwent glenohumeral joint intra-articular steroid injection and suprascapular nerve block±pulsed radiofrequency to the suprascapular nerve between October 2016 and April 2018. Informed consent was obtained from all study participants.

The inclusion criteria for the study were: Chronic shoulder pain (>3 months) and undergone interventional treatment due to inadequate response to conservative treatments.

The exclusion criteria for the study were: History of shoulder surgery, another intervention history between 3 months before and 1 year after the intervention applied, who had chronic pain syndrome other than shoulder pathology (fibromyalgia, cervical discopathy, brachial plexus injury, etc).

### Interventions

All procedures had been performed under the ultrasound guidance by a single and experienced pain specialist. All patients were monitored with electrocardiography, non-invasive blood pressure, and peripheral oxygen saturation and peripheral intravenous vascular access was performed before the procedure. Patients were placed in sitting positions. Mild sedation was achieved using 1–2 mg midazolam and 50–75 mcg fentanyl. The physician stood behind the patient for posterior approach. The skin area to be injected was prepared and covered in a sterile manner using a povidone-iodine-based solution. The operator used the Ultrasound (Esaote MyLab™Six, Genoa, Italy) guid-

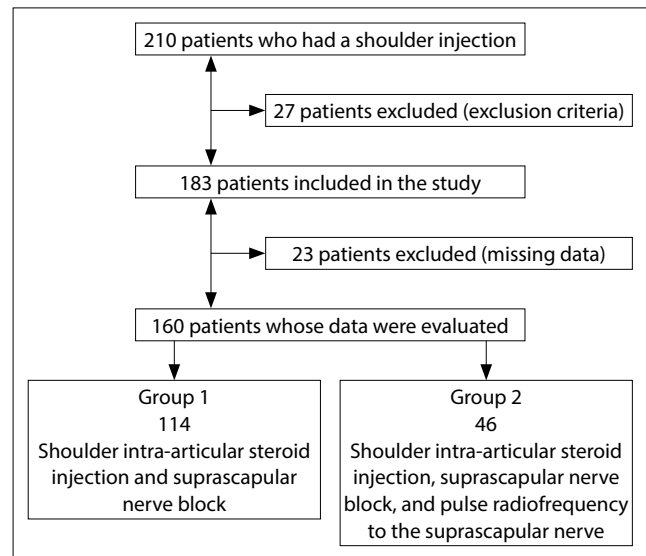
ance with high-frequency linear transducer (SL1543, 3–13 MHz) to perform shoulder joint injection.

For the glenohumeral joint steroid injection, probe was placed caudal and parallel to the lateral end of the scapular spine. The head of humerus, posterior glenoid rim, and labrum were visualized. Skin anesthesia was achieved by administering 1% lidocaine through a 25-G needle. Then, the 22 gauge Quincke type spinal needle (Egemen, Izmir, Türkiye) was directed until the subcapsular area with in-plane approach. After entering the glenohumeral joint, mixture of 1 ml 40 mg triamcinolone and 4 ml 0.5% bupivacaine was given to the intra-articular space. The suprascapular notch is then visualized by moving from medial to lateral on the scapular spine to apply the suprascapular nerve block. The pulsation of the suprascapular artery was visualized. The 22 gauge Quincke type spinal needle was introduced to the suprascapular notch and 10 ml 0.25% bupivacaine was given to perineurally.

In patients who were planned to undergo radiofrequency to the suprascapular nerve, the suprascapular notch is visualized in the same way after the glenohumeral intra-articular steroid injection. Twenty-two gauge, 10 cm long, and 5 mm active-tipped radiofrequency cannula (Cosman, Massachusetts, USA) was introduced to the suprascapular notch. Motor stimulation was performed at 2 Hz at a setting of 1 V and sensory stimulation was performed at 50 Hz at a setting of 0.5 V. After the needle tip confirmation, pulsed radiofrequency was applied to the suprascapular nerve for 240 s. At the end of the procedure, 10 ml 0.25 % bupivacaine was given perineurally for the suprascapular nerve block.

### Data collection

A retrospective data analysis was performed by both of the authors to collect the comprehensive data on clinical conditions: Name, age, sex, the technique performed, numerical rating scale (NRS; The patient is asked to make pain ratings: 0–10, with 0 being “no pain” and 10 being “the worst pain imaginable”) at two different time point: Pre-intervention and 1 month after the intervention, duration of pain relief (when the effect of the intervention was lost after the intervention), and satisfaction percentages of patients (They were asked to score between 0 and 100: 0 complete dissatisfaction and 100 full satisfaction) were collected.



**Figure 1.** Flow chart of patients.

### Statistical analysis

Statistical analysis was performed using the Statistical Package for the Social Sciences (SPSS) 21.0 software (IBM, Armonk, NY, USA). Descriptive statistics were defined as a number, percentage, median, and minimum-maximum. The consistency of continuous data with normal distribution was determined by the Kolmogorov–Smirnov and the Shapiro–Wilk test. Mann–Whitney U test was used in the comparisons between two groups of the variables in which the parametric assumptions were not met. Significance was evaluated at  $p < 0.05$ .

### Results

During the retrospective evaluation period, it was determined that the aforementioned shoulder procedures were applied to 210 patients. Among them, 27 patients were excluded because of exclusion criteria, and 23 patients were excluded because their data could not be accessed. As a result, 160 patients who underwent shoulder injections were included in the study (Fig. 1).

The patients included in the study were divided into two groups: 114 patients who underwent shoulder intra-articular steroid injection and suprascapular nerve block, as Group 1 and 46 patients who underwent pulse radiofrequency to the suprascapular nerve in addition to shoulder intra-articular steroid injection and suprascapular nerve block, as Group 2.

There is no statistical difference between the demographical data (age and sex) of the two groups (Table 1).

**Table 1.** Demographical data

	<b>Group 1 (n=114) Mean±SD</b>	<b>Group 2 (n=46) Mean±SD</b>	<b>p</b>
Age (years)	57.1±12.3	58.7±10.0	>0.05
Sex			
Male	36	13	>0.05
Female	78	33	

SD: Standard deviation.

The statistical results of the parameters examined in the study are summarized in Tables 2 and 3.

Pre-intervention NRS scores (median [min-max]) were found 8.0 (6.0–9.0) in Group 1 and 7.0 (6.0–9.0) in Group 2. There was no statistical difference between the groups in pre-intervention NRS scores ( $p>0.05$ ).

One month after the intervention, NRS scores (median [min-max]) were found 3.0 (0.0–8.0) in Group 1 and 1.0 (0.0–4.0) in Group 2. NRS scores of Group 2 were significantly lower than group 1 ( $p<0.05$ ).

The NRS scores of the patients 1 month after the intervention were found to be significantly lower than the values before the intervention within both groups ( $p<0.05$ ).

The duration of pain relief (median [min-max]) were 4.0 (2.0–14.0) months in Group 1 and 6.0 (3.0–14.0) months in Group 2. The duration of pain relief for Group 2 was statistically longer than group 1 ( $p<0.05$ ).

The satisfaction percentages of patients (median [min-max]) were 70 (30–100)% in Group 1 and 90 (50–100)% in Group 2. The satisfaction percentages of patients for Group 2 were statistically higher than Group 1 ( $p<0.05$ ).

## Discussion

Shoulder pain is one of the most common causes of musculoskeletal pain and may influence a patient’s daily life activities and work ability. Muscle tears or tendonitis, impingement syndromes, rheumatic diseases, bursitis, or arthritic changes can be counted among the causes of this pain. Many treatment alternatives can be applied in a conservative approach: Non-steroidal anti-inflammatory drugs,

**Table 2.** Comparison of Numerical Rating Scale (NRS) scores

	<b>Group 1 (n=114) median (min-max)</b>	<b>Group 2 (n=46) median (min-max)</b>	<b>p</b>
NRS pre-intervention	8.0 (6.0–9.0)	7.0 (6.0–9.0)	>0.05
NRS 1 month after the intervention	3.0 (0.0–8.0)	1.0 (0.0–4.0)	<b>&lt;0.05</b>
	<b>&lt;0.05</b>	<b>&lt;0.05</b>	

Mann-Whitney U test.

**Table 3.** Comparison of the duration of pain relief and satisfaction percentages of patients

	<b>Group 1 (n=114) Median (min-max)</b>	<b>Group 2 (n=46) Median (min-max)</b>	<b>p</b>
Duration of pain relief (months)	4.0 (2.0–14.0)	6.0 (3.0–14.0)	<b>&lt;0.05</b>
Satisfaction percentages of patients (%)	70 (30–100)	90 (50–100)	<b>&lt;0.05</b>

Mann-Whitney U test.

cold-hot applications, limiting activities that exacerbate discomfort, strengthening and resistance exercises, massage or manual mobilization, ultrasonography, laser therapy, transcutaneous electrical nerve stimulation, acupuncture, etc.<sup>[9]</sup>

If pain cannot be adequately relieved or quality of life cannot be improved with conservative treatments, interventional treatments are applied. Among these, steroid injections can be considered the oldest and still one of the most frequently used interventions. In the meta-analysis conducted by Sun et al.,<sup>[10]</sup> they concluded that while steroids gave better functional results in the shoulder than oral non-steroidal anti-inflammatories, there was no significant difference between them in terms of analgesic efficacy and complications. Steroid injections have been frequently tried, especially in patients with adhesive capsulitis. It was found to have similar efficacy with physiotherapy in these patients, and it was observed that they produced a stronger effect if they were applied together.<sup>[11,12]</sup> In the Cochrane review of Buch-

binder et al.,<sup>[13]</sup> in which they looked at corticosteroid injections in shoulder pain, it was seen that steroid injection in the shoulder provided a short-term and limited improvement.

Since steroids do not provide sufficient efficacy in some patients and the duration of action is generally short, alternatives have been the subject of interest. Taskaynatan et al.<sup>[14]</sup> compared the suprascapular block with steroid injection to the shoulder joint and reported that they were similarly effective. As a result, they concluded that due to suprascapular nerve block similar analgesic efficacy developed by avoiding many side effects that can be attributed to steroids. The suprascapular nerve block was applied in addition to some of the patients who were diagnosed with shoulder impingement syndrome and received subacromial steroid injection, and as a result, it was observed that when they were applied together, there was a much stronger effect and this effect was long-lasting.<sup>[15,16]</sup> In our study, suprascapular nerve block was applied to the patients in both groups with intra-articular steroid injection. As a result, a significant decrease was observed in the NRS scores of the patients after the intervention. This result seems to be compatible with the literature.

The main problem here is that the duration of action of both steroid injection and suprascapular nerve block is short.<sup>[17]</sup> Liliang et al.<sup>[18]</sup> applied pulse radiofrequency to the suprascapular nerve to increase the duration of the effect and reported that 6 months passed without any loss in the effect. In another study, it was showed that the application of pulse radiofrequency to the suprascapular nerve in addition to the suprascapular nerve block yielded better results in terms of NRS score and functional measurements.<sup>[19]</sup> In another study, 6-month pain relief was achieved by injecting steroids into the suprascapular nerve in addition to pulse radiofrequency application.<sup>[20]</sup>

In our retrospective analysis, we found that adding pulse radiofrequency to the suprascapular nerve in addition to intra-articular steroid injection and suprascapular nerve block resulted in a lower NRS score 1 month after the intervention. In addition, the application of pulse radiofrequency to the suprascapular nerve increased the median effect time from 4 to 6 months and patient satisfaction from 70% to 90%. Although the

current literature seems to be generally compatible with our results, some studies are not correlated with our study. For example, in a systematic review by Pushparaj et al.,<sup>[21]</sup> they reported that current evidence does not support the application of pulsed radiofrequency to the suprascapular nerve in terms of analgesic efficacy and functional benefit. Therefore, prospective and randomized studies to be conducted in patients with chronic shoulder pain with a specific etiology will provide us with clearer information on this subject.

### Limitations

Our study has several limitations: The most important one is the absence of a placebo group due to its retrospective design. We might have a better chance of reaching clearer results in patients with a specific cause of shoulder pain instead of general shoulder pain. We do not have data giving information in terms of functional recovery other than pain. This is an important limitation because functional improvement is as valuable as analgesia in shoulder pain.

### Conclusion

In addition to glenohumeral intra-articular steroid injection and suprascapular nerve block, pulse radiofrequency application to the suprascapular nerve provides more effective pain reduction, longer duration of pain relief action, and better patient satisfaction.

**Ethical Approval:** *The study was approved by The Istanbul University, Istanbul Faculty of Medicine Clinical Research Ethics Committee (Date: 15/03/2019, No: 2018/1507).*

**Conflict-of-interest issues regarding the authorship or article:** *None declared.*

**Financial Disclosure:** *This study has no funding or sponsor.*

**Peer-review:** *Externally peer-reviewed.*

### References

1. Linaker CH, Walker-Bone K. Shoulder disorders and occupation. *Best Pract Res Clin Rheumatol* 2015;29:405–23. [\[CrossRef\]](#)
2. Murphy RJ, Carr AJ. Shoulder pain. *BMJ Clin Evid* 2010;2010:1107.
3. Ginn KA, Cohen ML. Conservative treatment for shoulder pain: Prognostic indicators of outcome. *Arch Phys Med Rehabil* 2004;85:1231–5. [\[CrossRef\]](#)
4. Zheng XQ, Li K, Wei YD, Tie HT, Yi XY, Huang W. Nonsteroidal anti-inflammatory drugs versus corticosteroid for treatment of shoulder pain: A systematic review and meta-analysis. *Arch Phys Med Rehabil* 2014;95:1824–31. [\[CrossRef\]](#)



5. Brown DE, James DC, Roy S. Pain relief by suprascapular nerve block in gleno-humeral arthritis. *Scand J Rheumatol* 1988;17:411–5. [\[CrossRef\]](#)
6. Chang KV, Hung CY, Wu WT, Han DS, Yang RS, Lin CP. Comparison of the effectiveness of suprascapular nerve block with physical therapy, placebo, and intra-articular injection in management of chronic shoulder pain: A meta-analysis of randomized controlled trials. *Arch Phys Med Rehabil* 2016;97:1366–80. [\[CrossRef\]](#)
7. Haque R, Baruah RK, Bari A, Sawah A. Is suprascapular nerve block better than intra-articular corticosteroid injection for the treatment of adhesive capsulitis of the shoulder? A randomized controlled study. *Ortop Traumatol Rehabil* 2021;23:157–65. [\[CrossRef\]](#)
8. Vanneste T, Van Lantschoot A, Van Boxem K, Van Zundert J. Pulsed radiofrequency in chronic pain. *Curr Opin Anaesthesiol* 2017;30:577–82. [\[CrossRef\]](#)
9. Greenberg DL. Evaluation and treatment of shoulder pain. *Med Clin North Am* 2014;98:487–504. [\[CrossRef\]](#)
10. Sun Y, Chen J, Li H, Jiang J, Chen S. Steroid injection and nonsteroidal anti-inflammatory agents for shoulder Pain: A PRISMA systematic review and meta-analysis of randomized controlled trials. *Medicine (Baltimore)* 2015;94:e2216.
11. Ahmad Khan RD, Shahzad K, Khan S, Israr M, Zahid FM. Comparison of physiotherapy with and without intra-articular corticosteroid injection for treatment of frozen shoulder: A comparative study. *J Pak Med Assoc* 2021;71(Suppl 5):S17–S21.
12. Sun Y, Lu S, Zhang P, Wang Z, Chen J. Steroid injection versus physiotherapy for patients with adhesive capsulitis of the shoulder: A PRISMA systematic review and meta-analysis of randomized controlled trials. *Medicine (Baltimore)* 2016;95:e3469. [\[CrossRef\]](#)
13. Buchbinder R, Green S, Youd JM. Corticosteroid injections for shoulder pain. *Cochrane Database Syst Rev* 2003;2003:CD004016. [\[CrossRef\]](#)
14. Taskaynatan MA, Yilmaz B, Ozgul A, Yazicioglu K, Kalyon TA. Suprascapular nerve block versus steroid injection for non-specific shoulder pain. *Tohoku J Exp Med* 2005;205:19–25.
15. Yilmaz E. A prospective, comparative study of subacromial corticosteroid injection and subacromial corticosteroid injection plus suprascapular nerve block in patients with shoulder impingement syndrome. *Arch Orthop Trauma Surg* 2021;141:733–41. [\[CrossRef\]](#)
16. Jump CM, Waghmare A, Mati W, Malik RA, Charalambous CP. The impact of suprascapular nerve interventions in patients with frozen shoulder: A systematic review and meta-analysis. *JBJS Rev* 2021;9. [\[CrossRef\]](#)
17. Haque R, Baruah RK, Bari A, Sawah A. Is suprascapular nerve block better than intra-articular corticosteroid injection for the treatment of adhesive capsulitis of the shoulder? A randomized controlled study. *Ortop Traumatol Rehabil* 2021;23:157–65. [\[CrossRef\]](#)
18. Liliang PC, Lu K, Liang CL, Tsai YD, Hsieh CH, Chen HJ. Pulsed radiofrequency lesioning of the suprascapular nerve for chronic shoulder pain: A preliminary report. *Pain Med* 2009;10:70–5. [\[CrossRef\]](#)
19. Gofeld M, Restrepo-Garces CE, Theodore BR, Faclier G. Pulsed radiofrequency of suprascapular nerve for chronic shoulder pain: A randomized double-blind active placebo-controlled study. *Pain Pract* 2013;13:96–103. [\[CrossRef\]](#)
20. Sinha P, Sarkar B, Goswami S, Ray Karmakar P, Dasgupta SR, Basu S. Effectiveness of combination of ultrasonography-guided pulsed radiofrequency neuromodulation with steroid at the suprascapular nerve in chronic shoulder pain. *Pain Pract* 2020;20:16–23. [\[CrossRef\]](#)
21. Pushparaj H, Hoydonckx Y, Mittal N, Peng P, Cohen SP, Cao X, et al. A systematic review and meta-analysis of radiofrequency procedures on innervation to the shoulder joint for relieving chronic pain. *Eur J Pain* 2021;25:986–1011. [\[CrossRef\]](#)