



Regional anaesthesia in a Duchenne muscular dystrophy patient for upper extremity amputation

Duchenne musküler distrofili hastada üst ekstremité amputasyonu için bölgesel anestezi

Mehmet İlke BÜGET,¹ İlker EREN,² Süleyman KÜÇÜKAY¹



Summary

Duchenne muscular dystrophy (DMD) is the most common of the neuromuscular disorders. DMD is usually a challenge for the anaesthesiologist, with poor cardiac function, a high risk of developing rhabdomyolysis, and the probable life-threatening complications of general anaesthesia. To avoid possible morbidity associated with general anaesthesia, we applied a supraclavicular blockade. In this report, we present a 17-year-old DMD patient with a massive rhabdomyosarcoma, for whom a left arm amputation was indicated. In the post-operative period, a malignant hyperthermia-like reaction occurred, which resolved in a short time. We suggest a regional blockade as a safer alternative to general anaesthesia for the management of high risk DMD patients during orthopedic procedures.

Key words: Amputation; Duchenne; muscular dystrophy; regional anaesthesia.

Özet

Duchenne musküler distrofisi, (DMD) nöromusküler hastalıklar arasında en sık görülen rahatsızlıktır. Ciddi kardiyak rahatsızlıklar, yüksek rabdomyoliz gelişme ihtimali ve genel anestezinin hayati risk olasılığı yüksek komplikasyonlarıyla, DMD, anestezi uzmanları için genellikle sıkıntı oluşturmaktadır. Genel anesteziyle ilişkili muhtemel morbiditeden kaçınmak için hastamızda supraklaviküler blok uyguladık. Bu raporda, masif rabdomyosarkomu olan ve amputasyon endikasyonu mevcut olan, 17 yaşındaki Duchenne'li bir hastayı sunmayı amaçladık. Ameliyat sonrası dönemde, kısa süre içinde geçen, malign hipertermi benzeri bir reaksiyon gelişimini tespit ettik. Biz ortopedik cerrahi geçirecek DMD'li hastalarda genel anesteziye güvenli bir alternatif olarak rejyonel anestezi uygulamalarını önermekteyiz.

Anahtar Kelimeler: Amputasyon; Duchenne; musküler distrofi; rejyonel anestezi.

Introduction

Duchenne muscular dystrophy (DMD) is the most common disease among neuromuscular disorders. It is X linked and seen one in every 3500 male.^[1] Death most frequently occurs in the second decade mostly due to respiratory (90%) and cardiac (10%) complications.^[1] Respiratory failure, pulmonary aspiration, atelectasis, pneumonia, congestive heart failure, and

cardiac arrhythmia are the possible complications associated with DMD during the operation period. The limited ability of the patients to augment cardiac output, in order to respond sufficiently to surgical stress, is a danger to adequate oxygen delivery.^[2] Probable blood losses and fluid shifts during major surgeries also attenuate cardiac output and sufficient oxygen delivery.^[3] DMD patients are at constant

¹Department of Anesthesiology, Istanbul University Istanbul Faculty of Medicine, Istanbul, Turkey;

²Department of Orthopaedics and Traumatology, Istanbul University Istanbul Faculty of Medicine, Istanbul, Turkey

Istanbul Üniversitesi İstanbul Tıp Fakültesi, Anesteziyoloji Anabilim Dalı, İstanbul;

Istanbul Üniversitesi İstanbul Tıp Fakültesi, Ortopedi ve Travmatoloji Anabilim Dalı, İstanbul

Submitted (Başvuru tarihi) 07.02.2013 Accepted after revision (Düzeltilme sonrası kabul tarihi) 14.02.2013

Correspondence (İletişim): Dr. Mehmet İlke Büget. İstanbul Üniversitesi İstanbul Tıp Fakültesi, Ortopedi ve Travmatoloji Anabilim Dalı, Çapa, Fatih, İstanbul, Turkey.

Tel: +90 - 212 - 414 20 00 / 31742 e-mail (e-posta): mbuget@yahoo.com

risk of encountering complications within the operation period.^[4,5] For that reason, the management of a DMD patient always requires multidisciplinary approach.

We present a 17 year old Duchenne patient with a huge rhabdomyosarcoma in his left arm (Figure 1a, b). In this patient, amputation of the arm was indicated surgically and we decided to apply a supraclavicular blockade for the anesthesia.

Case Report

A 17 year old DMD patient was presented in this

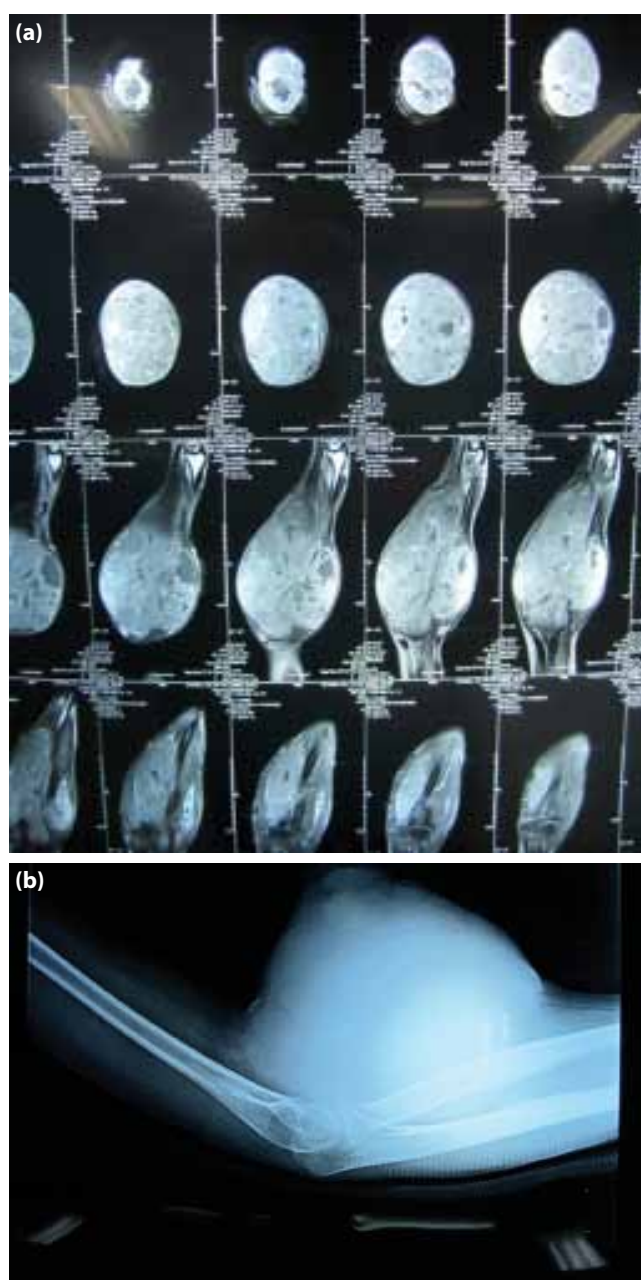


Figure 1. (a, b) Radiological images of the rhabdomyosarcoma.

report. He was operated for a massive rhabdomyosarcoma (Figure 2a). In his echocardiography, dilated cardiomyopathy, mitral regurgitation and ejection fraction of 23% were detected. His pulmonary function tests revealed a FEV1: 82%, FVC: 68%, and FEV1/FVC: 116%. In his blood testing, creatin kinase (CK) was 1420 U/L and electrolyte levels were within the normal range. We decided to perform a supraclavicular block with a nerve stimulator for anesthesia of the patient. A skin wheal was raised with 1% lidocaine. After appropriate twitches for the brachial plexus were elicited, 30 ml 0.5% bupivacaine without any additives was injected for the block. Twenty minutes later, motor and sensory blockade was satisfactory in the entire arm. He was breathing spontaneously with a face mask (SpO₂ 99%), with a heart rate (HR) of 88/min and blood pressure (BP) of 110/77 mmHg. Following the confirmation of block success, the operation was initiated. The patient was prepared and draped in a standard fashion, leaving the entire upper extremity free. In order to avoid contamination from actively bleeding exulcerated mass (Figure 2b), arm distal to the elbow covered. Dissection was performed leaving equal anterior and posterior skin flaps. Brachial artery and vein were doubly ligated. Median, ulnar and radial nerves were transected from a more proximal level and let retract. All muscular tissues were severely atrophic, almost without any contractible part. Bone was divided with an oscillating saw, and rasped to achieve smooth end. Leaving a drain inside, posterior and anterior flaps were sutured and skin was closed. The total duration of the operation was 2 hours and we did not observe any problems within this period.

He was taken into ICU for close monitoring, breathing spontaneously, with SpO₂:100%, BP: 100/70 mmHg and HR: 85/min. In the third post-operative hour fever of 39° C was detected in our patient. A face mask was applied for oxygen; paracetamol 1g was administered intravenously, whereas cold compression was applied immediately. His blood gas analysis revealed values within normal ranges. Acidosis, hyperkalemia and CO₂ rise were not present. Creatine level, urine output and blood count were also normal. Within 3 hours, the fever declined gradually and tachycardia also disappeared.

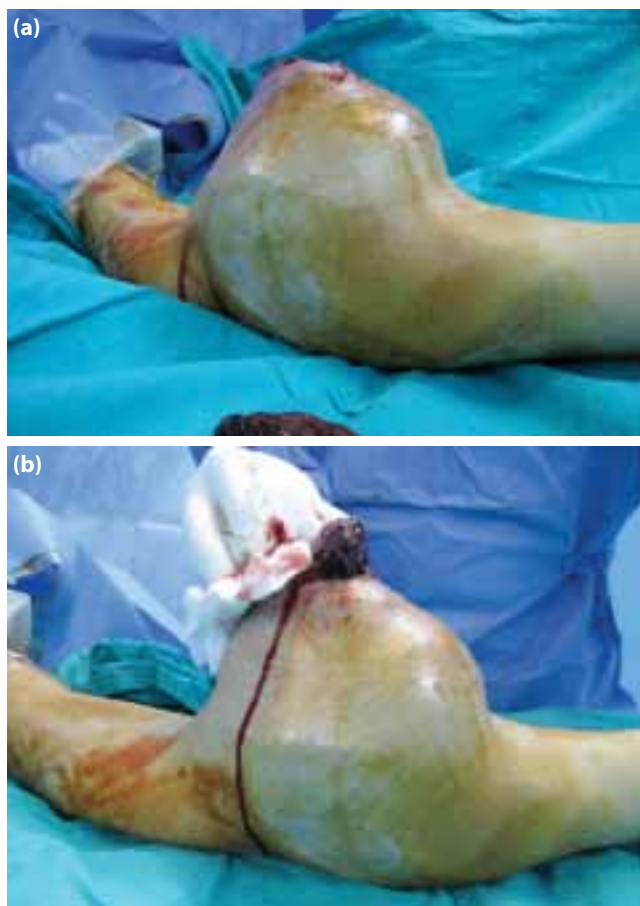


Figure 2. (a) Huge rhabdomyosarcoma. (b) Bleeding mass.

His CK levels were elevated to 5420 U/L. In the second post-operative day, CK levels decreased to 2110 U/L and he did not demonstrate any symptoms. He was discharged in the third post-operative day.

Discussion

DMD is caused by an X-chromosome linked recessive mutation that prevents normal formation of a muscle-stabilizing protein, named dystrophin and loss of dystrophin leads to muscular dystrophy.^[6]

In this report, our patient's left arm was amputated because of a massive rhabdomyosarcoma occupying his arm. Considering his poor cardiac function and increased risk of rhabdomyolysis, we decided to perform a supraclavicular blockade instead of general anesthesia.

In the literature, there exist many cases of complications due to general anesthesia^[7-9] in DMD patients. Exposure to volatile anesthetic agents can induce rhabdomyolysis and malignant hyperthermia-like

reactions, which in turn may cause cardiac arrest, even death.^[6,10] The perioperative use of succinylcholine is also contraindicated because of the risk of rhabdomyolysis, hyperkalemia, and cardiac arrest.^[10] In order to avoid these risks, succinylcholine should not be used; and volatile anesthetics should be used caution if necessary. Whenever possible, potential trigger free anesthetics, such as total intravenous anesthesia (TIVA) and a 'clean' anesthesia machine should be used.^[11] We thought regional anesthesia can be a relatively safe option compared to general anesthesia, provided that the surgical site is appropriate for the technique. Çalışkan et al reported an uneventful spinal anesthesia for a DMD patient and suggested regional anesthesia whenever possible.^[12] Unlike their experience which ended uneventfully, our case developed malignant hyperthermia (MH) like reaction in the third post-operative hour. For oxygen delivery, a face mask was used, and this face mask circuit was taking its roots from the anesthesia machine. Although the machine was cleaned for 30 min before the operation, a residue of an agent might cause this reaction, as the amount of volatile residue that can cause the reaction is unknown.^[11] In his report Hayes et al. categorized the MH like clinical presentations into three groups: Acute onset of hyperkalemic cardiac arrest, postoperative rhabdomyolysis without cardiac arrest and gradual rise in temperature and heart rate group.^[11] Our case can be an example of the latter group, although our case differs in terms of the regional anesthesia applied and anesthetic agents avoided. In the literature, 7 patients had tachycardia and hyperthermia occurred within a few hours of anesthesia and resolved spontaneously.^[13]

In this case, we used a nerve stimulator to determine the injection point, because there is no evidence in the literature that stimulation of a muscle can raise extracellular potassium levels.^[14] Thus, we did not notice any alterations in our patient's potassium levels during the follow up.

DMD is associated with the weakness of the diaphragm, intercostal muscles, and other respiratory accessory muscles, depending on this restrictive pulmonary insufficiency and a progressive decline in lung capacity develops.^[15] Beside, DMD patients are at risk of respiratory failure which is caused by

muscle weakness leading to hypoventilation and insufficient cough leading to ineffective airway secretion clearance.^[16] Our major concern with supraclavicular block was the possibility of developing hemidiaphragmatic paralysis (HDP) after the block, which occurs unpredictably and makes the block not recommended in patients who are not capable of tolerating a 30% decline in pulmonary function.^[17] In a study evaluating HDP after supraclavicular blockade, the author demonstrated a lower incidence of HDP when compared to interscalene blockade (50% and 100%, respectively).^[18] Although hemidiaphragmatic paresis may develop in some patients after supraclavicular block, its duration was shorter than observed following sensory and motor block and was not associated with a significant respiratory impairment in patients without any co-morbidity.^[18] We used supraclavicular blockade in this case because it covered the surgical field and had a lower incidence of HDP than which the interscalene approach had. Although DMD patients have generally serious restrictive pulmonary impairment, our patient's pulmonary reserve was sufficient for a 30% decline. In our case, we did not detect any respiratory impairment and it was unlikely that the patient had HDP.

Pneumothorax was another possible complication for the supraclavicular blockade. In literature, the overall incidence of pneumothorax associated with supraclavicular block was between 0.5%-6%, when the needle was guided towards the apical pleura.^[17] However, these numbers are slightly overemphasized, given that different approaches such as the plumb-bob and subclavian perivascular approaches diminish the risk of pneumothorax significantly.^[19] Consistent with previous findings, we did not observe pneumothorax in our patient after our blockade.

Among DMD patients, cardiomyopathy is common. It is suggested that, by the second decade, (80-90%) most of the patients will have a dilated cardiomyopathy detected in echocardiography and half of them will have clinical heart failure.^[20] DMD patients are at increased risk for perioperative congestive heart failure and cardiac arrhythmia; they have a limited ability to increase cardiac output in response to stress. Fluid boluses or blood transfu-

sions may cause intravascular fluid imbalance.^[15] In our case, although our patient had a serious heart failure, peripheral nerve blockade did not cause any negative hemodynamic effects, as expected. Careful fluid management reduced the risk of fluid imbalance.

Although regional anesthesia is a good alternative to general anesthesia in DMD patients, our case demonstrated a possible MH- like reaction, even with regional anesthesia. Close monitoring and strict follow up are essential both in the perioperative and postoperative period.

Conflict-of-interest issues regarding the authorship or article: None declared.

Peer-review: Externally peer-reviewed.

References

1. Morris P. Duchenne muscular dystrophy: a challenge for the anaesthetist. *Paediatr Anaesth* 1997;7(1):1-4. [CrossRef](#)
2. American Academy of Pediatrics Section on Cardiology and Cardiac Surgery. Cardiovascular health supervision for individuals affected by Duchenne or Becker muscular dystrophy. *Pediatrics* 2005;116(6):1569-73. [CrossRef](#)
3. Noordeen MH, Haddad FS, Muntoni F, Gobbi P, Hollyer JS, Bentley G. Blood loss in Duchenne muscular dystrophy: vascular smooth muscle dysfunction? *J Pediatr Orthop B* 1999;8(3):212-5. [CrossRef](#)
4. Girshin M, Mukherjee J, Clowney R, Singer LP, Wasnick J. The postoperative cardiovascular arrest of a 5-year-old male: an initial presentation of Duchenne's muscular dystrophy. *Paediatr Anaesth* 2006;16(2):170-3. [CrossRef](#)
5. Schmidt GN, Burmeister MA, Lilje C, Wappler F, Bischoff P. Acute heart failure during spinal surgery in a boy with Duchenne muscular dystrophy. *Br J Anaesth* 2003;90(6):800-4.
6. Gurnaney H, Brown A, Litman RS. Malignant hyperthermia and muscular dystrophies. *Anesth Analg* 2009;109(4):1043-8. [CrossRef](#)
7. Irwin MG, Henderson M. Cardiac arrest during major spinal scoliosis surgery in a patient with Duchenne's muscular dystrophy undergoing intravenous anaesthesia. *Anaesth Intensive Care* 1995;23(5):626-9.
8. Smelt WL. Cardiac arrest during desflurane anaesthesia in a patient with Duchenne's muscular dystrophy. *Acta Anaesthesiol Scand* 2005;49(2):267-9. [CrossRef](#)
9. Reid JM, Appleton PJ. A case of ventricular fibrillation in the prone position during back stabilisation surgery in a boy with Duchenne's muscular dystrophy. *Anaesthesia* 1999;54(4):364-7. [CrossRef](#)
10. Birnkrant DJ. The American College of Chest Physicians consensus statement on the respiratory and related management of patients with Duchenne muscular dystrophy undergoing anesthesia or sedation. *Pediatrics* 2009;123 Suppl 4:242-4. [CrossRef](#)
11. Hayes J, Veyckemans F, Bissonnette B. Duchenne muscular dystrophy: an old anesthesia problem revisited. *Paediatr An-*

- aesth 2008;18(2):100-6.
12. Caliskan E, Sener M, Kocum A, Aribogan A. Duchenne muscular dystrophy: how I do it? Regional or general anesthesia? *Paediatr Anaesth* 2009;19(6):624-5. [CrossRef](#)
 13. Larsen UT, Juhl B, Hein-Sørensen O, de Fine Olivarius B. Complications during anaesthesia in patients with Duchenne's muscular dystrophy (a retrospective study) *Can J Anaesth* 1989;36(4):418-22. [CrossRef](#)
 14. Ames WA, Hayes JA, Crawford MW. The role of corticosteroids in Duchenne muscular dystrophy: a review for the anesthetist. *Paediatr Anaesth* 2005;15(1):3-8. [CrossRef](#)
 15. Birnkrant DJ, Panitch HB, Benditt JO, Boitano LJ, Carter ER, Cwik VA, et al. American College of Chest Physicians consensus statement on the respiratory and related management of patients with Duchenne muscular dystrophy undergoing anesthesia or sedation. *Chest* 2007;132(6):1977-86. [CrossRef](#)
 16. Kravitz RM. Airway clearance in Duchenne muscular dystrophy. *Pediatrics* 2009;123 Suppl 4:231-5. [CrossRef](#)
 17. Neal JM, Gerancher JC, Hebl JR, Ilfeld BM, McCartney CJ, Franco CD, et al. Upper extremity regional anesthesia: essentials of our current understanding, 2008. *Reg Anesth Pain Med* 2009;34(2):134-70. [CrossRef](#)
 18. Neal JM, Moore JM, Kopacz DJ, Liu SS, Kramer DJ, Plorde JJ. Quantitative analysis of respiratory, motor, and sensory function after supraclavicular block. *Anesth Analg* 1998;86(6):1239-44. [CrossRef](#)
 19. Brown DL, Cahill DR, Bridenbaugh LD. Supraclavicular nerve block: anatomic analysis of a method to prevent pneumothorax. *Anesth Analg* 1993;76(3):530-4. [CrossRef](#)
 20. Hsu DT. Cardiac manifestations of neuromuscular disorders in children. *Paediatr Respir Rev* 2010;11(1):35-8. [CrossRef](#)