



Ultrasound-guided psoas compartment block and general anesthesia for arthroscopic knee surgery: a case report

Artroskopik diz cerrahisi için genel anestezi ve ultrason rehberliğinde psoas kompartman blok uygulaması: Olgu sunumu

Emine Aysu ŞALVIZ,¹ Yavuz GÜRKAN,² Murat TEKİN,² Levent BULUÇ³



Summary

Anesthetizing the lumbar plexus at its origin facilitates a more "complete" psoas compartment block compared to peripheral approaches. It is usually performed using surface anatomical landmarks, and the site for local anesthetic injection is confirmed by observing quadriceps muscle contraction to peripheral nerve stimulation. Ultrasound may provide guidance alone or together with the aid of nerve stimulation during nerve blocks. We present a 48-year-old male patient, American Society of Anesthesiologists (ASA) physical status II, who refused spinal anesthesia, and underwent knee arthroscopy with ultrasound-guided psoas compartment block and general anesthesia. Following the standard monitoring and lateral decubitus positioning, the vertebral body, psoas, erector spinae, and quadratus lumborum muscles and hyperechoic nerve roots of the patient were visualized at the level of L4-5 with curvilinear ultrasound probe. The needle was inserted with ultrasound guidance, and correct tip position was confirmed with quadriceps contraction. Then, the mixture of 30 mL local anesthetic (10 mL 2% lidocaine and 20 mL 5% levobupivacaine) was injected at the estimated position of the lumbar plexus (junction of the posterior third and anterior two-thirds of the psoas muscle). He also received general anesthesia for the surgery. Anesthesia and surgical procedures were completed successfully without any additional anesthetic/analgesic requirement or complication. The postoperative period was pain-free both at rest and during mobilization for 24 hours. This case report shows that ultrasound-guided psoas compartment block is feasible and efficient for peri- and postoperative analgesia during knee arthroscopy.

Key words: Knee arthroscopy; psoas compartment block; ultrasound.

Özet

Psoas kompartman bloğu, lumbar pleksusun kökler hizasında bloke edilmesi sebebiyle periferik yaklaşımlara göre daha tam bir blok- tur. Genellikle yüzeysel anatomik işaret noktaları kullanılarak blok lokalizasyonu belirlenir ve lokal anestetik enjeksiyonu periferik sinir stimülatörü ile kuadriseps kasının kontraksiyonu görülerek uygulanır. Ultrason sinir bloklarında tek başına veya sinir stimülatör- ü yardımı ile rehberlik sağlayabilir. Biz, bu yazıda spinal anestezi girişimini reddeden, genel anestezi ve ultrason rehberliğinde psoas kompartman bloğu altında diz artroskopik cerrahisi geçiren, 48 yaşında, ASA II, erkek hasta ile ilgili deneyimimizi sunduk. Hastaya standart monitorizasyon uygulandı ve lateral dekübit pozisyon verilmesi sonrasında vertebra, psoas, erektor spina and kuadratus lumborum kasları L4-5 seviyesinde konveks prob ile gözlemlendi. İğne ultrason rehberliğinde ilerletildi ve iğne ucunun lokalizasyonu kuadriseps kas kontraksiyonu ile doğrulandı. Otuz mL lokal anestetik karışımının (10 mL %2'lik lidokain ve 20 mL %5'lik levobupivakain) lumbar pleksus etrafına enjekte edilmesinin ardından hastaya genel anestezi uygulandı. Anestezi ve cerrahi işlem ek anestetik/analjezik ihtiyacı veya komplikasyon olmaksızın başarıyla tamamlandı. Hastanın ameliyat sonrası dönemde istirahat- ta da mobilizasyonda ilk 24 saatte ağrı şikayeti olmadı. Bu olgu sunumu, ultrason rehberliğinde psoas kompartman bloğunun diz artroskopik cerrahisinde ameliyat esnası ve sonrası analjezi için uygun ve etkin bir yöntem olduğunu göstermektedir.

Anahtar sözcükler: Diz artroskopisi; psoas kompartman bloğu; ultrason.

¹Department of Anesthesiology and Reanimation, Şanlıurfa Training and Research Hospital, Şanlıurfa;

²Department of Anesthesiology and Reanimation, Kocaeli University Faculty of Medicine, Kocaeli;

³Department of Orthopedics and Traumatology, Kocaeli University Faculty of Medicine, Kocaeli

¹Şanlıurfa Eğitim ve Araştırma Hastanesi, Anesteziyoloji ve Reanimasyon Kliniği, Şanlıurfa;

²Kocaeli Üniversitesi Tıp Fakültesi, Anesteziyoloji ve Reanimasyon Anabilim Dalı, Kocaeli;

³Kocaeli Üniversitesi Tıp Fakültesi, Ortopedi ve Travmatoloji Anabilim Dalı, Kocaeli

Submitted (Başvuru tarihi) 24.02.2012 Accepted after revision (Düzeltilme sonrası kabul tarihi) 15.06.2012

Correspondence (İletişim): Dr. Emine Aysu Şalvız. İstanbul Üniversitesi, İstanbul Tıp Fakültesi, Anesteziyoloji ve Reanimasyon Anabilim Dalı, Çapa, İstanbul, Turkey.

Tel: +90 - 212 - 414 20 00 e-mail (e-posta): aysusalviz@gmail.com

Current affiliation / Şimdiki kurumu:

¹Department of Anesthesiology and Reanimation, İstanbul University İstanbul Faculty of Medicine, İstanbul;

¹İstanbul Üniversitesi İstanbul Tıp Fakültesi, Anesteziyoloji ve Reanimasyon Anabilim Dalı, İstanbul

Introduction

The psoas compartment block (PCB) technique is useful in anesthetizing the lumbar plexus at its origin. Successfully placing local anesthetic (LA) at the level of the lumbar plexus roots (junction of the posterior third and the anterior two-thirds of the psoas muscle) is a more “complete” method compared to peripheral approaches.^[1-4] It provides the blockade of the femoral, obturator and lateral cutaneous nerves of the thigh with a single injection.^[3-5] Therefore, it may be used for anesthesia and analgesia of anterior, medial, and lateral procedures of the thigh such as skin grafts and femoral osteotomy, total knee replacement,^[6] total hip replacement,^[7,8] hip fractures,^[9,10] knee arthroscopy,^[11] anterior and posterior cruciate ligament reconstructions^[12] and chronic hip pain.^[13]

The PCB technique is traditionally performed using surface anatomical landmarks and observing quadriceps muscle contraction to peripheral nerve stimulation.^[3] Lately, there has been a rise in the use of ultrasound to visualize the sonoanatomy of lumbar plexus and to guide the PCBs. Ultrasound-guided regional anesthetic techniques of the lower limb can be challenging because of the muscles and fat which surround the nerves,^[5,14] however technological improvements of ultrasound equipment have allowed better visualization of the nerves and the other anatomical structures. The lumbar plexus and the posterior part of the psoas muscle, although deep, were examined in cadavers and just in a few cases successfully.^[1,3,15,16] We present a case, who underwent a knee arthroscopy with successful ultrasound-guided PCB and general anesthesia.

Case Report

A 48-year-old male, ASA physical status II patient with hypertension was scheduled for knee arthroscopy procedure. Patient history revealed that, the patient had undergone appendectomy, nephrolithiasis operations under general anesthesia and knee arthroscopy, hallux valgus, hemorrhoid operations under spinal anesthesia. Moreover, he had had coronary angiography twice by the reason of chest pain and hypertension, and got normal results. No abnormalities were noted on his preoperative blood tests, chest X-ray and physical examination. In order

to provide a more complete anesthesia and analgesia for this patient, who refused to undergo spinal anesthesia, an ultrasound-guided PCB and general anesthesia was planned.

On arrival to the holding area where blocks were performed, standard monitoring (pulse-oxymetry, heart rate (HR), noninvasive blood pressure (NIBP) and ECG) was applied. A 20-gauge intravenous (IV) cannula was placed on the right hand of the patient and a free running infusion of saline was started. Oxygen 2 L/h was applied via mask. Sedation was provided with 3 mg IV midazolam after the lateral decubitus position with the left operative side up, the hips and the knees flexed. After disinfection and sterile draping, sterile gel was applied to the procedure area. A low frequency curvilinear ultrasound probe (1-8 MHz, Esaote My Lab 30, Genoa, Italy) was placed at the level of L4-5 in the transverse plane (Figure 1). Vertebral body, articular process, psoas, erector spina, and quadratus lumborum muscles were visualized (Figure 2). After LA skin infiltration, a 22-gauge 100 mm insulated needle (Pajunk, Geisingen, Germany) was inserted lateral to the probe, using in-plane technique. The correct tip position was confirmed with quadriceps contraction at 8 cm by neurostimulator 0.5 mA. Then, LA mixture of 30 mL (10 mL 2% lidocaine and 20 mL 5% levobupivacaine) was injected incrementally in fractionated doses with frequent aspiration to detect any possible intravascular puncture. The LA spread was observed on transverse axis scan.

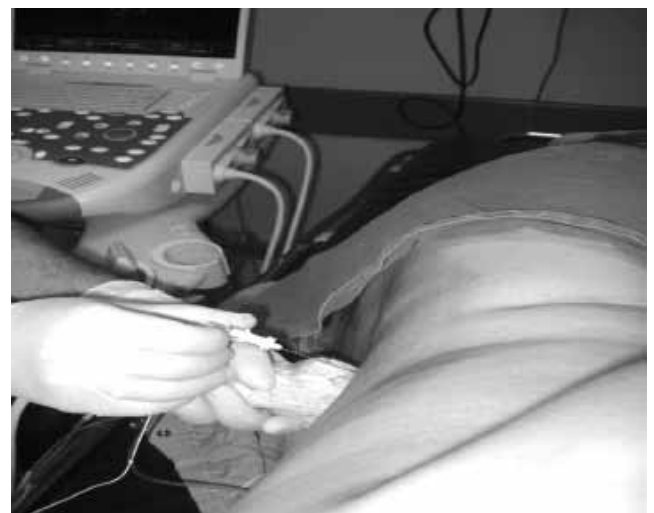

Figure 1. A low frequency curvilinear ultrasound probe was placed at the level of L4-5 in the transverse plane while the patient is placed in the right lateral decubitus position.

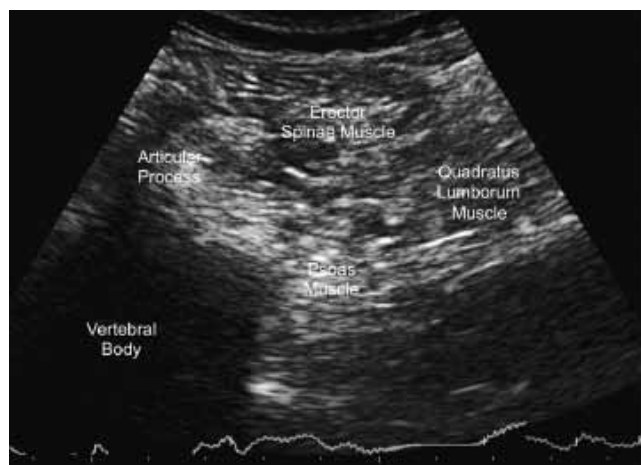


Figure 2. The vertebral body, articular process, psoas, erector spina, and quadratus lumborum muscles of the patient were visualized with a low frequency curvilinear ultrasound probe.

Successful block was confirmed in 20 minutes by decreased sensation in terminal nerves of the lumbar plexus (femoral, lateral femoral cutaneous, and obturator) and quadriceps weakness.

Then, the patient was taken to the operating room. Following the application of standard monitoring and obtaining normal vital signs, general anesthesia was induced with propofol 2.5 mg kg^{-1} and fentanyl $1 \text{ } \mu\text{g kg}^{-1}$ iv. Laryngeal mask (number 4) was placed for airway protection and anesthesia was then maintained with 1.5-2% sevoflurane in N_2O and O_2 (1:1 ratio). Knee arthroplasty and anesthesia procedures were successfully completed within 50 minutes without any additional anesthetic/analgesic requirement. Diclofenac 75 mg was ordered as a rescue analgesic that could be repeated every 6 h with a maximum daily dose of 300 mg.

The patient was discharged on the next day. He was very pleased because of pain free postoperative period both at rest and during mobilization, and his analgesic consumption was 0 during the postoperative first 24 hours.

Discussion

Knee arthroscopy is one of the most commonly performed elective ambulatory orthopedic procedures and associated with moderate to severe, often poorly controlled, postoperative pain.^[4,17] Various types of anesthesia including neuraxial blocks, general, and peripheral nerve blocks have been performed

for these procedures.^[18-21] Central neuraxial blocks and general anesthesia provide effective anesthesia, however neuraxial blocks cause nausea/emesis, urinary retention, post-dural puncture, hemodynamic changes, motor weakness in the lower extremity and on the other hand general anesthesia is reported with high postoperative pain scores, and low satisfaction ratings.^[4,12] However, peripheral nerve blocks have advantages of providing limb-specific anesthesia/analgesia without extended muscle weakness, allowing early ambulation, enabling effective physiotherapy and early discharge.^[4,22,23]

Although femoral nerve block is easy to perform, the obturator and lateral femoral cutaneous nerves are not consistently blocked with this technique.^[24] On the other hand, the lumbar plexus is made up of the L1 through L5 spinal nerve roots. As the roots of the lumbar plexus depart from their spinal nerves and emerge from the intervertebral foramen, they enter the posterior third or junction of the posterior third and the anterior two-thirds of the psoas muscle.^[1-4,25] In contrast to the femoral approach, the PCB reliably produces blockade of the entire lumbar plexus with high success rate.^[14,24] Therefore, PCB with general anesthesia was chosen to provide complete peri-/post-operative analgesia and anesthesia during our clinical practice.

To reach the lumbar plexus by surface anatomical landmarks is useful but can vary among patients. Several techniques as loss of resistance, elicitation of paresthesia, and quadriceps muscle contraction to nerve stimulation have been described at different levels using surface anatomical landmarks in the literature.^[2,9,16,24,26,27] However, epidural spread of the LA, systemic toxicity, renal hematoma, total spinal anesthesia and circulatory cases have been reported as complications of these approaches.^[28-33] These complications are usually related with failed or multiple attempts, or inadvertent vascular injuries.^[33] With the use of ultrasound for imaging of the individual anatomy and real-time needle guidance, the efficacy of the PCB might be increased and such complications might be avoided.^[16]

Ultrasound guidance during PCB may offer several advantages compared to the traditional methods. The related anatomy and target structures are clearly

identified, the advancement of the needle to the posterior part of the psoas muscle and meanwhile the spread of the LA during the injection can be observed.^[2,3,32] This may allow the anesthesiologist to perform the PCB safely and successfully. Furthermore, two different techniques of ultrasound-guided PCB as transverse and longitudinal approaches have been described.^[1,3,16,17] Longitudinal technique may cause bilateral spread and systemic LA toxicity because of the rapid absorption of large volumes or inadvertent injection into one of the large paravertebral blood vessels.^[5] Therefore, we preferred transverse technique and were able to visualize the kidney, vertebral body, spinous, articular, and transverse processes, psoas, erector spina and quadratus lumborum muscles clearly in order to perform a successful block and avoid the puncture.

Our observation of the lumbar plexus location in the posterior part of the psoas muscle was coherent with the previous data.^[2,3] The location of the plexus and the tip of the needle were confirmed both by ultrasound and nerve stimulator. The block was successfully completed after one attempt. Paresthesia, blood aspiration or injury to surrounding structures were not noted during the procedure.

As a result, this case report describes that a successful ultrasound guided PCB technique provides a pain free peri-/post-operative period without any additional anesthetic or analgesic. This shows that ultrasound-guided PCB is a feasible and efficient technique for knee arthroscopy. In spite of the impressive cadaver study and case report results, the published prospective investigations are limited. Further studies are necessary to evaluate the rate of success, safety and efficacy of the ultrasound guided PCB technique.

Conflict-of-interest issues regarding the authorship or article: None declared.

Peer-review: Externally peer-reviewed.

References

- Kirchmair L, Entner T, Wissel J, Moriggl B, Kapral S, Mitterschiffthaler G. A study of the paravertebral anatomy for ultrasound-guided posterior lumbar plexus block. *Anesth Analg* 2001;93(2):477-81. [CrossRef](#)
- Farny J, Drolet P, Girard M. Anatomy of the posterior approach to the lumbar plexus block. *Can J Anaesth* 1994;41(6):480-5.
- Karmakar MK, Ho AM, Li X, Kwok WH, Tsang K, Ngan Kee WD. Ultrasound-guided lumbar plexus block through the acoustic window of the lumbar ultrasound trident. *Br J Anaesth* 2008;100(4):533-7. [CrossRef](#)
- Greengrass RA. Posterior lumbar plexus block. *Tech Reg Anesth Pain Manag* 2003;7(1):3-7. [CrossRef](#)
- Marhofer P, Harrop-Griffiths W, Willschke H, Kirchmair L. Fifteen years of ultrasound guidance in regional anaesthesia: Part 2-recent developments in block techniques. *Br J Anaesth* 2010;104(6):673-83. [CrossRef](#)
- Luber MJ, Greengrass R, Vail TP. Patient satisfaction and effectiveness of lumbar plexus and sciatic nerve block for total knee arthroplasty. *J Arthroplasty* 2001;16(1):17-21. [CrossRef](#)
- Capdevila X, Macaire P, Dadure C, Choquet O, Biboulet P, Ryckwaert Y, et al. Continuous psoas compartment block for postoperative analgesia after total hip arthroplasty: new landmarks, technical guidelines, and clinical evaluation. *Anesth Analg* 2002;94(6):1606-13. [CrossRef](#)
- Türker G, Uçkunkaya N, Yavaşcaoğlu B, Yilmazlar A, Özçelik S. Comparison of the catheter-technique psoas compartment block and the epidural block for analgesia in partial hip replacement surgery. *Acta Anaesthesiol Scand* 2003;47(1):30-6. [CrossRef](#)
- Ho AM, Karmakar MK. Combined paravertebral lumbar plexus and parasacral sciatic nerve block for reduction of hip fracture in a patient with severe aortic stenosis. *Can J Anaesth* 2002;49(9):946-50. [CrossRef](#)
- de Visme V, Picart F, Le Jouan R, Legrand A, Savry C, Morin V. Combined lumbar and sacral plexus block compared with plain bupivacaine spinal anesthesia for hip fractures in the elderly. *Reg Anesth Pain Med* 2000;25(2):158-62. [CrossRef](#)
- Jankowski CJ, Hebl JR, Stuart MJ, Rock MG, Pagnano MW, Beighley CM, et al. A comparison of psoas compartment block and spinal and general anesthesia for outpatient knee arthroscopy. *Anesth Analg* 2003;97(4):1003-9. [CrossRef](#)
- Klein SM, Greengrass RA, Grant SA, Higgins LD, Nielsen KC, Steele SM. Ambulatory surgery for multi-ligament knee reconstruction with continuous dual catheter peripheral nerve blockade. *Can J Anaesth* 2001;48(4):375-8. [CrossRef](#)
- Goroszeniuk T, di Vadi PP. Repeated psoas compartment blocks for the management of long-standing hip pain. *Reg Anesth Pain Med* 2001;26(4):376-8. [CrossRef](#)
- Saranteas T. Limitations in ultrasound imaging techniques in anesthesia: obesity and muscle atrophy? *Anesth Analg* 2009;109(3):993-4. [CrossRef](#)
- Kirchmair L, Entner T, Kapral S, Mitterschiffthaler G. Ultrasound guidance for the psoas compartment block: an imaging study. *Anesth Analg* 2002;94(3):706-10. [CrossRef](#)
- Morimoto M, Kim JT, Popovic J, Jain S, Bekker A. Ultrasound-guided lumbar plexus block for open reduction and internal fixation of hip fracture. *Pain Pract* 2006;6(2):124-6. [CrossRef](#)
- O'Donnell BD, Iohom G. Regional anesthesia techniques for ambulatory orthopedic surgery. *Curr Opin Anaesthesiol* 2008;21(6):723-8. [CrossRef](#)
- Mulroy MF, Larkin KL, Hodgson PS, Helman JD, Pollock JE, Liu SS. A comparison of spinal, epidural, and general anesthesia for outpatient knee arthroscopy. *Anesth Analg* 2000;91(4):860-4. [CrossRef](#)
- Jacobson E, Forssblad M, Rosenberg J, Westman L, Weidenhielm L. Can local anesthesia be recommended for routine use in elective knee arthroscopy? A comparison between local, spinal, and general anesthesia. *Arthroscopy*

- 2000;16(2):183-90. [CrossRef](#)
20. Ilfeld BM, Le LT, Meyer RS, Mariano ER, Vandeborne K, Duncan PW, et al. Ambulatory continuous femoral nerve blocks decrease time to discharge readiness after tricompartement total knee arthroplasty: a randomized, triple-masked, placebo-controlled study. *Anesthesiology* 2008;108(4):703-13.
 21. Gürkan Y, Kılıçkan L, Canatay H, Müezzinoğlu S, Tokar K. Artroskopik diz cerrahisinde farklı anestezi yöntemlerinin karşılaştırılması. *Türk Anesteziyoloji ve Reanimasyon Cemiyeti Mecmuası* 2002;30:408-12.
 22. Capdevila X, Barthelet Y, Biboulet P, Ryckwaert Y, Rubenovitch J, d'Athis F. Effects of perioperative analgesic technique on the surgical outcome and duration of rehabilitation after major knee surgery. *Anesthesiology* 1999;91(1):8-15. [CrossRef](#)
 23. Singelyn FJ, Deyaert M, Joris D, Penderville E, Gouverneur JM. Effects of intravenous patient-controlled analgesia with morphine, continuous epidural analgesia, and continuous three-in-one block on postoperative pain and knee rehabilitation after unilateral total knee arthroplasty. *Anesth Analg* 1998;87(1):88-92. [CrossRef](#)
 24. Parkinson SK, Mueller JB, Little WL, Bailey SL. Extent of blockade with various approaches to the lumbar plexus. *Anesth Analg* 1989;68(3):243-8. [CrossRef](#)
 25. Di Benedetto P, Pinto G, Arcioni R, De Blasi RA, Sorrentino L, Rossifragola I, et al. Anatomy and imaging of lumbar plexus. *Minerva Anesthesiol* 2005;71(9):549-54.
 26. Chayen D, Nathan H, Chayen M. The psoas compartment block. *Anesthesiology* 1976;45(1):95-9. [CrossRef](#)
 27. Winnie AP, Ramamurthy S, Durrani Z, Radonjic R. Plexus block for lower extremity surgery. *Anesth Rev* 1974;(1)1:11-6.
 28. Huet O, Eyrolle LJ, Mazoit JX, Ozier YM. Cardiac arrest after injection of ropivacaine for posterior lumbar plexus blockade. *Anesthesiology* 2003;99(6):1451-3. [CrossRef](#)
 29. Breslin DS, Martin G, Macleod DB, D'ercole F, Grant SA. Central nervous system toxicity following the administration of levobupivacaine for lumbar plexus block: A report of two cases. *Reg Anesth Pain Med* 2003;28(2):144-7. [CrossRef](#)
 30. Pousman RM, Mansoor Z, Sciard D. Total spinal anesthetic after continuous posterior lumbar plexus block. *Anesthesiology* 2003;98(5):1281-2. [CrossRef](#)
 31. Aida S, Takahashi H, Shimoji K. Renal subcapsular hematoma after lumbar plexus block. *Anesthesiology* 1996;84(2):452-5.
 32. Mullanu Ch, Gaillat F, Scemama F, Thibault S, Lavand'homme P, Auffray JP. Acute toxicity of local anesthetic ropivacaine and mepivacaine during a combined lumbar plexus and sciatic block for hip surgery. *Acta Anaesthesiol Belg* 2002;53(3):221-3.
 33. Aveline C, Bonnet F. Delayed retroperitoneal haematoma after failed lumbar plexus block. *Br J Anaesth* 2004;93(4):589-91. [CrossRef](#)