

PRIMARY PELVIC HYDATID CYST AS AN UNUSUAL CAUSE OF ADNEXAL MASS IN A POSTMENOPAUSAL WOMAN

Case Report

POSTMENOPOZAL DÖNEM ADNEKSİYAL KİTLENİN NADİR BİR NEDENİ; PRİMER PELVİK KİST HİDATİK

Raziye Narin

Numune Training and Research Hospital, Obstetrics and Gynecology, Adana.

Mehmet Ali Narin

Numune Training and Research Hospital, Obstetrics and Gynecology, Adana.

Deniz Aka Satar

Numune Training and Research Hospital, Histology and Embryology, Adana

Hakan Nazik

Numune Training and Research Hospital, Obstetrics and Gynecology, Adana

Fulya Adamhasan

Numune Training and Research Hospital, Pathology, Adana

Sefa Ozyazıcı

Numune Training and Research Hospital, General Surgery, Adana

Corresponding Author

Raziye Narin

*Department of Obstetrics and Gynecology,
Adana Numune Education and Research Hospital
Postal Code: 01330, Adana, TURKEY
fax: +903222472654
Tel: +905426882828
ryencilek@yahoo.com.tr*

ABSTRACT

Postmenopausal adnexal masses are important to make differentiation of benign-malign disorders. A 59 year-old postmenopausal woman presented with a mass in lower abdomen clinically suspicious of malignancy. Investigations failed to identify the nature. On laparotomy, excision of the mass was done. Histopathological examination identified the lesion as hydatid cyst arising from the mesentery of rectum. The patient had no history of liver or lung involvement. A significant clinical suspicion is necessary in the differential diagnosis of pelvic masses to identify such a rare entity.

Key Words: *Postmenopause; cyst hydatid; pelvic mass.*

ÖZET

Postmenopozal dönem adneksiyal kitlelerin malign-benign ayrımını yapmak önemlidir. 59 yaşında postmenopozal dönemdeki hasta batında kitle ile polikliniğimize başvurmuş, malignite şüphesi ile hastaneye yatırılmıştır. Araştırmaların kitlenin tanısını belirlemede yetersiz kalması üzerine hastaya laparotomi yapılmış ve kitle çıkarılmıştır. Histopatolojik inceleme sonucunda rektum mezenterinde yerleşmiş kist hidatik tanısı konulmuştur. Hastada daha önce geçirilmiş akciğer ve karaciğer kist hidatiği öyküsü bulunmamaktadır. Pelvik kitlelerin ayırıcı tanısında kist hidatik gibi nadir

nedenleri belirlemek için özellikle endemik bölgelerde yüksek klinik şüphe gerekir.

Anahtar kelimeler: *Postmenopoz; kist hidatik; pelvik kitle.*

INTRODUCTION

Postmenopausal adnexal masses are important to make differentiation of benign-malign disorders and district diagnosis require surgical removal and pathologic diagnosis.

The hydatid cyst is a common parasitic infection of liver. The most common form found in humans is cystic echinococcosis which is caused by echinococcus granulosus. In humans, the infestation is usually located in the liver (65%) or lungs (25%), and rarely involves the brain, heart, bone, or other organs(1). Involvement of others sites is usually secondary to these primary localizations. It is rare to diagnose an hydatid cyst in the pelvis, especially as a primary localization (2). The incidence being given as 0.2–2.25% (3).

We present a primary pelvic cyst hydatid arising from mesentery of rectum in a 59-year-old postmenopausal woman.as a rare entity.

CASE

A 59 year-old postmenopausal woman with gravida 11,parity 11 was admitted to our gynecology clinic with complaint of pelvic pain. Her family history and medical history were unremarkable except for hypertension. There was 64x57mm solid-cystic formation appearance at the left adnexia in the ultrasound imaging (USG) and abdominal computed tomography (CT) revealed that an 68x61mm mass lesion at the same location. The CT showed only the size and location of the mass, did not give additional information about the nature of the mass. All laboratory findings were normal (Ca125:11.0 U/ml, CA19-9: 23.5 U/ml CA15-3:24.6 U/ml AFP:2.8 IU/ml,

CEA:1.7 ng/ml, Hb:14g/dl). Cervicovaginal smear was benign.

The patient underwent laparotomy under general anesthesia. The Uterus, tubes and ovaries were compatible with menopausal status . At the left side of pelvis, behind the internal genital organs, a soft and smooth mass without any infiltration into the surrounding structures, palpated in the mezo of rectum. This mass was extirpated by a general surgeon (**Figure 1,A**).

The macroscopic appearance and the content of the mass was shown in figures (Figure 1,B,C). Postoperative recovery was uneventful. An albendazole therapy, 200 mg twice daily, was begun for six weeks. The patient underwent further clinical and the radiological evaluation for detection of hydatid disease of other organs. Since no evidence of such lesion was identified, a final diagnosis of primary rectal mesentery hydatid cyst was rendered. There was no complication in the postoperative period and she was discharged on the third postoperative day.

The solid-cystic lesion was subjected to histopathological examination. Histopathology confirmed the diagnosis of hydatid disease. (**Figure 1,D**).

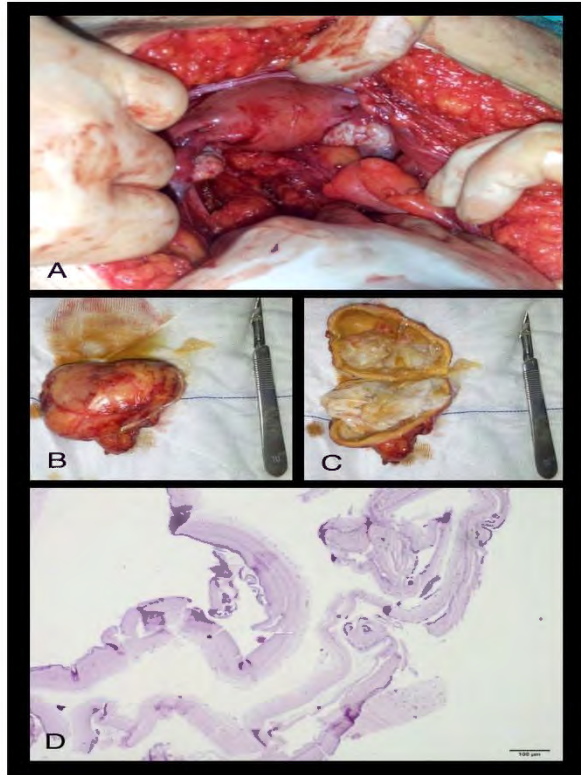


Figure 1. Shown the pelvis after the mass removed(A), The mass and its content (B,C) Microscopic appearance of germinal layer and laminated fibrous wall of hydatid cyst (H&Ex40). (D)

DISCUSSION

Echinococcosis is a zoonotic infection caused by *Echinococcus* spp. and is one of the most important helminthic diseases worldwide. Two forms of echinococcosis occur in Turkey, *Echinococcus granulosus* and *E. multilocularis*. The life cycle of *E. granulosus* is predominantly in dogs and sheep, and most sheep farmers in Turkey keep a dog or two.(4). In the literature, the primary hydatid cysts arising from the broad ligament and ovary were reported (5,6,7). Mesentery of rectum is also a rare location of primary cyst hydatid. The majority of hydatid cysts cause no symptoms. The manifestation of symptoms depends on the location, size, and the pressure caused by the enlarging cyst(8). Hydatid cysts grow slowly, like benign tumors (9,10). Radiological findings range from purely cystic lesion to a completely solid appearance(11). USG and CT Scan may show some features of

the mass such as multilocular appearance, cyst wall calcification, a fluid level from hydatid sand, and the ultrasonic water lily sign (12). However, in the present case, USG and CT Scan could not detect such abnormality. CT images revealed only an image of solid-cystic adnexial mass. Total excision was performed without destroying the cyst wall and we did not find any visceral organ involvement. Retrospectively, we investigate this is a primary infection because the patient had no history of hepatic and lung involvement.

Typically, medical treatment alone is not effective in hydatid disease(13,14). Complete surgical resection plus medical therapy is the preferred treatment for isolated echinococcosis.. Preoperative diagnosis of hydatid disease is essential because rupture and dissemination of the cyst may result in recurrence, and intraoperative spillage of the antigenic cyst fluid may lead to severe anaphylactic response. For this reason, rupture or spillage of cysts should be avoided (15,16). Laparoscopic cyst excision although technically difficult can be attempted with due risk of spillage if expertise for the same is available (17).

To diagnose this pathology one must have a high grade of suspicion and anamnestic data as it is important to differentiate between benign or malignant neoplasms. Hydatid disease must be considered while making the differential diagnosis of pelvic solid-cystic masses, especially in endemic areas.

REFERENCES

- 1) Amr SS, Amr ZS, Jitawi S, Annab H. Hydatosis in Jordan: an epidemiological study of 306 cases. *Ann Trop Med Parasitol* 1994; 88: 623-627.
- 2) Başaranoğlu M., Sonsuz A., Perek A., Perek S., Akin P. Primary pelvic hydatid cyst. *J Clin Gastroenterol.* 1998;26:157-158.
- 3) Tampakoudis P., Assimakopoulos E., Zafrakas M., Tzeveleki P., Kostopoulou E., Bontis J. Pelvic echinococcus mimicking multicystic ovary. *Ultrasound Obstet Gynecol.* 2003;22:196-198.

4) Altıntaş N. Past to present: echinococcosis in Turkey. *Acta Tropica*. Volume 85, Issue 2, February 2003,105-112.

5) Ovarian hydatid disease M. E. Alonso García, P. Suárez Mansilla, P. Mora Cepeda, E. Bayón Álvarez, C. Álvarez Colomo, J. I. González Martín *Arch Gynecol Obstet*. 2013 Dec 8. [Epub ahead of print]

6) Primary ovarian and pararectal hydatid cysts mimicking pelvic endometriosis. Bozkurt M, Bozkurt DK, Çil AS, Karaman M.*Acta Med Iran*. 2012;50:839-42.

7)Primary hydatid cyst of broad ligament.Bhattacharya A, Saha R, Mitra S, Nayak P.*Trop Parasitol*. 2013;3:155-7.

8) Duygulu F, Karaoğlu S, Erdoğan N, Yıldız O. Primary hydatid cyst of the thigh: a case report of an unusual localization *The Turkish Journal of Pediatrics* 2006; 48: 256-259.

9) Onerci M, Turan E, Ruacan S. Submandibular hydatid cyst. *J Craniomaxillofac Surg* 1991; 19: 359-361.

10) Sahni JK, Jain M, Bajaj Y, Kumar V, Jain A. Submandibular hydatid cyst caused by *Echinococcus oligarthus*. *J Laryngol Otol* 2000; 114: 473-476.

11) Polat P, Kantarci M, Alper F, Suma S, Koruyucu MB, Okur A. Hydatid disease from head to toe.*Radiographics* 2003; 23: 475-494.

12) Pedrosa I, Saíz A, Arrazola J, Ferreirós J, Pedrosa CS. Hydatid disease: Radiologic and pathologic features and complications. *Radiographics*. 2000;20:795-817.

13) Saimot AG. Medical treatment of liver hydatidosis. *World J Surg* 2001; 25: 15-20.

14) Anadol D, Ozcelik U, Kiper N, Gocmen A. Treatment of hydatid disease. *Pediatr Drugs* 2001; 3: 123-135.

15) Cannon CP, Nelson SD, Panosian CB, Seeger LL, Eilber FR, Eckardt JJ. Soft tissue echinococcosis: a report of two cases and review of the literature. *Clin Orthop* 2001; 385: 186-191.

16) Dudkiewicz I, Salai M, Apter S. Hydatid cyst presenting as a soft tissue thigh mass in a child. *Arch Orthop Trauma Surg* 1999; 119: 474-475.

17) Bickel A, Loberant N, Singer-Jordan J, Goldfeld M, Daud G, Eitan A. The laparoscopic approach to abdominal hydatid cysts: a prospective nonselective study using the isolated hypobaric technique. *Archives of Surgery*. 2001;136:789-795.