

NEPHROTIC SYNDROME ASSOCIATED WITH ISOTRETINOIN TREATMENT

Case Report

İSOTRETİNOİN TEDAVİSİ İLE İLİŞKİLİ NEFROTİK SENDROM VAKASI

Beyza Macunluoglu

*Department of Nephrology, Uskudar State Hospital,
34000, Istanbul, Turkey.*

Aydin Atakan

*Department of Nephrology, Fatih Sultan Mehmet
State Hospital, 34000, Istanbul, Turkey.*

Elif Ari

*Department of Nephrology, Van Yuksek Ihtisas
Hospital, 65200, Van, Turkey.*

Gulcin Kantarci

*Department of Nephrology, Yeditepe University
Medical Faculty, Istanbul, Turkey.*

Corresponding Author

Beyza Macunluoglu

*Department of Nephrology, Uskudar Ministry
Hospital, 34000, Istanbul, Turkey
Tel: +90 533 386 26 72
e-mail: beyzamacunlu@hotmail.com*

ABSTRACT

Isotretinoin is a synthetic retinoid used for the treatment of moderate to severe acne rosacea. Although various adverse effects during isotretinoin treatment have been reported, renal impairment is very rare. Herein we report a case of full-blown nephrotic syndrome associated with isotretinoin treatment.

A previously healthy 29 year old lady, presented with periorbital and ankle oedema. Based on the clinical and laboratory findings, she was diagnosed as nephrotic syndrome. A renal biopsy was taken and minimal change disease was diagnosed due to electromicroscopic examination which showed prominent effacement and microvillus formation in the pedicels of epithelial cells in the glomerulus. The only significant point in the history was the use of isotretinoin (40 mgr/day) which had been prescribed six months ago for acne rosacea. Isotretinoin was immediately stopped and she was treated with 1 mg/kg/day alfa-methyl prednisolone. The nephrotic syndrome responded to treatment in 3 weeks. Nephrotic syndrome is a rare side effect of isotretinoin therapy and should be suspected in any patient with oedema formation during therapy.

Key words: *nephrotic syndrome; isotretinoin; oedema.*

ÖZET

Isotretinoin, orta ve ağır şiddetli akne tedavisinde kullanılan sentetik bir retinoiddir. Isotretinoin tedavisi ile farklı yan etkiler bilinmekte olup, tedavi ile ilişkili böbrek yan etkileri oldukça nadirdir. Bu vaka sunumunda isotretinoin tedavisi altında gelişen nefrotik sendrom vakası takdim edilmiştir.

Daha önce bilinen bir hastalığı olmayan 29 yaşındaki bayan hasta periorbital ve alt extremitte ödemi ile nefroloji polikliniği'ne

başvurmuştur. Klinik ve laboratuvar bulguları sonucu nefrotik sendrom tanısı konulan hastanın hikayesinde tek göze çarpan nokta, 6 ay önce akne tedavisi için 40 mgr/gün dozunda isotretinoin tedavisi başlanmış olmasıydı. Isotretinoin tedavisi hemen kesilerek alf-methyl-prednisolone 1 mgr/kg/gün başlatılan hastanın 3 hafta içinde nefrotik sendrom klinik ve laboratuvar bulguları tamamen düzelmiştir. Sonuç olarak, isotretinoin tedavisinde çok nadir olarak nefrotik sendrom görülebilir ve bu tedavi sırasında ödem yakınması olan bütün hastalarda şüphe uyandırılmalıdır.

Anahtar kelimeler: nefrotik sendrom; isotretinoin; ödem.

INTRODUCTION

Isotretinoin, a vitamin A related molecule, has been widely used in the treatment of severe and antibiotic-resistant cystic acne vulgaris for more than 25 years. It is also rarely used in the treatment of certain malignancies such as certain skin cancers, brain and pancreatic tumours. Isotretinoin, normally found in small quantities in humans, is known to be a safe drug and most of the side effects are related to dry mouth, dry eyes, cheilitis, headache, nausea, elevated liver enzymes, a shift towards an atherogenic lipid profile and teratogenic birth defects (1,2). Despite this wide spectrum of side effects, little is known about its impact on the kidneys. Here we report a case of full-blown nephrotic syndrome following the use of isotretinoin.

CASE PRESENTATION

A previously healthy 29 year old lady was referred to our nephrology department due to periorbital and ankle oedema. She also complained of turbidity in urine and 10 kg weight gain in the last two months. No previous renal disease or familial renal disease history was found. There was no history of hypertension, diabetes or any clue for rheumatic and vasculitic diseases. The only significant

point in the history was the use of isotretinoin (40 mgr/day) which had been prescribed six months ago for acne rosacea. On the day of the admission, she was still on isotretinoin therapy. Physical examination revealed significant periorbital and pretibial oedema. Blood pressure was 110/80 mmHg with a pulse rate of 72 beats/min. Blood work showed normal blood urea nitrogen (11mg/dl), creatinine (0.57 mg/dl) and electrolyte levels with significant hypoalbuminemia (1.8 gr/dl). Total cholesterol (445mg/dl) and LDL cholesterol levels (347mg/dl) were significantly increased. Hematologic parameters were all within normal limits (Haemoglobin 14.3 gr/dl, Leukocytes 10,000/mm³ with normal differential count) except for ESR (64 mm/hr, normal <15 mm/hr). Serological tests including viral markers, ANA, Anti-dsDNA, RF, ANCA titers as well as the Direct Coombs test were all negative. Complement factor levels were also normal (C3:1.07 gr/l, C4: 0.227 gr/l). 24-hour urine collection revealed 4100 mg/day microalbuminuria. Urine microscopy was negative for cellular elements and casts. Ultrasonographic examination showed two normal-sized kidneys with normal echogenicity without any evidence of obstruction. Based on these findings, she was diagnosed with nephrotic syndrome and a percutaneous renal biopsy was undertaken to identify the underlying glomerular pathology. Histologic examination revealed 13 glomeruli without evidence of sclerosis. Thirty percent of glomeruli showed mild mesangial expansion without any cellular infiltration, necrosis or crescent formation. The remainders of the glomeruli as well as the tubulointerstitial and vascular areas were all normal under light microscopic examination. Immune-fluorescence revealed IgM and C3 deposition in only one glomerulus. Congo-red staining was negative for amyloidosis. Electron microscopic examination showed prominent effacement and microvillus formation in the pedicels of epithelial cells in the glomerulus (**Figure 1**).

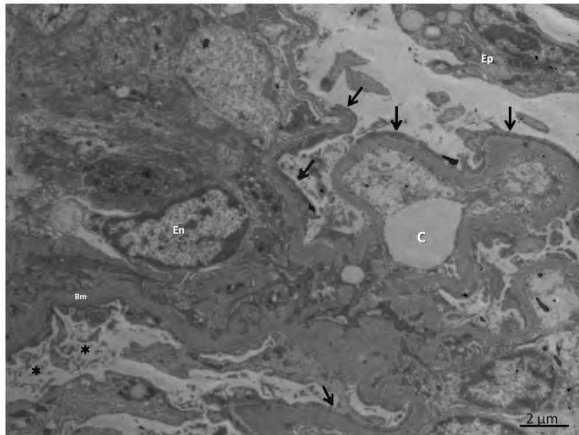


Figure 1: Electron microscopic examination; Prominent effacement (arrows) and microvillus transformation (asterix) in the pedicels of epithelial cells (Ep) in the glomerulus. (Bm): Basement membrane; (En): Nucleus of an endothelial cell; (C): Capillary lumen. Bar=2 µm .

On the basis of data mentioned, diagnosis of minimal change disease due to isotretinoin use was made. Isotretinoin was immediately stopped and she was treated with 1 mg/kg/day alfa-methyl prednisolone and 80 mg/day furosemide. The nephrotic syndrome responded to treatment in 3 weeks. During that time, serum albumin level increased to 4 gr/dl, microalbuminuria decreased to 30mg/day while the patient lost 8 kg with complete resolution of oedema. Corticosteroids were tapered off every 2 weeks without any sign of relapse. On her last follow -up two months after the start of therapy, the patient was on 4 mg of alfa-methyl prednisolone without any evidence of relapse.

DISCUSSION

Drugs are well known causes of minimal change disease. ACE inhibitors, 5 aminosalicylic acid, sulphasalazine, NSAII and gold are the most known agents . To date, only a single case of nephrotic syndrome development after isotretinoin use has been reported before. In that report, the nephrotic syndrome was clinically manifest 2 months after the start

of therapy and clinical symptoms had resolved after discontinuation of the drug and a short course of corticosteroids (3). Our patient 's clinical, histologic and outcome features are similar. The only difference is that our patient developed nephrotic syndrome after 4 months of therapy. An interesting case report by Horber et al described renal impairment, hypercalcemia and proteinuria in a patient treated with etretinate (a synthetic retinoid) for superficial bladder tumour (4). Pavesse et al also reported mild proteinuria and renal impairment in a patient treated with isotretinoin for acne after 2 months of therapy. After discontinuation of therapy renal functions and proteinuria returned to normal [5]. However in both case reports, proteinuria was in the non-nephrotic range. Although it may be argued that the development of nephrotic syndrome was coincidental in our patient, rapid resolution of symptoms and proteinuria after withdrawal of isotretinoin and the quick response to a short course of corticosteroid therapy imply a causal relationship.

CONCLUSION

Nephrotic syndrome is a rare side effect of isotretinoin therapy and should be suspected in any patient with oedema formation during therapy. The drug should be stopped immediately with a short course of corticosteroid therapy started in patents with the full nephrotic syndrome.

ACKNOWLEDGEMENTS

Written informed consent was obtained from the patient for publication of this case report and accompanying images.

REFERENCES

- 1)Strauss JS, Krowchuck DP, Leyda JJ et al. Guidelines of care of acne vulgaris management. *J Am Acad Dermatol* 2007; 56 : 651-663.
- 2)Berard A, Azaoulay L, Koren G, Blais L, Perrault S, Oraichi D. Isoretinoin, pregnancies, abortions and birth defects; a population based perspective .*Br J Clin Pharmacol* 2007; 63 :190-205.

3) Oers van AJ, Leeuw DJ, Bommel van HE. Nephrotic syndrome associated with isotretinoin. *Nephrol Dial Transplant* 2000;15: 924.

4) Horber FF, Zimmerman A, Frey FJ. Impaired renal function and hypercalcaemia associated with etretinate. *Lancet* 1984; 10: 1093.

5) Pavese P, Kuentz F, Belleville C, Rouge P, Elsener M. Renal impairment induced by isotretinoin. *Nephrol Dial Transplant* 1997;12:129.