

THE COINCIDENCE OF APPENDICITIS AND BLUNT ABDOMINAL TRAUMA- THE CHICKEN OR THE EGG DILEMMA

Case Report

APANDİSİT VE KÜNT KARIN TRAVMASI BİRLİKTELİĞİ-TAVUK VEYA YUMURTA İKİLEMİ

Safak Karacay

Yeditepe University Faculty of Medicine, Department of Pediatric Surgery and Pediatric Urology, Istanbul

Selami Sozubir

Yeditepe University Faculty of Medicine, Department of Pediatric Surgery and Pediatric Urology, Istanbul

Bengi Gurses

Yeditepe University Faculty of Medicine, Department of Radiology, Istanbul

Sevgi Bilgen

Yeditepe University Faculty of Medicine, Department of Anesthesia, Istanbul

Corresponding Author

Safak Karacay

*Yeditepe University Faculty of Medicine, Department of Pediatric Surgery and Pediatric Urology Istanbul/Turkey
Email: safakkaracay@gmail.com*

ABSTRACT

While the appendicitis and blunt abdominal trauma are two distinct entities, there are still rare instances where they may unite and can come as a surprise to the clinician. The authors report one such child who had abdominal pain due to trauma at presentation but went on to develop appendicitis. This reports discusses the coincidence and pitfalls of the situation for both the clinician and the surgeon.

Key Words: *Childhood; Appendicitis; Blunt Abdominal Trauma.*

ÖZET

Apandisit ve künt karın travması iki farklı durum olsa da, nadiren gösterebildikleri birliktelik klinisyen için bir sürpriz olabilir. Bu sunumda, travma nedeniyle başvuran ancak klinik izleminde karın ağrısı devam eden ve sonuçta apandisit gelişen bir olguyu bildirdik. Çalışmada, hem klinisyen hem de cerrah için tesadüfi birliktelik ve kolaylıkla tanısı atlanabilecek apandisit ile ilgili detaylar incelenmiştir.

Anahtar Kelimeler: *Çocukluk Çağı; Apandisit; Künt batın travması.*

INTRODUCTION

Appendicitis occurring after blunt abdominal trauma is a rare condition which debates still exist whether this is an incidental finding or result of a cause-effect relationship. Some patients are presented as direct trauma to the appendix causing a linear perforation while some are thought to be caused by indirect effects of pressure to the organ or mesoappendix. While the underlying mechanism is still unclear, the possibility of a coincidence between these two distinct pathologies endangers a delayed diagnosis and perforation of the appendix(1,2).We aimed to discuss the coincidence and pitfalls of the situation for both the clinician and the surgeon.

Although it is easier with the aid of modern imaging techniques, we emphasized that, appendicitis does not have to be ruled out in the presence of a history of blunt abdominal trauma with the findings of right lower quadrant pain and tenderness.

CASE REPORT

A 6-year-old boy presented to the emergency department (ED) with a 24-hour history of mild abdominal pain, discomfort and nausea starting about 8 hours after a punch in his abdomen by his class mate. The parents told about witnesses reporting the scene as sudden, without a fight and ended after one blow. He had vomitted once without bile, and his appetite diminished surprising the parents. He was having medication for Attention Deficit Hyperactivity Disorder (ADHD) for four months, and his appetite increased since then. He had no other complaints and no other signs of trauma. Apart from ADHD, his past medical history was unremarkable. The patient's vital signs were: blood pressure 110/80 mm/Hg, heart rate 126 beats/min, respiratory rate 32 breaths/min, and temperature 37.3°C. In general, the patient appeared moderately uncomfortable and pale. The abdominal examination was significant for moderate distension and tenderness to palpation and guarding throughout the abdomen, greatest at the right lower quadrant. Rectal and genitourinary examinations were unremarkable. Chest, pelvis, abdominal X-ray studies were normal. The CBC and urinalysis were also unremarkable.

An abdominal ultrasonography [USG] was done in the ED and was questionable for fluid in the pouch of Douglas. The examination findings and USG led us to the abdominal computed tomography [CT] scan which displayed moderate free fluid in the pelvis with no solid organ injury. The appendix was inflamed and there were fecaliths in the lumen (**Figure 1**).

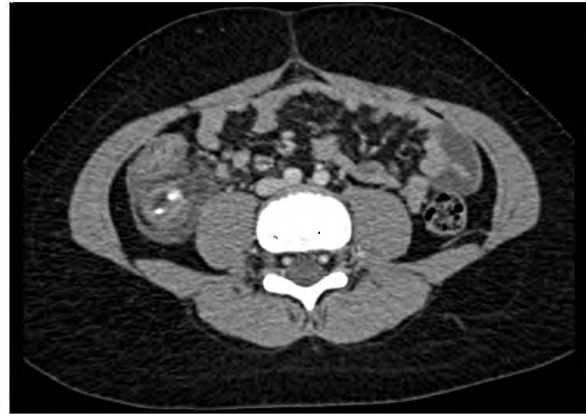


Figure 1: Axial contrast enhanced CT image showing Enlargement of the appendix (18 mm) Increased enhancement of appendicial wall on postcontrast images Two millimetric appendicoliths in the lumen of the appendix.

Although the patient's vital signs remained normal, the CT scan findings as well as the patient's uncomfortable appearance and significant tenderness on abdominal examination led us to plan surgery instead of observing the patient and performing serial examinations.

Under general anesthesia, we performed an exploratory laparotomy and observed sero purulent fluid while entering the abdomen. During the exploration, no injuries were found along the small bowel, and there was no evidence of solid organ injury. The appendix was subserous and retrocecal, erythematous with a perforation distal to the palpable fecaliths (**Figure 2**).

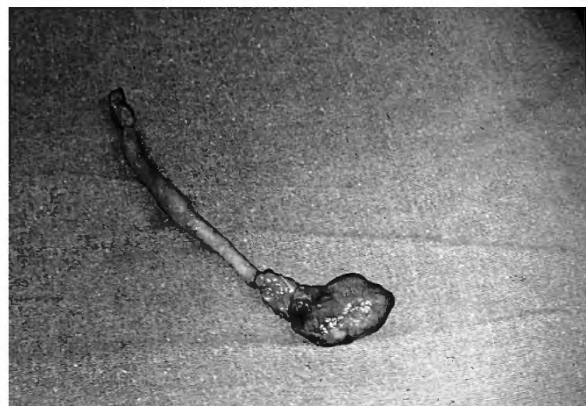


Figure 2: Macroscopic appearance of the appendix .

The patient's abdomen was irrigated with normal saline, and the fascia and skin were closed.

The histopathological examination revealed a focus of adherent fibro purulent material 1 cm from the inflamed appendiceal tip. A diagnosis of acute appendicitis and rupture of the organ was made.

Ampicillin, gentamicin, and metronidazole were started postoperatively. The patient's hospital course was uncomplicated with a maximum temperature of 38.1°C and white blood cell count of 12,600. After 2 days of observation, the patient was discharged home in a good condition on oral penicillin.

DISCUSSION

It has been more than a century now, which the mechanism of appendicitis has been thoroughly investigated and reported. Animal studies as well as human researches after the cannulation of exteriorized appendix and pressure monitoring(1) have been in great help about understanding the pathology. The vicious cycle of obstruction, continuing secretion of the mucosa, and increased pressure lead to ischemia and perforation of the organ(1,2,3) . Any cause leading to the luminal obstruction of the organ may result with this scene. Fecaliths, enlarged lymph nodes, foreign bodies and even intestinal parasites (4,5) have been found to be responsible.

There are rare cases in literature reporting the coincidence of blunt abdominal injuries and appendicitis in children, which rise up the suspicion of a cause-effect relationship (2-5).

The abdominal muscles, mobility of intraabdominal hollow viscera and sustained low friction with the aid of fluids are the defense mechanisms serving to protect the intestines from trauma. This happens as a simple sliding over motion.

The pressure which is radiated throughout the abdomen causes the parenchymal fixed organs to be injured more than the relatively mobile hollow viscera which may have the possibility to "run away" from the acute intrusion. Fixed structures are subject to greater stress than loosely attached ones (4) . In case of an external force targeting an intestinal segment which is fixed by peritoneum as duodenum, or subserosal retrocecal appendix, a squeezing action caused by external pressure is most likely to trigger a consequence of events such as edema formation and inflammation if acute rupture does not happen. In case of appendix, fixation within the subserosa and retrocecal position, intraluminal masses most commonly fecaliths(2,4,5), previous colonization of bacteria due to diminished transit time(3), force at an unprepared time, may be triggering the histopathological cycle of events.

CONCLUSION

The cause-effect hypothesis in this presentation are suggested after clinical experiences, analysis of available physiological data and literature review. However, it should be kept in mind that they are still theories. The aim of this article is not to demonstrate a direct relationship between trauma and appendicitis or prove the causative factors, but to maintain a high level index of suspicion that there are cases with obscured appendicitis behind the curtaining history of blunt abdominal trauma. Pediatric intrabdominal blunt traumas are well known entities by pediatric surgeons throughout the world, and the main principle is clinical follow up before any surgical intervention is carried out. In case of an occult acute appendicitis, the time only serves as an ally of complications. Keeping the possibility in mind, timely diagnostic evaluation and suitable imaging will prevent the delay in diagnosis, which will reduce the complications.

REFERENCES

1)Wangensteen OH, Dennis C. *Experimental proof of the obstructive origin of appendicitis in man. Ann Surg.* 1939;110:629-47.

2)Hennington MH, Tinsley EA Jr, Proctor HJ, Baker CC. *Acute appendicitis following blunt abdominal trauma. Incidence or coincidence? Ann Surg.* 1991;214:61-3.

3)Ramsook C. *Traumatic appendicitis: fact or fiction? Pediatr Emerg Care.* 2001;17:264-6.

4)Fowler RH. *The rare incidence of acute appendicitis resulting from external trauma. Ann Surg.* 1938;107:529-39.

5)Amir A, Amir L, Waisman Y. *Acute appendicitis after a blunt perineal trauma: an illustrative case. Pediatr Emerg Care.* 2009;25:184-5.