



# Evaluation of difficult alopecia areata cases requiring histopathological confirmation

## Histopatolojik inceleme gerektiren alopesi areatalı olguların değerlendirilmesi

İD Güldehan Atış, İD Aşşenur Şam Sarı\*

Üsküdar University, Ataşehir Memorial Hospital, Clinic of Dermatology, İstanbul, Türkiye

\*Üsküdar University, Acıbadem Health Group, Clinic of Dermatology, İstanbul, Türkiye

### Abstract

**Background and Design:** Alopecia areata (AA) is a common cause of non-cicatricial hair loss on the scalp or hearing-bearing areas, and diagnosis is typically straightforward. In atypical cases, histopathological examination is suggested. This study aims to determine when dermatologists need histopathological confirmation in AA and which clinical and trichoscopic clues aid diagnosis in atypical cases.

**Materials and Methods:** Patients diagnosed with AA clinically and histopathologically were retrospectively included in the study. Age, gender, duration of disease, localizations of lesions, number of lesions, trichoscopy features, initial diagnosis, extra-scalp involvement, and nail characteristics were recorded.

**Results:** 10 (7.3%) of 137 patients had histopathologic examinations. The mean age of patients was 37.9 ( $\pm 14.68$ ). Five of the ten patients (50%) were male, and five were female. The mean disease duration was 48.7 ( $\pm 74.55$ ) months. All the patients suffered from their first episode. Patchy AA (n=9, 39.5%) and cicatricial alopecia (n=7, 30.4%) were the two most frequent initial diagnoses. Loss of follicle ostia (n=7), vellus hairs (n=7), anisotrichosis (n=5), yellow dots (n=5), and erythematous background (n=4) were the five most prevalent features. Only one of the patients (10%) has extra-scalp involvement. Two patients have nail features.

**Conclusion:** We assume that some unexpected trichoscopy features, such as loss of follicle ostium and vellus hair, can be observed in cases with long disease duration, whereas typical trichoscopy features, such as exclamation mark hairs, yellow dots, and black dots, are not always detected in these patients. In some challenging cases, the diagnosis may require histopathological confirmation.

**Keywords:** Alopecia areata, histopathology, dermoscopy

### Öz

**Amaç:** Alopesi areata (AA), saçlı deri ve kıllı bölgeleri tutan, kolaylıkla tanı konulabilen sık görülen bir non-sikatrisyel saç dökülmesi sebebidir. Atipik olgularda histopatolojik inceleme önerilmektedir. Bu çalışmada amacımız, dermatologların AA'lı hastalarda ne zaman histopatolojik incelemeye ihtiyaç duyduklarını ortaya koymak ve atipik olgularda tanıya yardımcı olabilecek klinik ve trikoskopik ip uçlarını belirlemektir.

**Gereç ve Yöntem:** Klinik ve histopatolojik olarak AA tanısı alan hastalar retrospektif olarak çalışmaya alındı. Yaş, cinsiyet, lezyon lokalizasyonları, lezyon sayıları, trikoskopik bulgular, ön tanılar, saçlı deri dışı tutulum varlığı ve tırnak bulguları kaydedildi.

**Bulgular:** Yüz otuz yedi hastanın 10'una (%7,3) histopatolojik inceleme yapılmıştı. Hastaların yaş ortalaması 37,9 ( $\pm 14,68$ ) idi. Hastaların beşi (%50) kadın, beşi erkek idi. Ortalama hastalık süresi ( $\pm 74,55$ ) ay idi. Tüm hastaların ilk atağıydı. En sık iki ön tanı yama AA (n=9, %39,5) ve sikatrisyel alopesi (n=7, %30,4) idi. Folikül ostiumlarında kayıp (n=7), vellus saçlar (n=7), anizotrikozis (n=5), sarı noktalar (n=5) ve eritematöz zemin (n=4) en sık görülen beş bulguydu. Sadece 1 hastada (%10) saçlı deri dışı tutulum saptandı. İki hastada (%20) tırnak bulguları izlendi.

**Sonuç:** Hastalık süresinin uzun olduğu olgularda; folikül ostiumlarında kayıp ve vellus saçlara gibi bazı beklenmedik trikoskopik bulguların gözlemlenebileceğini ancak ünlem saçlar, sarı noktalar ve siyah noktalar gibi tipik trikoskopik bulguların görülmeyebileceğini düşünmekteyiz. Bazı çelişkili olgularda histopatolojik konfirmasyon gerekebilir.

**Anahtar Kelimeler:** Alopesi areata, histopatoloji, dermoskopi

**Address for Correspondence/Yazışma Adresi:** Güldehan Atış MD, Üsküdar University, Ataşehir Memorial Hospital, Clinic of Dermatology, İstanbul, Türkiye

**E-mail:** guldehan.atis@gmail.com **ORCID:** orcid.org/0000-0001-5069-044X

**Received/Geliş Tarihi:** 15.08.2024 **Accepted/Kabul Tarihi:** 07.02.2025 **Publication Date/Yayınlanma Tarihi:** 28.03.2025

**Cite this article as/Atf:** Atış G, Şam Sarı A. Evaluation of difficult alopecia areata cases requiring histopathological confirmation. Turkderm-Turk Arch Dermatol Venereol. 2025;59(1):13-7



## Introduction

Alopecia areata (AA) is a common cause of non-cicatricial hair loss on the scalp or hair-bearing areas<sup>1</sup>. Due to the presence of well-demarcated, non-inflammatory, alopecic patches and well-defined trichoscopic characteristics, such as exclamation mark hairs, yellow dots, black dots, and tapered hairs, diagnosing these patients is typically straightforward<sup>2</sup>. Diffuse hair loss or the absence of characteristic clinical and trichoscopy features make diagnosis challenging. In such cases, a histopathological examination is suggested<sup>3,4</sup>. This study is designed to determine when dermatologists need histopathological confirmation in AA and which clinical and trichoscopic clues aid diagnosis in difficult cases.

## Materials and Methods

Patients who cannot be diagnosed based on the typical clinical and trichoscopy features<sup>2</sup> and required histopathological confirmation for diagnosis of AA were included in the study retrospectively. The data were collected from the "hair diseases clinic" archives between February 2016 and July 2021. Age, gender, disease duration, lesion localization, number of lesions, trichoscopic features, initial diagnosis, extra-scalp involvement and nail characteristics were recorded from the files routinely created for all patients applying to the hair clinic. A patient with more than two lesions was considered as having multiple lesions.

The presence of lymphocytic infiltration on the peribulbar area instead of the infundibulum, increasing the number of vellus and miniaturized hairs, the presence of terminal catagen hairs and increasing telogen hairs and the absence of prominent fibrosis were used as histopathological criteria for diagnosis of AA<sup>5</sup>.

### The study was approved by the Ethics

Committee of the University of Health Sciences Türkiye, Haydarpaşa Numune Training and Research Hospital (approval number: HNEAH-KAEK 2022/KK/5, date: 10.01.2022).

### Statistical Analysis

The descriptive statistics of the data used mean, standard deviation, minimum, and maximum values. SPSS 28.0 was utilized for analysis. The p-value of 0.05 was statistically significant.

## Results

The data of 137 patients with AA were retrieved from our department's archive. Ten patients (7.3%) had histopathologic examination. The mean age of patients was 37.9 ( $\pm 14.68$ ) years. Five of the ten patients (50%) were male, and five were female. The mean disease duration was 48.7 ( $\pm 74.55$ ) months. Two patients (20%) had a history of atopy, and two patients (20%) were diagnosed with thyroid disease. One patient (10%) has a positive family history. All the patients suffered from their first episode of hair loss. Biopsies were performed on the patients with 23 initial diagnoses. Patchy AA (n=9; 39.5%) and cicatricial alopecia (n=7; 30.4%) were the two most frequent initial diagnoses. Table 1 presents a summary of all initial diagnoses.

Various microscopic features were observed. Loss of follicle ostia (n=7) (Figures 1a, 2a) vellus hairs (n=7) (Figure 1a), anisotrichosis (n=5)

(Figures 1a, 3a), yellow dots (n=5) (Figure 1a), and erythematous background (n=4) (Figure 2a) were the five most prevalent features. Only one of the patients (10%) has extra-scalp involvement. Five of the patients (50%) have a single lesion (Figure 3b), four of the patients (40%) have multiple lesions (Figure 2b), and one of the patients (10%) has diffuse alopecia. Vertex is the most frequent localization (n=5; 50%). Two patients have nail features. All clinical characteristics are outlined in Table 2.

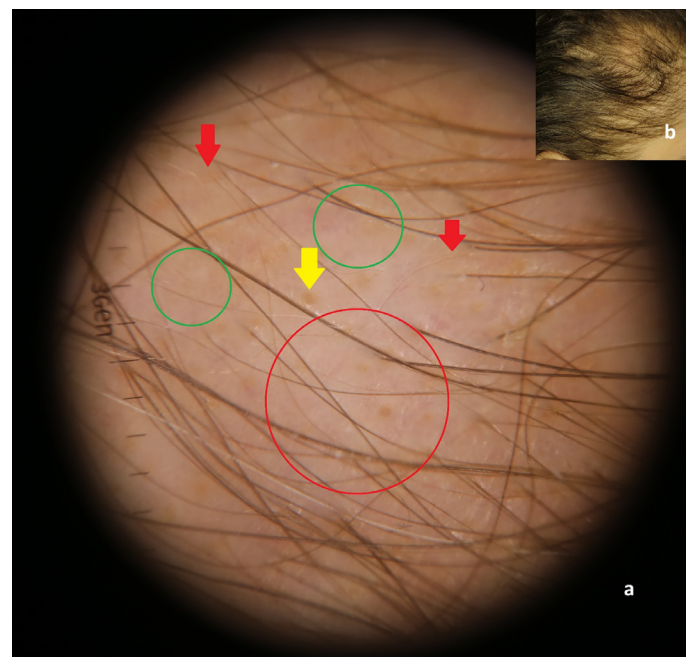
## Discussion

AA is one of the most common causes of hair loss, and its trichoscopic features are well described in the literature. Yellow dots, regrowing hairs, exclamation mark hairs, black dots, broken hairs, tapered hairs, short vellus hair, pigtail hair, and Pohl-Pinkus constrictions are known trichoscopy features of AA<sup>6,7</sup>. Exclamation mark hairs, yellow dots,

**Table 1. Distribution of initial diagnosis of patients**

Initial diagnosis	n (%)	
Patchy AA	9 (39.5)	
Cicatricial alopecia	LPP	3 (12.9)
	PPB	2 (8.6)
	Alopecia mucinosa	2 (8.6)
Trichotillomania	2 (8.6)	
CTE	2 (8.6)	
FPA	1 (4.3)	
TA	1 (4.3)	
Diffuse AA	1 (4.3)	

AA: Alopecia areata, LPP: Lichen planopilaris, PPB: Pseudo-pelade of Broque, CTE: Chronic telogen effluvium, FPA: Female pattern alopecia, TA: Tractional alopecia



**Figure 1. (a)** Yellow dots (yellow arrow), anisotrichosis (red circle), loss of follicle ostia (green circle), vellus hairs (red arrow) on trichoscopy; **(b)** Diffuse thinning of hair on the temporal region

and black dots are common and helpful findings for diagnosing AA. The absence of these findings was surprising and challenging for the AA diagnosis. In our study, contrary to expectations, 70% of the patients exhibited loss of follicle ostia and vellus hairs as the most prevalent trichoscopy feature. Scarring alopecia is characterized by the loss of follicle ostia, corresponding to perifollicular fibrosis<sup>8</sup>. Perifollicular fibrosis with follicular dropout can be observed in patients with a long history of repeated attacks in AA. Most of our patients with loss of follicle ostia have a long disease duration. The presence of vellus hairs is a non-specific feature of AA and can be observed in many other conditions besides AA. It is usually associated with prolonged disease course<sup>7</sup>. We detected vellus hair in most patients with long disease duration.

The majority of patients experience more than one episode<sup>9</sup>. It is prevalent among adolescents, with approximately 40.2% of patients experiencing their first episode before the age of 20<sup>10</sup>. In our study, contrary to the literature, only 10% of patients were children, and the mean age of patients was 37.9 years older than expected. None of the patients had more than one episode. In addition to unusual clinical and trichoscopic features, it appears that unexpected demographic characteristics make diagnosis challenging.

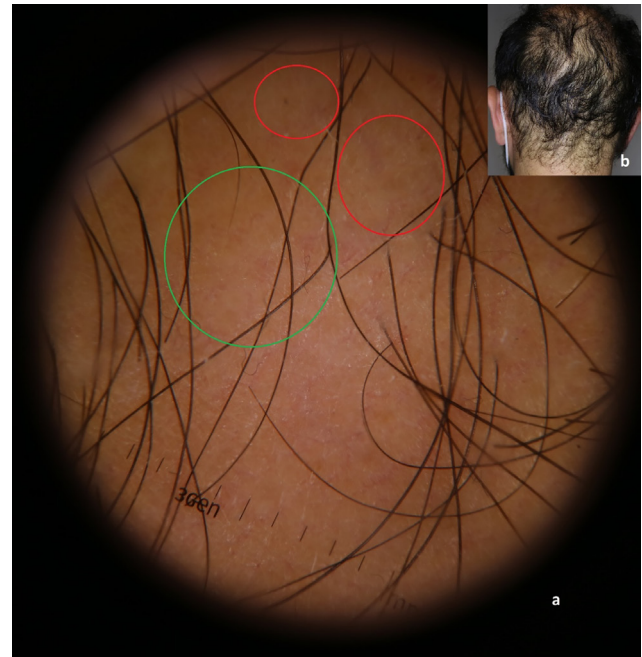In the general population, the lifetime risk of AA is approximately 2%, but genetic studies have shown that AA patients' risks for parents, siblings, and offspring are 7.8%, 7.1%, and 5.5%, respectively. Literature indicates that 4-28% of AA patients have at least one other affected family member<sup>3</sup>. Only one patient (10%) in our study has a family history. A positive family history can help diagnose a patient with an uncommon presentation.

Atopy is a risk factor for the occurrence of AA. The involvement of common mediators in the pathogenesis of allergic asthma and atopic dermatitis has been demonstrated in previous studies. 20% of the patients in our study have atopy. In many studies, it has been shown that thyroid diseases are more common in patients with AA<sup>9</sup>. In our study, thyroid disease was detected in two patients (20%). The presence of conditions accompanying AA can aid in the diagnostic process.

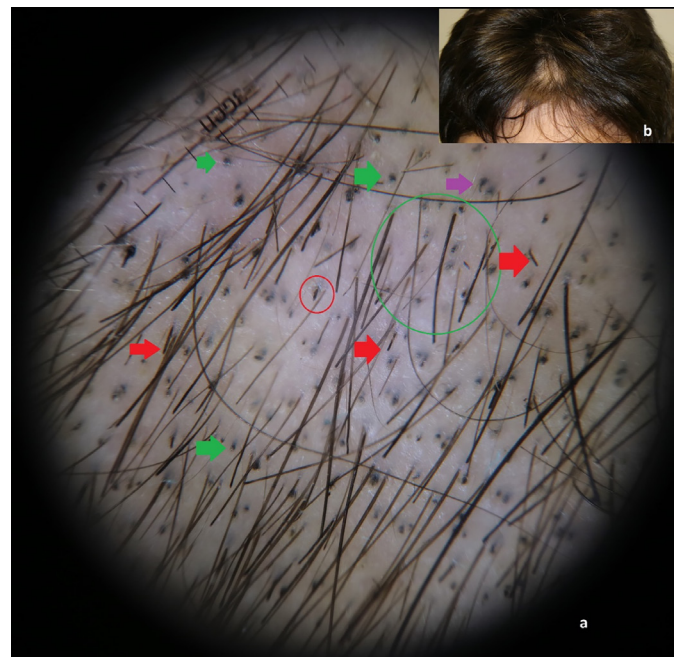
Tinea capitis, temporal triangular alopecia, and trichotillomania are some conditions that should be considered in the differential diagnosis of AA<sup>1</sup>. Since these diagnoses were ruled out clinically and trichoscopically, they were not included in our study's initial diagnosis. However, distinguishing diffuse AA from telogen effluvium can be difficult<sup>1</sup>. One of our patients (patient 9) underwent a biopsy with two initial diagnoses of chronic telogen effluvium and diffuse AA, and the patient was diagnosed with diffuse AA.

AA patients report 7 to 66% of cases of nail changes, which is a high incidence. Pitting and trachyonychia are the most prevalent features. Children and patients with severe diseases like alopecia totalis or universalis are likelier to experience nail involvement<sup>11</sup>. In our study, one of our patients has longitudinal ridges, and another has subungual hyperkeratosis. Subungual hyperkeratosis is not associated with AA, even though longitudinal ridges are reported in this condition. Consequently, only 10% of patients with AA have nail involvement<sup>11</sup>. It may be related to our study's absence of pediatric patients or the prevalence of patients with mild diseases. Despite this, our study group's incidence of nail involvement was low. While our study

provides valuable insight into the diagnostic challenges of AA, it is not without limitations. The limitations of our study are that the study was conducted with a small group in a single country and that information about various skin types and colors was not obtained. Multicenter studies are needed to confirm our findings.



**Figure 2. (a)** Loss of follicle ostia (green circle), erythematous background (red circle) on trichoscopy; **(b)** Diffuse thinning of hair on the scalp and multiple alopecic patches



**Figure 3. (a)** Anisotrichosis (green circle), broken hairs (red arrows), black dots (green arrow), comma hair (purple arrow), flame hair (red circle) on trichoscopy; **(b)** Alopecic area on frontal region

Table 2. Demographic and clinical features of patients

Patient	Age	Gender	Duration of symptoms (month)	Localization	Number of lesions	Trichoscopy features	Initial diagnosis	% of scalp involvement	Extra-scalp involvement	Nail features
1	34	F	240	Vertex	1	<ul style="list-style-type: none"> <li>• Loss of follicle ostium</li> <li>• Vellus hair</li> <li>• Yellow dots</li> <li>• Anisotrichosis</li> <li>• Dirty dots</li> </ul>	<ul style="list-style-type: none"> <li>• Patchy AA</li> <li>• LPP</li> <li>• BPP</li> </ul>	15	None	None
2	40	F	12	Temporal	2	<ul style="list-style-type: none"> <li>• Loss of follicle ostium</li> <li>• Vellus hair</li> <li>• Yellow dots</li> <li>• Anisotrichosis</li> </ul>	<ul style="list-style-type: none"> <li>• TA</li> <li>• Patchy AA</li> <li>• CTE</li> </ul>	25	None	Subungual hyperkeratosis
3	32	M	108	Diffuse	Multiple	<ul style="list-style-type: none"> <li>• Loss of follicle ostium</li> <li>• Yellow dots</li> <li>• Erythematous background</li> </ul>	<ul style="list-style-type: none"> <li>• BPP</li> <li>• Patchy AA</li> </ul>	25	None	None
4	25	M	20	Frontal	1	<ul style="list-style-type: none"> <li>• Vellus hair</li> <li>• Anisotrichosis</li> <li>• Erythematous background</li> <li>• Broken hairs</li> <li>• Black dots</li> <li>• Comma hair</li> </ul>	<ul style="list-style-type: none"> <li>• TTM</li> <li>• Patchy AA</li> </ul>	10	None	None
5	13	M	1	Frontal	1	<ul style="list-style-type: none"> <li>• Anisotrichosis</li> <li>• Broken hair</li> <li>• Black dots</li> <li>• Comma hair</li> <li>• Flame hair</li> </ul>	<ul style="list-style-type: none"> <li>• Patch AA</li> <li>• TTM</li> </ul>	5	None	None
6	35	M	2	Vertex and occipital	2	<ul style="list-style-type: none"> <li>• Loss of follicle ostium</li> <li>• Vellus hair</li> <li>• Erythematous background</li> <li>• Scale</li> <li>• Tapered hair</li> </ul>	<ul style="list-style-type: none"> <li>• LPP</li> <li>• Patchy AA</li> </ul>	7.5	None	None
7	32	F	48	Vertex	1	<ul style="list-style-type: none"> <li>• Vellus hair</li> <li>• Yellow dot</li> <li>• Tapered hair</li> </ul>	<ul style="list-style-type: none"> <li>• FPA</li> <li>• Diffuse AA</li> </ul>	20	None	None
8	49	F	18	Temporal, frontal, eyebrow	Multiple	<ul style="list-style-type: none"> <li>• Loss of follicle ostium</li> <li>• Vellus hair</li> <li>• Yellow dots</li> <li>• Telangiectasia</li> </ul>	<ul style="list-style-type: none"> <li>• A. mucinosa</li> <li>• Patchy AA</li> </ul>	5	Eye-brow	None
9	59	M	2	Diffuse	Diffuse	<ul style="list-style-type: none"> <li>• Loss of follicle ostium</li> <li>• Anisotrichosis</li> </ul>	<ul style="list-style-type: none"> <li>• CTE</li> <li>• Diffuse AA</li> </ul>	50	None	None
10	60	F	36	Vertex	1	<ul style="list-style-type: none"> <li>• Loss of follicle ostium</li> <li>• Vellus hair</li> <li>• Erythematous background</li> <li>• Pigtail hair</li> </ul>	<ul style="list-style-type: none"> <li>• Patchy AA</li> <li>• LPP</li> <li>• A. mucinosa</li> </ul>	10	None	Longitudinal ridges

AA: Alopecia areata, LPP: Lichen planopilaris, PPB: Pseudo-pelade of Broque, A. mucinosa: Alopecia mucinosa, CTE: Chronic telogen effluvium, FPA: Female pattern alopecia, TA: Traction alopecia

### Study Limitations

The study was designed as a retrospective cross-sectional study. We did not have a control group for comparing the features.

### Conclusion

Alopecia areata is a well-known hair disease that dermatologists can easily diagnose, but some cases can be exceptional. It is recommended that biopsies be performed on suspected cases, but this still needs to be clearly defined. As a result of our study, we assume that some unexpected trichoscopic features, such as loss of follicle ostium and vellus hair, can be observed in cases with long disease duration. In contrast, typical trichoscopy features, such as exclamation mark hairs, yellow dots, and black dots, are not always detected in these patients. In addition, nail involvement is observed in only a small percentage of patients. In some challenging cases, the diagnosis may require histopathological confirmation and should not be avoided when necessary.

### Ethics

**Ethics Committee Approval:** Committee of the University of Health Sciences Türkiye, Haydarpaşa Numune Training and Research Hospital (approval number: HNEAH-KAEK 2022/KK/5, date: 10.01.2022).

**Informed Consent:** Retrospective study.

### Footnotes

#### Authorship Contributions

Surgical and Medical Practices: G.A., A.Ş.S., Concept: G.A., Design: G.A., Data Collection or Processing: G.A., A.Ş.S., Analysis or Interpretation: G.A., A.Ş.S., Literature Search: G.A., A.Ş.S., Writing: G.A.

**Conflict of Interest:** No conflict of interest was declared by the authors.

**Financial Disclosure:** The authors declared that this study received no financial support.

### References

1. Strazzulla LC, Wang EHC, Avila L, et al.: Alopecia areata: disease characteristics, clinical evaluation, and new perspectives on pathogenesis. *J Am Acad Dermatol.* 2018;78:1-12.
2. Waškiel A, Rakowska A, Sikora M, Olszewska M, Rudnicka L: Trichoscopy of alopecia areata: an update. *J Dermatol.* 2018;45:692-700.
3. Alkhalifah A, Alsantali A, Wang E, McElwee KJ, Shapiro J: Alopecia areata update: part I. Clinical picture, histopathology, and pathogenesis. *J Am Acad Dermatol.* 2010;62:177-88.
4. Shapiro J, Madani S: Alopecia areata: diagnosis and management. *Int J Dermatol.* 1999;38:19-24.
5. Restrepo R, Calonje E: Disease of the hair. McKee's pathology of the skin with clinical correlations. Ed. Calonje E, Brenn T, Lazar AJ, Billings SD. Fifth Ed. UK, Elsevier, 2020;1051-129.
6. Atış G, Ferhatoğlu ZA. Trichoscopic clues for the diagnosis of alopecia areata. *Turkderm-Turk Arch Dermatol Venereol* 2019;54:76-8.
7. Gómez-Quispe H, Muñoz Moreno-Arrones O, Hermosa-Gelbard Á, Vañó-Galván S, Saceda-Corralo D: Trichoscopy in alopecia areata. *Actas Dermosifiliogr.* 2023;114:25-32.
8. Tosti A: Dermoscopy of the hair and nails. 2nd ed. Newyork, CRP Press,2016;51-71.
9. Zhou C, Li X, Wang C, Zhang J: Alopecia areata: an update on etiopathogenesis, diagnosis, and management. *Clin Rev Allergy Immunol.* 2021;61:403-23.
10. Rangu S, Rogers R, Castelo-Soccio L: Understanding alopecia areata characteristics in children under the age of 4 years. *Pediatr Dermatol.* 2019;36:854-8.
11. Chelidze K, Lipner SR: Nail changes in alopecia areata: an update and review. *Int J Dermatol.* 2018;57:776-83.