

**SİGMOİD KOLON KARSİNOMUNA EŞLİK EDEN
CHİLAİDİTİ SENDROMU "OLGU SUNUMU"***CHILAITIDI'S SYNDROME ASSOCIATED WITH SIGMOID
COLON CARCINOMA "CASE REPORT"*

Selman SÖKMEN MD., Cem TERZİ MD., Mehmet FÜZÜN MD., Alper ÇEVİK M MD.,

ÖZET: Chilaiditi Sendromu kolonun sağ subfrenik mesafeye semptomatik interpozisyonudur ve nadir görülmektedir (%0.02-0.22). Çoğu zaman cerrahi bir öneminin olmadığı düşünülmektedir. Ancak, "yanıltıcı psödo pnömoperitonyum" tablosu oluşturarak yanlış tanı konmasına ve gereksiz cerrahi girişimlere neden olabilir. Acil cerrahi girişim gerektiren Chilaiditi sendromu oluşturmuş sigmoid kolon karsinomlu nadir bir olgu tartışılmıştır.

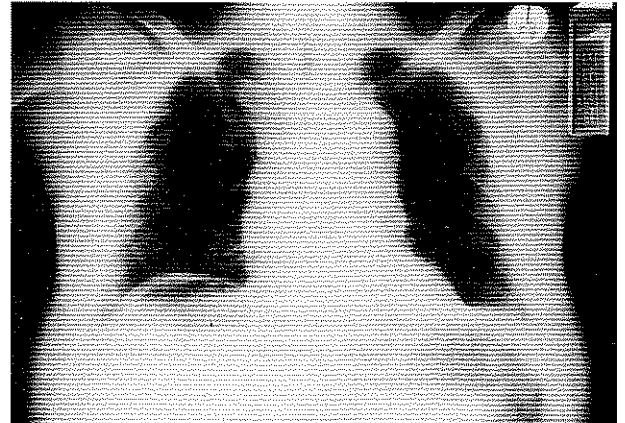Hepatodiaphragmatic interposition of the colon (Chilaiditi's Syndrome) is an uncommon abnormality (1). Although it was first described in 1865, the entity was named after Demetrius Chilaiditi, a Viennese radiologist, who reported three cases in 1910(1,2). Most commonly, it is an incidental radiographic finding (Chilaiditi's sign). The vast majority of these patients are without symptoms; however, abdominal pain, distention, vomiting, anorexia, and constipation may occur. Recognition of Chilaiditi's syndrome is important because this disorder may be easily confused with pneumoperitoneum, ruptured abdominal viscus, subphrenic abscess, all of which require much more aggressive approach(3,5). The hallmark of therapy is conservative(3,4). Rarely, trapping of the intestines has been associated with severe conditions requiring emergency operation: internal hernias, volvulus of the colon and stomach, acute intestinal obstruction and subphrenic appendicitis have been described(1,3,4,6). To our current knowledge, we present the first case report of colonic hepatodiaphragmatic interposition associated with sigmoid carcinoma.

CASE REPORT

An 82-year-old man was admitted with 3-day history of abdominal pain, progressive obstipation, and nausea. He reported some diaphoresis and weight loss. Past medical history was unremarkable. He was not taking any medication and had had no previous operation. On physical examination, he was hemodynamically stable and afebrile. Tympanic and high-pitched bowel sounds were

present in all quadrants of abdomen, which was diffusely tender without rebound. Digital rectal exam did not reveal any abnormality and stool was guaiac negative. There was mild leukocytosis. A posteroanterior chest film showed air between the right hemidiaphragm and liver, and a coin lesion on the right lung (Figure 1). On lateral chest radiograph, distended loops of dilated and elongated large bowel was located beneath an elevated right hemidiaphragm (Figure 2). Thoracoabdominal CT revealed widespread metastatic disease in the liver (Figure 3) and lung, and bowel wall thickening at the sigmoid colon, with the characteristics of Chilaiditi's syndrome. At the operation, an obstructing advanced sigmoid carcinoma was found. The entire markedly dilated hepatic flexura and transverse colon were interposed between the right hemidiaphragm and the right lobe of the liver, where it was entrapped. There was no bowel necrosis or perforation. A

Figure 1. A posteroanterior chest film showing air between right hemidiaphragm and liver, and metastatic coin lesion.



Depts. of Surgery and Emergency Medicine
Dokuz Eylül University, School of Medicine,
Correspondence and reprints address: Selman SÖKMEN, M.D.
651 Sok. No. 8/3 Gazemir, Izmir 35410, Turkey

Figure 2. A lateral chest film indicating haustral markings in the interpositioned colon.

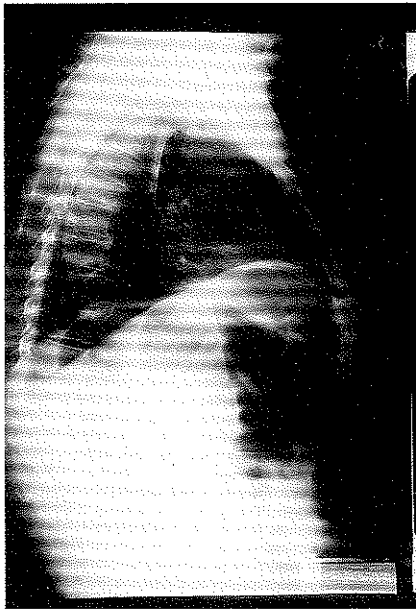
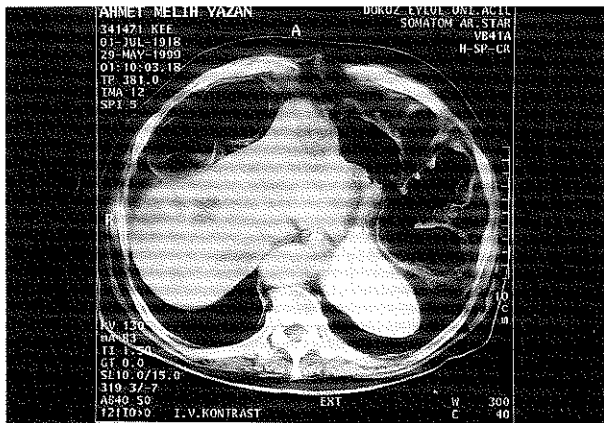


Figure 3. Thoracoabdominal CT scan revealing metastatic disease in the liver and lung with the distended, entrapped segment of colon (Chilaiditi's sign).



Hartmann's procedure was performed. His postoperative course was uneventful. Histopathological analysis of the specimen showed undifferentiated adenocarcinoma of the sigmoid colon.

DISCUSSION

Chilaiditi's syndrome is defined as symptomatic hepatodiaphragmatic colonic interposition. Although mostly asymptomatic and originally considered to be a

radiological curiosity, physicians should be familiar with its radiographic appearance because the syndrome may be associated with various disorders that seem to be reasonably related or without clear connection to the disease(1,3). Chilaiditi's syndrome can cause a wide range of gastrointestinal symptoms especially nausea, vomiting and abdominal pain(4). In our patient, the full-blown symptomatology of this entity was progressively induced by sigmoid neoplasm. Intestinal, hepatic, and diaphragmatic factors have been implicated in the aetiology of this syndrome(1,2,4). Colonic elongation, redundancy and congenital malrotation are known to increase colonic mobility, making interposition more likely. Two clinically pertinent entities that may mimic this syndrome are pneumoperitoneum and subdiaphragmatic abscess(5). This patient's initial clinical presentation and abdominal films were diagnostic for Chilaiditi's syndrome as well as colonic obstruction. Although treatment of patients with Chilaiditi's syndrome is almost always conservative, including bed rest in the supine position and the measures to prevent constipation, it must be noted that this syndrome can be a potential source of abdominal problems requiring emergency or elective operation such as volvulus of the colon(3,4,6) and stomach(3) or as in our case, obstruction of the colon.

Our case is the first case report of colonic interposition associated with colonic carcinoma. This unusual clinical entity can easily be mistaken for more serious abdominal conditions, which may lead to unnecessary surgical mishap. A high index of suspicion is needed for rare cases of Chilaiditi's syndrome as a surgical problem.

REFERENCES

- 1- Plorde JJ, Raker EJ: Transverse colon volvulus and associated Chilaiditi's syndrome: Case report and literature review. *Am J Gastroenterol* 1996; 91: 2613-2616.
- 2- Orangio GR, Fazio VW, Winkelman E, et al : The Chilaiditi syndrome and associated volvulus of the transverse colon. An indication for surgical therapy. *Dis Colon Rectum* 1986; 29: 653-656.
- 3- Haddad CJ, Lacle J: Chilaiditi's syndrome: A diagnostic challenge. *Posgrad Med* 1991; 89: 249-252.
- 4- Bishop CCR, Whitehead SM, Jackson BT: Misdiagnosis of the Chilaiditi syndrome. *Br Med J* 1987; 295: 1655.
- 5- Risaliti A, Anna DD, Terrosu G, et al : Chilaiditi's syndrome as a surgical and nonsurgical problem. *Surgery* 1993; 176: 55-58.
- 6- Takagi Y, Abe T, Nahada T, et al : A case of Chilaiditi's syndrome associated with strangulated volvulus of the sigmoid colon. *Am J Gastroenterol* 1995; 90: 1905.