

UNUSUAL PRESENTATION OF A BIZARRE GASTRIC LEIOMYOBLASTOMA “CASE REPORT”

Selman SÖKMEN, MD, Sedat KARADEMİR, MD, Tarkan ÜNEK, MD,
Sermin ÖZKAL, MD, Ali KÜPELİOĞLU, MD,

ÖZET: Epitolooid gastrik stromal tümörler, gastrik tümörlerin ayrı bir patolojik alt grubunu oluşturur. Malign ve metastatik potansiyelleri, prognozları tartışmalıdır. Bu tümörlerin klinik davranışlarını tayin edebilmek çoğu zaman güçtür, ancak hastaların büyük bir kesimi semptomatiktir ve en sık görülen semptom gastrointestinal hemorajidir. Diğer bazı neoplazmalarla, özellikle gastrik adenokarsinom, birliktelik bildirilmiştir. Bu olgu sunumunda, akut masif gastrointestinal ve intraperitoneal kanama ile başvuran, senkron olarak multiple primer malign tümörlerle birliktelik gösteren bir gastrik stromal tümörün kendisine özgü klinik özellikleri, histolojik bulguları ve prognozu tartışılmıştır.

SUMMARY: Epithelioid gastric stromal tumors form a distinct pathologic subset of gastric tumors whose malignant and metastatic potential and prognosis are controversial. The clinical behavior of these tumors is often difficult to predict, however, a significant number of patients are symptomatic and the most common symptom is gastrointestinal hemorrhage. The association of other neoplasms, particularly carcinoma of stomach have been noted in patients with epithelioid leiomyomatous tumors. Here we report the bizarre clinical features, histologic findings, and prognosis of a gastric stromal tumor presented with acute massive gastrointestinal and intraperitoneal bleeding and with other multiple primary malignant tumors.

Keywords: Bizarre leiomyoblastoma, gastrointestinal hemorrhage, pathology, multiple primary tumors

Although primary non-epithelial neoplasia of the stomach and small bowel constitute the largest category of gastrointestinal stromal tumors, "gastric leiomyoblastoma of Martin's myoid tumor" or "Stout's smooth muscle cell bizarre tumor" is a rare mesenchymal neoplasia (1-5). These tumors raise interest for their uncertain biological evolution, including that 3% to 38% of them have malignant histologic features and that metastasis occurs in up to 68% of these cases (1, 3).

They generally occur in antrum-pyloric region, tend to develop very slowly and to remain intramural. Symptomatology is extremely variable, 21 to 27 percent are asymptomatic, however, most present with symptoms of gastrointestinal bleeding, epigastric pain, and fatigue or malaise suggestive of peptic ulcer disease (1-6). A strikingly high frequency of multiple primary malignant tumors (8 to 27 %) was found in two surveys (4, 5). Instances of coincidental carcinoma of the stomach have

been reported (1, 4, 5, 7, 8). These reports indicate the importance to screen patients carefully for synchronous and metachronous tumors. To improve our understanding of the biologic behavior of gastric leiomyoblastoma, a personal clinical case presented with acute massive upper GI and intraperitoneal bleeding is reported and the most important clinical and anatomopathological aspects are reviewed, particularly focusing on concurrent gastric and pulmonary malignant tumors.

CASE REPORT

A 72-year-old male patient had severe upper GI bleeding and abdominal pain as well as nausea, dispnea, weight loss, and fatigue and was admitted to the hospital. Further examination revealed a distended abdomen, a palpable tumor and tenderness in the epigastric region. He was on medication for an atherosclerotic cardiac disease and primary hypertension since 25 years. He recently operated for chronic occlusive arterial disease and femoro-popliteal by-pass procedure was performed. The patient was hypotensive (90/60 mmHg) and had a tachycardia of 110 beats per minute on admission. The initial laboratory data showed leucocytosis and left shift, a hemoglobin level of 6.9 gr/dL, hematocrit volume of 19 %, and platelet count of 59.000 cu.mm. before resuscitation. At urgent gastroscopy,

Departments of Surgery and Pathology, Dokuz Eylül University
School of Medicine

Correspondence address: Selman Sökmen, MD,

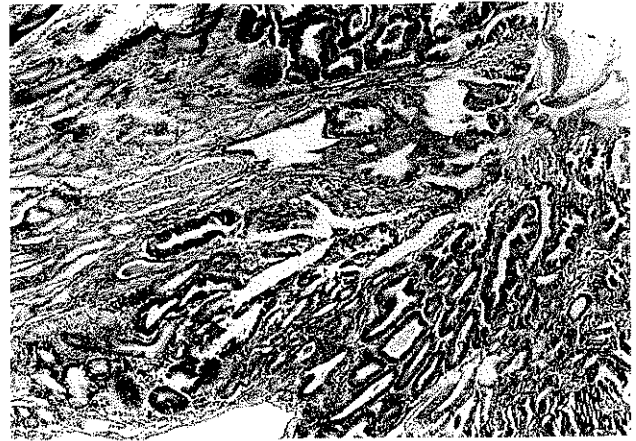Department of Surgery, Dokuz Eylül University School of
Medicine, İzmir 35340, Turkey

large tumor nodule with a deep chronic and bleeding mucosal ulceration at the top involved the greater curvature and partly extending to the lesser curvature of the antrum. Abdominal ultrasonography confirmed only the presence of free liquid throughout the peritoneal cavity. During exploratory celiotomy, the surgeon found a massive hemoperitoneum, the volume of blood aspirated was over 1500 ml, and the source of the bleeding by irregular, lobulated and pediculated exogastric and ulcerated tumoral mass. Highly-vascularized tumor located in the antrum was 12 cm in diameter. A subtotal gastrectomy was performed, and the continuity was re-established by a gastrojejunostomy. There were no complications in the postoperative course. Histopathologic analysis revealed a smooth muscle tumor of borderline malignancy and early intestinal type gastric adenocarcinoma in the proximity of the index tumor (Fig. 1). The tumor was composed of cells with varied size and shape. Apart from spindle and epitheloid cells, occasional giant cells could also be observed. Mitotic counts was 1/50 high power field. Immunohistochemical stains showed intense cytoplasmic reactivity for vimentin, focal reactivity for neuron specific enolase and S-100 protein. No immunoreactivity was demonstrated with desmin. After the operation, a chest radiologic examination revealed rounded pulmonary lesions and enlarged mediastinal lymph nodes that were considered as metastases. However, bronchoscopic biopsies of the tumoral lesion showed carcinoma of the left lung and lymphangitis carcinomatosa. Supportive care of the patient was recommended at the Tumor Board. The patient died 5 months later due to multiple organ system failure,

DISCUSSION

Gastric leiomyoblastomas (GLs) are uncommon, and detailed information on their natural history, the relationship of pathologic characteristics to clinical behavior and methods of treatment is still incomplete. In a study done in 1962, 108 different pathologic diagnosis were assigned to 69 patients (1-5). A new histologic entity, the so-called bizarre leiomyoblastoma, was identified from this inhomogeneous pool (1-5, 7). These tumors tend to occur later in life, the median age of the patients is 60 years, and the incidence is significantly higher in men than women (1-6, 9). They usually have nonspecific symptoms, some series suggest that in 81 % of the cases the finding of a GI stromal tumor was a matter of chance (3). The most common presentations are pain and gastrointestinal bleeding (1,3,5,10). The overlying mucosa of many submucosal tumors tends to ulcerate (31 to 51 %) (1-5, 7, 9). McGrath et al. demonstrated that digestive hemorrhage occurs in 40 % of GLs (1-5). Thus, they frequently present an emergency basis: there were series in which almost 60 % of all GLs needed urgent surgical intervention as in our case (2-6, 9, 10). However, the main cause of urgent surgical approach was not only massive upper GI bleeding but also an extremely rare complication of GLs, a severe

Fig. 1. A smooth muscle tumor of borderline malignancy and early intestinal type gastric adenocarcinoma



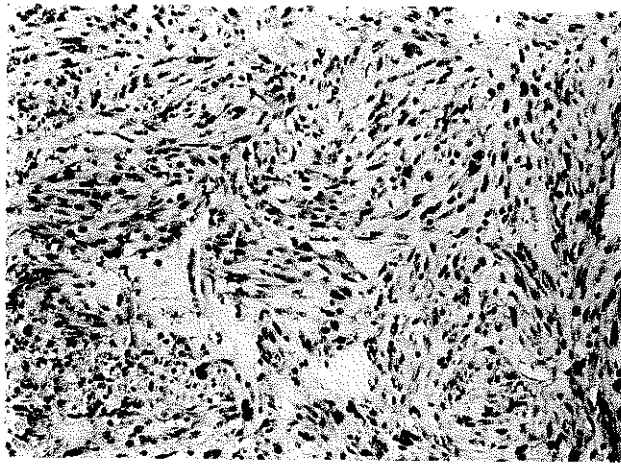
hemoperitoneum, in our patient. A cramping, postprandial, mid-abdominal pain can also develop in patients having large polyps or pediculated non-epithelial tumors located near the pylorus that prolapse through the pylorus into the duodenum with peristaltic activity. They may also present with other symptoms such as anorexia, nausea, vomiting, loss of weight and even fever. Physical findings are non-revealing in the vast majority of patients.

Three gross patterns- intramural, endogastric and exogastric -were defined according to the relation of the muscular wall of the stomach and the main body of the tumor (1, 7-9). They are multiple in 2.3 to 7.0 % of the patients (1). The least common are the exogastric or pediculated variety. Size varies from 0.4 to 35.0 cms, with 20 percent being more than 10.0 cms (1, 7, 8). Ninety percent occur in the antrum or body of the stomach (1,3,7,9). In our case, the antrally placed tumor measuring 12 cm. in diameter was friable, exogastric mass with vascular necrotic signals and partly intraluminal growth.

It is not possible to assign specific characteristics that would separate leiomyoblastomas from other smooth muscle tumors. Histologically, they are composed of interlacing fascicles and whorls of elongated cells (Fig. 2) (1, 2).

Spindle tumor cells with acidophilic fibrillary cytoplasm and the presence of cytoplasmic vacuoles at both ends of the nucleus should suggest smooth muscle differentiation. An epitheloid appearance is also more likely to be associated with evidence of smooth muscle differentiation. They are composed of rounded cells with central nucleus and usually abundant acidophilic or clear cytoplasm (Fig. 3) (9). This cytoplasmic clearing appears to be result of fixation artifact (7). A prominent myxoid matrix may be present in between the tumor cells (Fig. 4). These tumors are characterized by a remarkable cellular variability and their malignant potential is sometimes difficult to predict (1,2,7,9). Very recent studies, using mitotic count and tumor size as the best determinants of biological behavior divide GLs into three groups: benign, borderline and

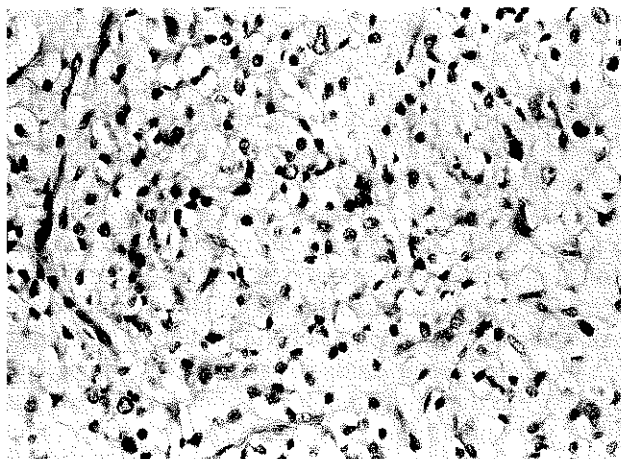
Fig. 2. Leiomyoblastomas are composed of interlacing fascicles and whorls of elongated cells.



malignant tumors (1, 3, 7, 8). However, this division can not solve the difficulty of predicting the clinical course in individual patients with GLs of gastric origin. Large size (>5cm), of which was seen in the current case, high mitotic activity, which was not observed, aneuploidy, and higher S-phase fraction have been reported to be of prognostic significance (5, 7). The prognosis for patients with metastasizing and/or recurrent GLs has been found to be poor, but long-term survival has also been reported in a few patients after oncologically correct surgical treatment (2, 3, 6). The largest series estimates the metastatic rate at 12 percent (1, 2). Metastases typically involve the liver, omentum and peritoneal surface. Lymph node and distant involvement are unusual. On the other hand, multiple primary malignant tumors were reported in different series of patients with GLs: 11 of the 41 patients (27%) had a second or even a third cancer, and in four patients, the other malignancies presented synchronously with the gastric tumor, while in five they developed at a later date (2-4).

Instances of coincidental carcinoma of the stomach have

Fig. 3. Typical rounded cells with central nucleus and abundant acidophilic or clear cytoplasm



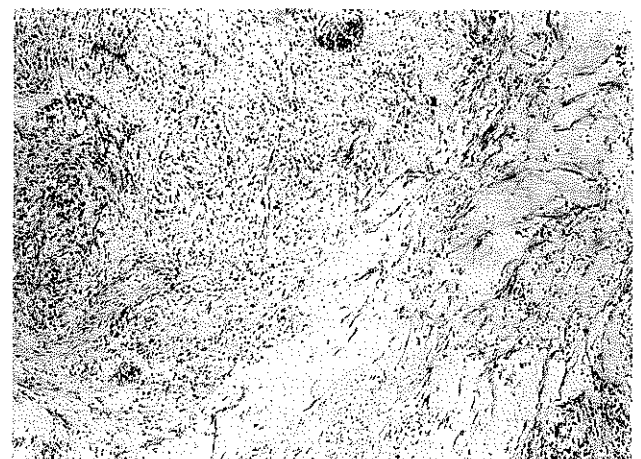
been reported (1, 4, 5, 7, 8). The occurrence of two very rare neoplasms, pulmonary chondromas and functioning extraadrenal paragangliomas, have been described with GLs (Carney triad) (1,6,7,9). Two synchronous primary neoplasms, early gastric and lung carcinoma, were diagnosed in our patient through active surgical strategy. This bizarre presentation indicates the need to investigate patients carefully for synchronous and metachronous tumors.

Total resection of the tumor is the proper surgical treatment for GLs (1-6). Tumoral resection would include, if necessary, adjacent organs infiltrated by the neoplasm in order to secure the appropriate margins of resections. In contrast, with metastases from abdominal carcinomas, GLs producing abdominal metastases usually do not have deep infiltration into other structures, so it often is possible to remove them with local radical operation (1-6). Although knowledge about the chemotherapeutic sensitivity of GLs is at present limited, several authors advocate tumor removal in the presence of liver metastases as it usually has a slow growth rate and adjuvant chemotherapy may benefit it (2, 4, 5). Radiation therapy may be reasonably applied in conditions where residual microscopic disease in the tumor bed is likely, such as with infiltrating exogastric tumors (2, 4, 5).

Subtotal gastric resection was performed safely for complete tumor excision in our high risk patient with bizarre and life-threatening presentation. However, the combined magnitude of tumor burden of two primary cancers and complication probably played an important role for the dismal prognosis of this patient.

From a clinical standpoint, during the immediate management of a patient who has GL and subsequent follow-up examinations, the physician must be alert to the possible simultaneous presentation or future development of another primary cancer, because detection and treatment of the second primary tumor may be equally important to the continued survival of the patient.

Fig. 4. Between the tumor cells, a prominent myxoid may be present



REFERENCES

1. Nelson RS, Lanza FL: Benign and malignant tumors of the stomach (other than carcinoma). In Berk JE (ed): *Bockus Gastroenterology*. 4 th Ed., Philadelphia, WB Saunders Company, 1985, vol 2, pp: 1255-1277.
2. Persson S, Kindblom LG, Angervall L, et al. : Metastasizing gastric epithelioid leiomyosarcomas (leiomyoblastomas) in young individuals with long term survival. *Cancer* 1992; 70: 721-732.
3. Lee JSY, Nascimento AG, Farnell MB, et al. : Epithelioid gastric stromal tumors (leiomyoblastomas): A study of fifty-five cases. *Surgery* 1995; 118: 653-661.
4. Shiu MH, Farr GH, Papachristou DN, et al. : Myosarcomas of the stomach. *Cancer* 1982; 49: 177-187.
5. Graham SM, Ballantyne GH, Modlin IM: Gastric epithelioid leiomyomatous tumors. *Surg Gynecol Obstet* 1987; 164:391-397.
6. Ng EN, Pollock R, Romsdahl MM: Prognostic implications of patterns of failure for gastrointestinal leiomyosarcomas. *Cancer* 1992; 69: 1334-1341.
7. Rosai J. Gastrointestinal tract. In: Rosai J (ed): *Ackerman's Surgical Pathology*. 8 th Ed., St Louis, Mosby, 1996, pp: 616-666.
8. Owen DA. Stomach. In: Sternberg SS (ed): *Diagnostic Surgical Pathology*. 2 nd Ed., New York, Raven Press, 1994, pp: 1279-1310.
9. Cornog JL Jr. Gastric leiomyoblastoma. A clinical and ultrastructural study. *Cancer* 1974; 34: 711-719.
10. Karatzas G, Kouraklis G, Delladetsima J, et al. Massive intraperitoneal hemorrhage caused by a giant exogastric leiomyoblastoma. *Surg Today* 1998; 3: 293-295.