

CLINICAL APPLICATION OF TEMPOROPARIETAL FASCIAL FLAP IN RECONSTRUCTION OF TRAUMATIC ORBITAL DEFORMITIES

TRAVMATİK ORBİTA DEFORMİTELERİNİN REKONSTRÜKSİYONUNDA TEMPOROPARIETAL FASYA FLEBİNİN KLİNİK UYGULAMASI

Dr. Aylin B.KARABULUT*, Dr. Burçak TÜMERDEM ÇAĞ*, Dr. Atilla ARINCI*,
Dr. Metin EREK*, Dr. Cemalettin ERTEKİN**

ÖZET: Temporoparietal-galeal flep travmaya bağlı kontrakte soket ve periorbital deformite rekonstrüksiyonunda iyi vaskülarize bir doku sağlaması açısından güvenilir bir fleptir. Bu çalışmada minimal donör morbiditeye yol açarak temporoparietal fasyal flebi uyguladığımız 5 hastayı sunmaktayız.

Anahtar kelimeler: Travmatik orbital rekonstrüksiyonu, Temporo-parietal fasyal flep

SUMMARY: Temporoparietal-galeal flap provides a reliable source of pliable, well vascularized local tissue capable of reconstructing contracted eye socket and periorbital deformities due to trauma. We present five patients whom we applied temporoparietal fascial flap successfully with minimal donor morbidity. The results were quite satisfactory.

Key words: Traumatic orbital reconstruction, Temporo-parietal fascial flap

INTRODUCTION

The presence of two independent vascular territories in the temporal region permits separate utilisation of muscle and fascia in the elevation of the regional flaps. The temporoparietal fascia and overlying skin are supplied by the superficial temporal artery providing the axial-pattern fascial and fasciocutaneous flaps (1). Fox and Edgerton first drew attention to the use of well-vascularized fascia and muscle in the temporal region (2). Avelar and Psillakis in 1981 and Maillard et al. in 1984 proposed galeal flap in facial reconstruction (2,3). In this study, we would like to report the use of temporoparietal fascial flap in complicated eye socket and periorbital reconstruction.

MATERIAL AND METHOD

We used temporoparietal fascial flap for 5 patients. These patients 2 female, 3 male ranged in age from 16 to 27 years. All of the patients had orbital

deformities due to trauma. One of the patients had globe perforation as a stone had struck to his eye in early childhood. After enucleation, socket deformation had occurred (Figure 1). The patients had used ocular prosthesis previously but they could not use anymore because of socket contraction. Two of them had undergone operation for socket reconstruction by split thickness grafting before, but the results were not satisfactory.




Figure 1: Preoperative view of the male patient who had undergone enucleation after globe perforation due to trauma in childhood. Contracted eye socket is seen.

* I.U. Istanbul Faculty of Medicine, Department of Plastic ve Reconstructive Surgery

** I.U. Istanbul Faculty of Medicine, Department of General Surgery

Yazışma Adresi: Dr. Aylin Bilgin KARABULUT

I.U. Istanbul Faculty of Medicine, Department of Plastic ve Reconstructive Surgery

SURGICAL TECHNIQUE

A preauricular incision is made and extended superiorly into the scalp. After the elevation of scalp flaps in the immediate subfollicular plane, the temporoparietal fascia is exposed (Figure 2,3). The flap pivots about the entry point of vascular pedicle into the fascia just above the zygomatic arch. The distal limit of the flap is planned according to the size of the defect. The temporoparietal fascia is incised and easily dissected off the underlying deep temporal fascia. The flap is transferred to the defective area (Figure 4,5). The donor site is closed primarily.

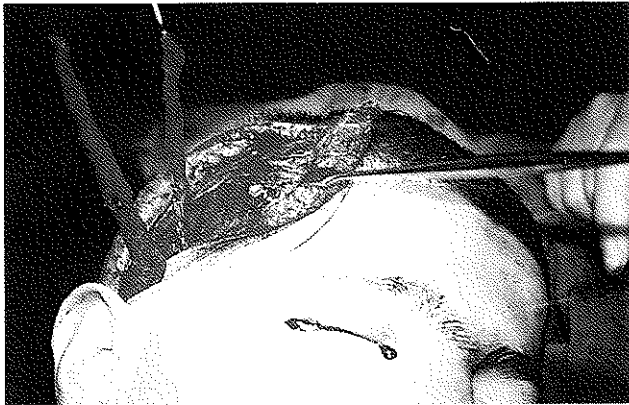

Figure 2: Peroperative view of the male patient.

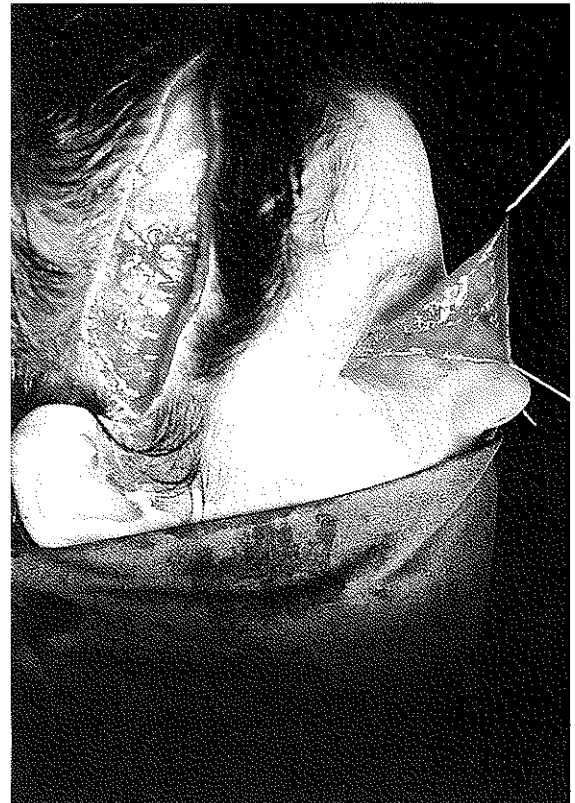


Figure 4: Peroperative view of the female patient. The donor site is seen. The temporoparietal fascial flap is transferred to the socket.

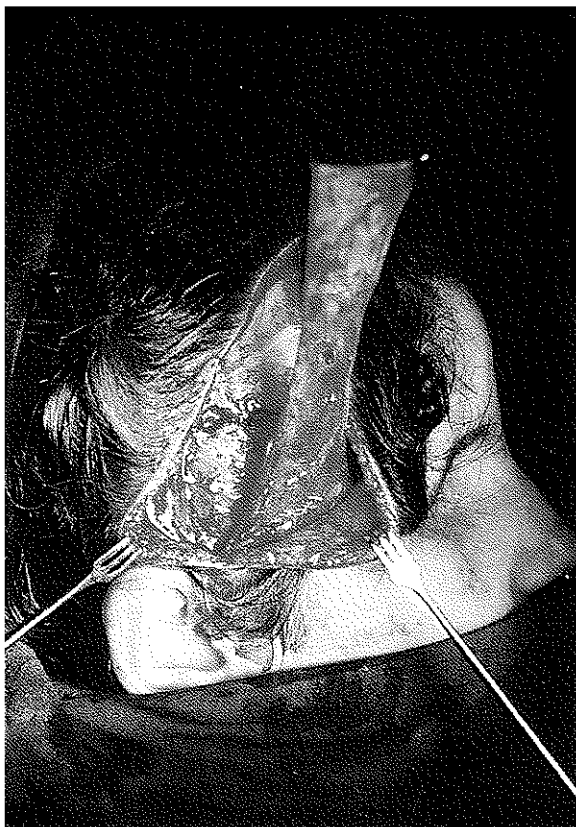

Figure 3: Peroperative view of the female patient to whom temporoparietal fascial flap is applied because of socket contraction due to trauma. The flap is elevated.

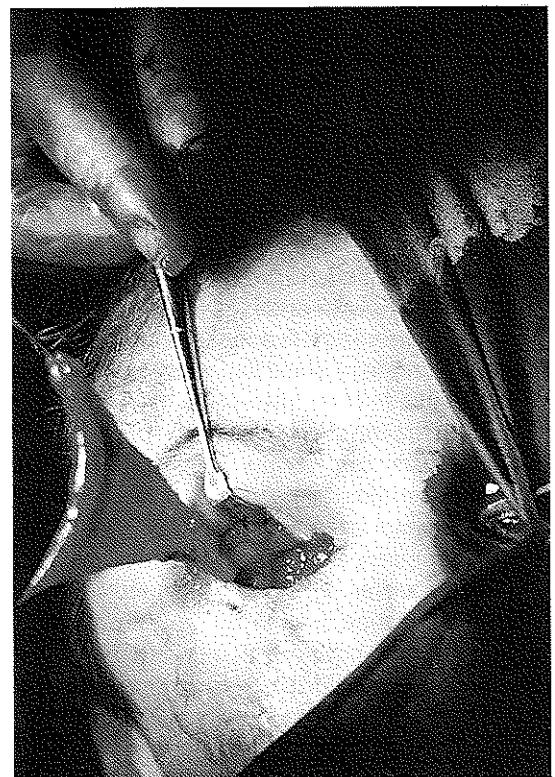


Figure 5: Peroperative view of the female patient. The defective area and the transferred flap is seen.

DISCUSSION

The temporoparietal fascia is a thin layer of moderately dense connective tissue which lies immediately deep to the hair follicles and subdermal fibrofatty tissue. It is continuous with galea superiorly and subcutaneous musculoaponeurotic system inferiorly. It is richly vascularized by the superficial temporal artery and vein. Superficial temporal artery is a terminal branch of arteria carotid externa. It crosses the zygomatic arch in front of the ear and courses superiorly within the fascia while its corresponding vein lies more superficial in the immediate subfollicular plane.

The temporoparietal fascia provides a large amount of tissue and transferred as an axial flap for reconstruction of facial defects.

As it is vascularized, thin and pliable tissue it is used in the reconstruction of auricular deformity without obscuring contour and details (4). Besides, it is used to augment the blood supply to the recipient bed of the free bone graft without adding excessive soft tissue bulk (1)

In this study, we used this flap for periorbital region deformities and contracted socket reconstruction.

Inadequate surgical technique of enucleation, removal of eye during infancy, postoperative irradiation therapy and trauma cause severe deformities in the orbital and periorbital regions and result in contracted eye socket (5). This situation restricts the application of the ocular prosthesis.

For a successful reconstruction, a socket covered with well-vascularized epithelial surface and having adequate volume must be formed. Traditional methods such as mucosa and skin grafts may be effective especially if they are used in proper size and shape with an oversize mould to keep the reconstructed socket open during healing process (6)

More recently attempts have been made to provide neovascularity to the eye socket and a better recipient site for graft.

Temporoparietal fascial flap is well suited for orbital and eyelid reconstruction because of its proximity to the orbit, good vascularity and less donor site morbidity (7)

A prefabricated temporal island flap which is prepared by a skin graft applied over the temporalis fascia and transposed into the eye socket 3 weeks later, has been used to solve unsatisfactory results of traditional socket reconstruction methods (5,8)

As beautifully demonstrated by Smith (1980) and Brent et al (1985), the temporoparietal fascia provides an excellent tissue for free transfer (9) It has been used in complex reconstruction situation in hand and foot. It provides thin layer of vascularized covering tissue with good gliding properties on the underside to allow for the movement of the tendons (10)

One of the main advantages of temporoparietal fascial flap is that it gives the possibility to preserve the desired shape for prosthesis. As it has high and constant vascularity, it

can preserve its original volume for periorbital reconstruction more predictably than nonvascularized grafts of fat and dermis (11)

Finally, the result is aesthetically satisfactory with low donor morbidity. (Figure 6,7)

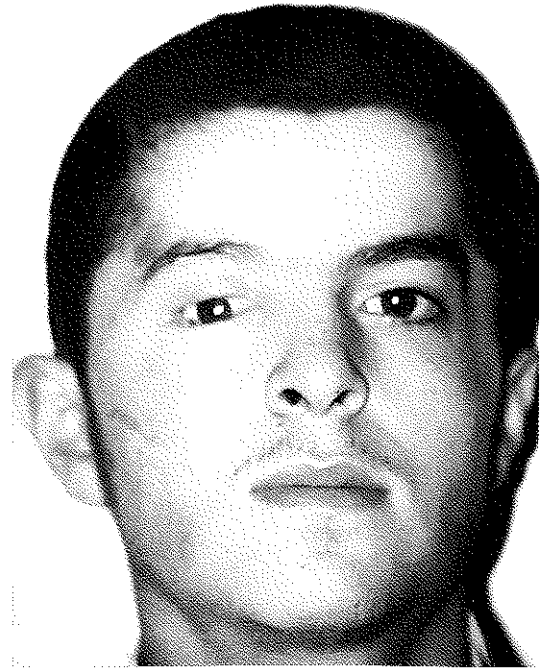


Figure 6: Postoperative view of the male patient (AP). He use his ocular prosthesis without any difficulty.

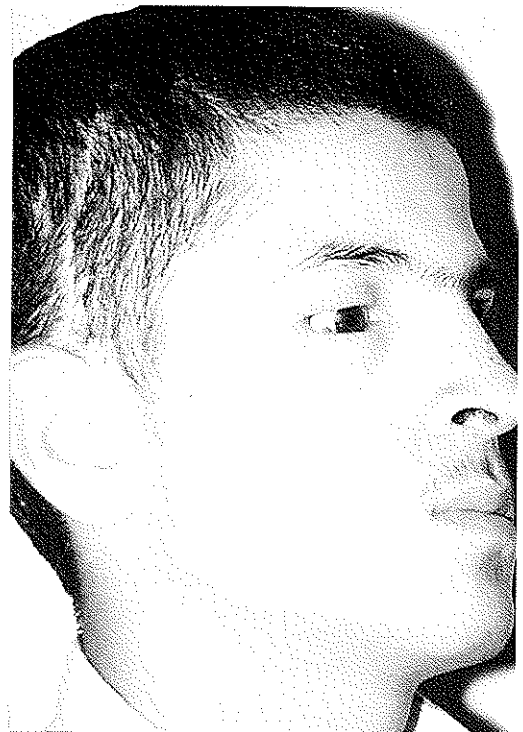

Figure 7: Postoperative view of the male patient (LAT). Note the donor site has minimal deformity.

REFERENCES

1. Antonyshyn O, Birt BD :Versality of temporalis muscle and fascial flap.Br.J. Plast.Surg. 41,118-131,1998
2. Fox JW,Edgerton MT :The fan flap ;An adjunct to ear reconstruction.Plast. Reconstr. Surg.58:663,1976
3. Avelar JM and Psillakis : The use of galea flaps in craniofacial deformities Ann. Plast.Surg. 6:464,1981
4. Cotlar SW : Reconstruction of burned ear using temporal fascial flap.Plast. Reconstr. Surg. 71:45,1983
5. Altıntaş M,Aydın Y,Yücel A : Eye socket reconstruction with the prefabricated temporal island flap. Plast. Reconstr. Surg.102(4):980-7,1998
6. Zajacz M : Reconstruction of the consricted orbital cavity in patients with artificial anophthalmia.Acta. Chir.Hung. 36:1-4,395-7,1997
7. Ellis DS,Toth BA,Stewart WB : Temporoparietal fascial flap for orbital and eyelid reconstruction. Plast. Reconstr. Surg.17-24,1986
8. Erol O,Parsa DF,Spira M : The use of a secondary island graft-flap in reconstruction of the burned ear.Br.J. Plast. Surg. 34-147,1981
9. Brent B,Upton J,Acland RD et al : Experience with the temporoparietal fascial free flap. Plast. Reconstr. Surg. 76-177,1985
10. Hussein SA,Grace von DA,Robert DA:Surgical anatomy and blood supply of the temporal region. Plast. Reconstr. Surg.17-24,1986
11. Fukuta K,Jackson IT,Collares MU et al:The volume limitation of the galeal temporalis flap in facial augmentation. Br.J. Plast. Surg. 44,281-284,1991