

# The management of testicular torsion: A survey of Turkish pediatric surgeons and pediatric urologists

✉ Furkan Adem Canbaz, ✉ Gonca Gerçel, ✉ Sefa Sag

Department of Pediatric Surgery, Sancaktepe Şehit Prof. Dr. İlhan Varank Training and Research Hospital, İstanbul-Türkiye

## ABSTRACT

**BACKGROUND:** This study aimed to evaluate the approaches of pediatric surgeons and pediatric urologists in Türkiye regarding the diagnosis and treatment of testicular torsion (TT) and their adherence to the European Association of Urology (EAU) pediatric urology guideline.

**METHODS:** A survey consisting of 19 questions, accompanied by an annotation describing the objective of the study, was emailed to pediatric surgeons and pediatric urologists in June and July 2023.

**RESULTS:** Of the 95 respondents, 62.1% had over 10 years of experience, and 48.4% treated more than five cases of TT annually. Of the participants, 87.4% stated that scrotal Doppler ultrasonography (US) was always used, and 12.6% stated that US was used in cases of doubtful diagnosis. Concerning treatment, 14.7% reported performing manual detorsion, 70.5% never did, and 14.7% did so only if the operating room was unavailable soon. A total of 92.6% of participants opted for emergency surgery. Among participants who perform manual detorsion, 71.4% perform surgery within 24 hours after successful manual detorsion. Regarding fixation of the contralateral testicle, 14.7% never performed it, and 27.4% did so only when they performed an orchiectomy on the torsion testicle.

**CONCLUSION:** While most participants follow EAU pediatric urology guidelines by performing emergency surgery, the rate of manual detorsion is low. Few participants stated that emergency surgery may not be performed after manual detorsion. While all of the participants performed fixation of the torsion testicle in accordance with the guidelines, the same adherence was not observed in the contralateral testicle.

**Keywords:** Emergency; survey, testicular torsion.

## INTRODUCTION

The incidence of testicular torsion (TT) in children under 18 years of age is approximately 3.8 per 100,000.<sup>[1]</sup> This common urologic emergency is a surgical condition that may result in organ loss and requires prompt intervention. Shortening the duration between diagnosis and treatment provides salvage of a torsion testicle.

Pediatric surgeons and pediatric urologists' approaches to diagnosing and treating patients with TT may differ. The conditions of the clinics they have been trained and work at may

create these different approaches.

The European Association of Urology (EAU) pediatric urology guideline recommends manual detorsion without anesthesia in patients with TT. It highlights that scrotal Doppler ultrasonography (US) might be used for diagnosis but should not cause a delay in diagnosis. However, emergency surgical intervention within the first 24 hours and fixation of contralateral healthy testicles are also recommended by the EAU pediatric urology guideline, despite successful manual detorsion. Furthermore, it does not recommend a preferred type of surgical incision, fixation method, or suture material to be used.<sup>[2]</sup>

Cite this article as: Canbaz FA, Gerçel G, Sag S. The management of testicular torsion: A survey of Turkish pediatric surgeons and pediatric urologists. *Ulus Travma Acil Cerrahi Derg* 2024;30:685-693.

Address for correspondence: Furkan Adem Canbaz

Sancaktepe Şehit Prof. Dr. İlhan Varank Training and Research Hospital, İstanbul, Türkiye

E-mail: ademcanbaz@gmail.com

*Ulus Travma Acil Cerrahi Derg* 2024;30(9):685-693 DOI: 10.14744/tjtes.2024.52932

Submitted: 06.07.2024 Revised: 03.08.2024 Accepted: 07.08.2024 Published: 02.09.2024

OPEN ACCESS This is an open access article under the CC BY-NC license (<http://creativecommons.org/licenses/by-nc/4.0/>).



In this study, the approaches of pediatric surgeons and pediatric urologists in Türkiye to the diagnosis and treatment of TT were evaluated. It was also aimed to assess the adherence of participants to the section of TT published in the EAU pediatric urology guideline in the diagnosis and treatment of TT.

## MATERIALS AND METHODS

The survey, prepared with an annotation describing the objective and importance of this survey study, was sent to pe-

diatric surgeons and pediatric urologists via email in June and July 2023. Participants' approaches to a 13-year-old boy presenting with acute scrotal pain were evaluated using a developed survey. The survey was composed of 19 questions, six of which were intended to determine the participants' demographics. Other questions evaluated participants' approaches to scrotal Doppler US, preferred treatment options, timing of treatment, and surgical method in the treatment of TT. All questions are provided in Table 1.

**Table 1.** Survey questions regarding approaches to the diagnosis and treatment of testicular torsion (TT)

- |  |  |
|--|--|
| 1. What is your gender?  | B. Only in cases of doubtful diagnosis   |
| A. Male  | C. Never, torsion is a clinical diagnosis  |
| B. Female  | 8. Who performs the scrotal US?  |
| 2. How old are you?  | A. I always prefer it to be performed by a radiologist   |
| A. Under 30  | B. I prefer it to be performed by a radiologist if it can be done promptly, otherwise, I perform it myself     |
| B. 30-39   | C. If my US findings are doubtful, I prefer an evaluation by a radiologist                                     |
| C. 40-49   | D. US is not indicated in cases with a clinical presentation suggesting torsion                                |
| D. 50-59   | 9. Do you perform closed manual detorsion?   |
| E. Above 60  | A. Yes, with local anesthesia  |
| 3. What is your academic title?  | B. Yes, without anesthesia to evaluate response to pain  |
| A. Professor   | C. Only when the operating room is not available soon  |
| B. Associate Professor   | D. No, I never perform it  |
| C. Assistant Professor   | 10. How do you evaluate the success of manual detorsion?   |
| D. Pediatric surgeon   | A. If pain completely resolves   |
| E. Pediatric urologist   | B. I check with US   |
| 4. What kind of hospital are you working in?                                   | C. If the testicle comes up to the same level with the other testicle  |
| A. Faculty of medicine   | D. I do not perform manual detorsion   |
| B. Training and research hospital/City hospital                                | 11. Do you perform emergency surgery?  |
| C. Women's maternity and children's hospital                                   | A. Yes, always   |
| D. State hospital  | B. Yes, even after successful manual detorsion   |
| E. Private hospital  | C. No, I prefer not to. I only perform emergency surgery if manual detorsion fails or if failure is suspected. |
| F. Private office  | 12. When do you perform orchiopexy after successful manual detorsion?  |
| G. Retired, not actively working   | A. I do not perform manual detorsion; I perform emergency surgery instead                                      |
| 5. How long have you been a specialist physician?                              | B. I perform emergency surgery as soon as possible after manual detorsion                                      |
| A. Less than 5 years   | C. Within 24 hours   |
| B. 5-10 years  | D. Within 72 hours   |
| C. More than 10 years  | E. On my first scheduled operation day   |
| 6. How many cases of TT do you treat individually each year?                   |  |
| A. 0   |  |
| B. 1-2   |  |
| C. 3-5   |  |
| D. More than 5   |  |
| 7. Do you request scrotal ultrasonography (US) for patients with suspected TT? |  |
| A. Yes, always   |  |

F. Only if TT recurs	17. How do you fixate the testicles?
13. Which incision do you prefer?	A. By passing a suture deep through the tunica albuginea and testicular parenchyma
A. Vertical scrotal median raphe incision	B. By passing a suture as superficially as possible through the tunica albuginea
B. Transverse scrotal incision	C. By passing a suture through peritesticular tissues to preserve testicular parenchyma
C. Inguinal and scrotal incision	D. I do not fixate the testicles
D. Inguinal incision only	18. With how many sutures do you perform the fixation of testicles?
14. Do you open tunica vaginalis during surgery?	A. I do not fixate testicles following detorsion
A. Yes, always. I use the Winkelmann procedure to suture it behind the spermatic cord	B. I perform 1-point fixation
B. Yes, always, but I do not use the Winkelmann procedure	C. I perform 2-point fixation
C. No	D. I perform 3-point fixation
15. Which suture material do you use for the fixation of testicles?	19. Do you fixate the contralateral healthy testicle?
A. I do not fixate	A. Yes, I always fixate
B. Absorbable monofilament	B. I fixate it if there is evidence of torsion on the contralateral side
C. Nonabsorbable monofilament	C. I fixate contralateral testicle if I perform orchiectomy for the torsioned testicle
D. Absorbable multifilament	D. I never fixate
E. Nonabsorbable multifilament	
16. To which structure do you fixate the testicles?	
A. Tunica vaginalis	
B. Tunica dartos	
C. I do not fixate following detorsion	

TT: Testicular Torsion; US: Ultrasonography.

Only respondents who completed the questionnaire were included. The study was approved by the institutional Ethics Committee (Date: June 14, 2023, decision number: 103).

### Statistical Analysis

Descriptive analysis of the demographic characteristics of the participants and the survey responses was conducted using IBM SPSS Statistics Software Version 25 (IBM Corp., Armonk, NY, USA).

## RESULTS

Of the 95 specialists who participated in the study by completely answering the survey, 56.8% were male and 43.2% were female. Most of the respondents (62.1%) had more than 10 years of professional experience. The annual number of cases with TT treated individually was more than 5 in 48.4%.

While 83 participants (87.4%) always preferred scrotal Doppler US to be performed, 12 participants (12.6%) considered US only in the case of a doubtful diagnosis. Manual detorsion was performed in any case by 14.7% of the participants. Among the respondents, 70.5% reported that they never perform manual detorsion, while 14.7% reported that they perform it only when the operating room will not be available soon. Of the 28 participants who performed manual detorsion, 23 (82.1%) reported that they evaluated the success of manual detorsion by using US and 5 (17.9%) by response to

pain. Regarding the consistent performance of manual detorsion, it was carried out by 75% of pediatric urologists, 10.6% of pediatric surgeons, and 7.5% of participants with academic staff roles. Performing manual detorsion in every case was observed in 41.2% of professionals with less than 5 years of experience, 21.1% of those with 5-10 years of experience, and 5.1% of those with more than 10 years of experience.

Of the respondents, 92.6% reported that they performed emergency surgery immediately. Furthermore, 9.5% of the participants performed emergency surgery even after a successful manual detorsion. Among the 28 participants who perform manual detorsion, 71.4% perform surgery within the first 24 hours after successful manual detorsion. Performing emergency surgery (regardless of whether manual detorsion was successful) was observed in 97.5% of participants with academic degrees, 91.5% of pediatric surgeons, and 75.0% of pediatric urologists. Among professionals with less than 5 years of experience, 23.5% believed that emergency surgery could not be performed if manual detorsion was successful. This belief was not observed in those with 5-10 years of experience (0%) and was held by 5.1% of those with more than 10 years of experience.

In regard to the surgical approach, 58.9% of the participants preferred a scrotal median raphe incision. Absorbable suture material was used by 60.0% of the participants, non-absorbable sutures by 33.7%, and 6.3% reported not fixing

the testicles at all. Among the participants, 87.4% reported performing 3- or 2-point fixation, while 7.4% reported performing 1-point fixation.

Fixation of a contralateral healthy testicle was never performed by 14.7%, always performed by 53.7%, and performed only when orchiectomy for a torsion testicle was performed by 27.4%. The rate of routine fixation of the contralateral testicle was similar among academic staff, pediatric surgeons, and pediatric urologists, at 55%, 51.1%, and 62.5%, respectively. Additionally, it was practiced by 70.6% of professionals with less than 5 years of experience, 52.6% of those with

5-10 years of experience, and 49.2% of those with more than 10 years of experience. All results about demographic features and participants' responses to questions are presented in Table 2 and Table 3.

## DISCUSSION

TT is the most common cause of testicular ischemia in children. Testicular salvage rates can be as high as 90% when correction of torsion is achieved within 6 hours, but this falls rapidly to 50% at 12 hours, and less than 10% at 24 hours. Delay in intervention is more likely to result in orchiectomy, with

**Table 2.** Distribution of participants by demographic and general characteristics

	Participants (n)	Percentage (%)
Gender		
Male	54	56.8
Female	41	43.2
Age		
Under 30 years	6	6.3
30-39 years	14	14.7
40-49 years	43	45.3
50-59 years	22	23.2
Above 60 years	10	10.5
Title		
Professor	17	17.9
Associate Professor	16	16.8
Assistant Professor	7	7.4
Pediatric Surgeon	47	49.5
Pediatric Urologist	8	8.4
Type of Hospital		
Faculty of medicine	29	30.5
Training and research hospital/city hospital	34	35.8
Women's maternity and children's hospital	4	4.2
State hospital	9	9.5
Private hospital	9	9.5
Private office	7	7.4
Retired, not actively working	3	3.2
Occupational Experience		
Less than 5 years	17	17.9
5-10 years	19	20.0
More than 10 years	59	62.1
Annual Number of TT Cases Treated Individually		
0	3	3.2
1-2	21	22.1
3-5	25	26.3
More than 5	46	48.4

**Table 3.** Participants' responses to survey questions

	Participants (n)	Percentage (%)
Do you request scrotal ultrasonography (US) for patients with suspected testicular torsion (TT)?		
Yes, always	83	87.4
Only in cases of doubtful diagnosis	12	12.6
Never, torsion is a clinical diagnosis	0	0
Who performs the scrotal US?		
I always prefer it to be performed by a radiologist	85	89.5
I prefer it to be performed by a radiologist if it can be done promptly, otherwise, I perform it myself	3	3.2
US is not indicated in cases with a clinical presentation suggesting torsion	7	7.4
Do you perform closed manual detorsion?		
Yes, I perform it with local anesthetic administered to the spermatic cord	0	0
Yes, I perform it without anesthesia, which allows for evaluating the response to pain	14	14.7
I perform it only when the operating room is not available promptly	14	14.7
No, I never perform it	67	70.5
How do you evaluate the success of manual torsion?		
If pain completely disappears	5	5.3
I check with US	23	24.2
If the testicle comes up to the same level with other testicle	0	0
I do not perform manual detorsion	67	70.5
Do you perform emergency surgery?		
Yes, always	79	83.2
Yes, I even after successful manual torsion	9	9.5
No, I prefer not to. I only perform emergency surgery if manual detorsion fails or if failure is suspected	7	7.4
When do you perform orchiopexy after successful manual detorsion?		
I do not perform manual detorsion; I perform emergency surgery instead	67	70.5
I perform emergency surgery as soon as possible after manual detorsion	17	17.9
Within 24 hours	3	3.2
Within 72 hours	1	1.0
On my first scheduled operation day	6	6.3
Only if TT recurs	1	1.0
Which incision do you prefer?		
Vertical scrotal median raphe incision	56	58.9
Transverse scrotal incision	20	21.0
Inguinal and scrotal incision	10	10.5
Inguinal incision only	9	9.5
Do you open tunica vaginalis during surgery?		
Yes, always. I use the Winkelman procedure to suture it behind the spermatic cord	34	35.8
Yes, always, but I do not use the Winkelman procedure	60	63.2
No	1	1.0
Which suture material do you use for the fixation of testicles?		
I do not fixate	6	6.3
Absorbable monofilament	19	20.0
Nonabsorbable monofilament	25	26.3
Absorbable multifilament	38	40.0

Nonabsorbable multifilament	7	7.4
To which structure do you fixate the testicles?		
Tunica vaginalis	20	21.0
Tunica dartos	70	73.7
I do not fixate following detorsion	5	5.3
How do you fixate the testicles?		
By passing a suture deep through the tunica albuginea and testicular parenchyma	18	18.9
By passing a suture as superficially as possible through the tunica albuginea	61	64.2
By passing a suture through peritesticular tissues to preserve testicular parenchyma	11	11.6
I do not fixate the testicles	5	5.3
With how many sutures do you perform the fixation of testicles?		
I do not fixate testicles following detorsion	5	5.3
I perform 1-point fixation	7	7.4
I perform 2-point fixation	29	30.5
I perform 3-point fixation	54	56.8
Do you fixate the contralateral healthy testicle?		
Yes, I always fixate	51	53.7
I fixate it if there is evidence of torsion on the contralateral side	4	4.2
I fixate contralateral testicle if I perform orchiectomy for the torsioned testicle	26	27.4
I never fixate	14	14.7

TT: Testicular Torsion; US: Ultrasonography.

a subsequent decrease in fertility and hormonal function.<sup>[3]</sup>

Since TT can lead to organ loss if not diagnosed and treated early, it is crucial to standardize the approach. Scientific guidelines are essential in this regard, as they help clinicians make informed decisions by integrating the highest quality and most current scientific evidence with the patient's personal circumstances, values, and preferences. This survey investigated the practices of physicians treating TT in children in Türkiye and assessed how these practices align with the TT section of the EAU pediatric urology guideline. The primary aim was to determine whether the recommendations of this

guideline, which are based on robust scientific evidence, were being implemented.

In this survey, the majority of participants seemed to follow the EAU pediatric urology guideline's recommendations for emergency surgery, but manual detorsion was not a common practice among them. It was also observed that some participants believed emergency surgery might not be performed after manual detorsion. All participants adhered to the guideline for fixation following detorsion; however, the same level of adherence was not observed for the fixation of the contralateral testicle (Fig. 1).

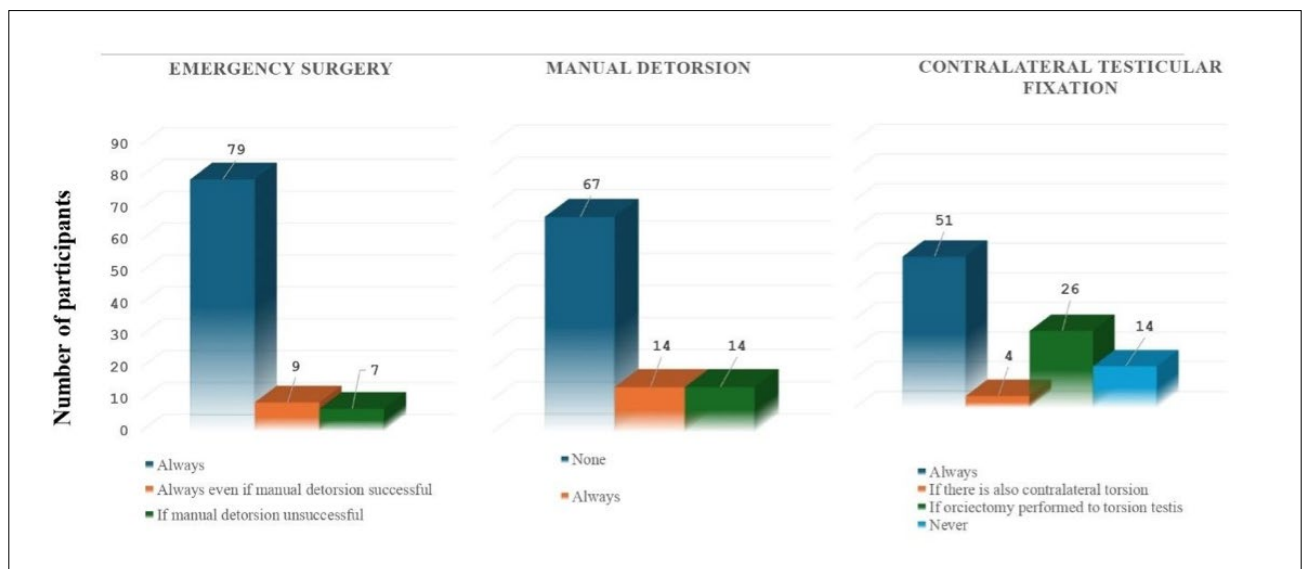


Figure 1. Number of respondents performing emergency surgery, manual detorsion, and contralateral testicular fixation.

Scrotal color Doppler ultrasonography (US) is the imaging method of choice for differentiating pathologies causing acute scrotum. The sensitivity, specificity, positive predictive value, and negative predictive value of scrotal Doppler US for detecting TT were 100%, 75.2%, 80.4%, and 100%, respectively.<sup>[4]</sup> Teurneau-Hermansson reported that in cases with a moderate level of clinical suspicion, a scrotal doppler US performed within one hour after admission was shown to be effective in clarifying the diagnosis of TT.<sup>[5]</sup> Thus, it was demonstrated that the rate of negative surgical explorations could be reduced without increasing the rate of underdiagnosed cases of TT. Scrotal doppler US has also been shown not only to diagnose TT, but also to evaluate the viability of testicles by heterogeneity index through examination of testicular parenchyma. Thus, anesthetic complications of emergency surgery might be avoided in cases where organ loss is certain.<sup>[6]</sup>

The EAU pediatric urology guideline highlights that scrotal Doppler US is beneficial in diagnosis but should not delay surgical intervention. It is stated in the guideline that the decision should be made based on the patient's physical examination findings. In a survey study conducted by Almaramhy, 60% of pediatric urologists performed scrotal Doppler US preoperatively, whereas this ratio was found to be 25% among pediatric surgeons.<sup>[7]</sup> In another survey study, Van Doeveren et al.<sup>[8]</sup> reported that 64% of the participants always performed scrotal Doppler US, whereas 32% preferred US only in the case of a doubtful diagnosis.<sup>[8]</sup> In this study, the vast majority of the participants always performed scrotal Doppler US to diagnose TT. The remaining, however, preferred the US in the case of a doubtful diagnosis.

The Testicular Workup for Ischemia and Suspected Torsion (TWIST) score can be used in patients with acute scrotal pain. TWIST may eliminate the need for scrotal Doppler US and decrease ischemic time and the cost of care.<sup>[9]</sup>

Manual detorsion has been shown to reduce the duration of ischemia in TT.<sup>[10]</sup> Although TT is a genuine surgical emergency, the time between diagnosis and surgery can often be prolonged. The mean surgical waiting time for emergency exploration after diagnosis has been reported to be approximately four hours.<sup>[11]</sup> Factors such as patient transfer within the hospital, preoperative preparation, evaluation by the anesthesia team, and the availability of an operating room can contribute to these delays. In this context, it is evident that performing manual detorsion promptly upon diagnosis can help reduce ischemia time. Success rates of manual detorsion vary in the literature. Manual detorsion has been shown to be successful at a rate of 95.1% in patients with TT who admit within the first 24 hours after the onset of symptoms and to increase the salvage of testicles.<sup>[12]</sup> Russo et al. achieved success in manual detorsion of 80.5% of the patients and stated that admission within the first five hours and mild scrotal edema are important for success in manual detorsion.<sup>[11]</sup> The EAU pediatric urology guideline recommends performing manual detorsion without anesthesia in all cases of TT when avail-

able, as it is associated with improved surgical salvage rates. In this study, the majority of the participants reported they did not perform manual torsion routinely. However, performing manual detorsion as recommended by the guideline was more commonly practiced among pediatric urologists and professionals with less than five years of experience. Nobody performed manual detorsion under anesthesia.

It has been stated that although improvement of pain and examination findings indicate a successful manual detorsion, assistance from US may be sought. Russo et al. also emphasized the importance of confirmation with US along with improvement of pain and examination findings following manual detorsion.<sup>[11]</sup> Performance of manual detorsion in the emergency department under guidance of US has been shown to be beneficial for demonstrating the recovery of testicular blood supply.<sup>[13]</sup> In the present study, the vast majority of those performing manual detorsion also evaluated the success using US.

Although manual detorsion was considered successful based on clinical response and/or ultrasound findings, precise prediction of its success was not always possible. In 27.8% of patients who underwent preoperative manual detorsion, intraoperative residual torsion or re-torsion was detected.<sup>[12]</sup> Furthermore, residual torsion may still be present in patients with abnormal ultrasound findings, even when pain has been completely resolved. Similarly, the same study demonstrated that residual torsion can occur in patients who experience incomplete pain relief despite improved ultrasound findings.<sup>[14]</sup> The guideline also recommends surgical intervention and bilateral orchiopexy within the first 24 hours after successful manual detorsion.<sup>[2]</sup> More than half of those who perform manual detorsion perform emergency surgery within the first 24 hours, although the ratio of those delaying surgery was considerable. Among those with less than five years of experience, the belief that emergency surgery was unnecessary if detorsion was successful was more common compared to their more experienced colleagues. Pediatric urologists were more likely to believe that emergency surgery might not be necessary if manual reduction was successful. Adherence to the guideline is observed in the routine performance of manual detorsion among professionals with less experience and pediatric urology specialists. However, these participants also believe that emergency surgery may not be necessary following successful manual detorsion, which indicates a lack of adherence to the guideline in this regard. Additionally, we believe that individuals with less professional experience should be regarded as having up-to-date knowledge, as they have recently completed their surgical training.

In a survey study from the Netherlands, it is observed that emergency surgery is performed less frequently (77% of participants) and manual detorsion is applied more often (63% of participants) compared with this current survey.<sup>[8]</sup>

Numerous methods have been used by surgeons to fix the



testes and prevent re-torsion in TT. Although it has been reported in the literature that a dartos pouch, 3-point testicular fixation, the use of non-absorbable sutures, or eversion and then suturing of the tunica vaginalis with the Jaboulay procedure may be used for prevention of re-torsion, there is no consensus about it.<sup>[15]</sup> Clement et al. recommended testicular fixation with sutures following detorsion in adults, while they reported that, in pediatric patients, it might be fixated with sutures or only by placement of the testicle into a preformed dartos pouch without using sutures.<sup>[16]</sup> They reported that, for suture fixation, non-absorbable sutures or polydioxanone sutures, which are absorbed after a long period of time, may be used. Although the use of non-absorbable sutures is safe for preventing re-torsion, it has been reported that they may cause the formation of microabscess foci and pain. It has been noted that the use of absorbable sutures, however, may raise medico-legal concerns with possible re-torsion. They emphasized that suture fixation may be as 3- or 4-point fixation. Fixation of the contralateral healthy testicle is also recommended. Re-torsion following testicular fixation is likely, though rare. Although the use of absorbable sutures is blamed for recurrent torsion, Sells et al. reported that, with complete eversion of the tunica vaginalis, adhesions occurring between the testicle and scrotum may prevent re-torsion.<sup>[17,18]</sup>

In a survey study from Poland conducted by Piotrowska-Gall et al., including pediatric surgeons and pediatric urologists, 98% of the participants reported that they fixate the torsioned testicle, and 69% reported that they always fixate the contralateral testicle. It was reported that fixation of the contralateral testicle was not performed at all by 2% of participants, whereas 28% stated that they fixate the contralateral testicle in patients for whom they perform orchiectomy for the torsioned testicle. It was also demonstrated that 30% of the participants perform contralateral testicular surgery a few weeks after the primary surgery, justifying this due to torsion-induced intensive scrotal inflammation.<sup>[19]</sup>

A survey conducted with 95 pediatric surgeons in the United Kingdom and Ireland revealed that 85% of the participants perform testicular fixation with sutures, and 15% with a dartos pouch or Jaboulay procedure. Almost all (95%) participants were found to fixate the contralateral testicle.<sup>[20]</sup>

The EAU pediatric urology guideline recommends the fixation of testicles if the testis will be preserved after detorsion and also the fixation of the contralateral testicle.<sup>[2]</sup> In this study, the majority of the participants reported that they perform testicular fixation after detorsion. Among fixation materials, the use of absorbable sutures seemed to be more common. For contralateral fixation, however, a considerable portion (46.3%) of the participants stated that they never fixate the contralateral testicle or that they fixate it when an orchiectomy is performed for the torsioned testicle. While the rate of contralateral testicular fixation is similar among pediatric urologists, pediatric surgeons, and academic professionals, it

is more commonly practiced by those with less than 5 years of experience compared to their more experienced counterparts. Adherence to the guideline regarding contralateral fixation of a healthy testis was lower among participants with more than 5 years of experience.

This study has some limitations which must be acknowledged. Despite great efforts to include all pediatric surgeons and pediatric urologists (who deal with TT) working in Türkiye, the number of respondents who completed the questionnaire is small. An important limitation of the study is that the number of pediatric urologists, who were intended to form a substantial part of the sample, was significantly lower than anticipated. Secondly, the study is limited to surgeons from Türkiye; therefore, it would be beneficial to compare the data with professionals in other countries.

## CONCLUSION

TT is a pathology that requires emergency intervention. The majority of participants appeared to perform emergency surgery in accordance with the EAU pediatric urology guidelines. However, adherence to the guidelines regarding manual detorsion before surgery was less consistent, with this practice being performed infrequently among respondents. It was also noted that there were participants who considered that emergency surgery could not be performed following manual detorsion. All participants were performing fixation following detorsion as recommended by the EAU pediatric urology guideline; however, the same situation was not observed for the fixation of the contralateral healthy testicle.

**Ethics Committee Approval:** This study was approved by the Sancaktepe Şehit Prof. Dr. İlhan Varank Training and Research Hospital Ethics Committee (Date: 14.06.2023, Decision No: 103).

**Peer-review:** Externally peer-reviewed.

**Authorship Contributions:** Concept: F.A.C., G.G., S.S.; Design: F.A.C., G.G., S.S.; Supervision: F.A.C., G.G., S.S.; Resource: F.A.C.; Materials: F.A.C.; Data collection and/or processing: F.A.C., S.S.; Analysis and/or interpretation: F.A.C., G.G.; Literature search: F.A.C.; Writing: F.A.C.; Critical reviews: F.A.C., G.G., S.S.

**Conflict of Interest:** None declared.

**Financial Disclosure:** The author declared that this study has received no financial support.

## REFERENCES

1. Zhao LC, Lutz TB, Meeks JJ, Maizels M. Pediatric testicular torsion epidemiology using a national database: incidence, risk of orchiectomy and possible measures toward improving the quality of care. *J Urol* 2011;186:2009–13. [\[CrossRef\]](#)
2. Radmayr C, Bogaert G, Burgu B, Castagnetti MS, Dogan HS, O'Kelly F, et al. EAU guidelines on pediatric urology presented at the EAU Annual Congress Milan 2023. ISBN 978-94-92671-19-6. European Association of Urology Guidelines Office, Arnhem, The Netherlands, 2023. <https://>



- uroweb.org/guidelines/paediatric-urology.
- Osumah TS, Jimbo M, Granberg CF, Gargollo PC. Frontiers in pediatric testicular torsion: An integrated review of prevailing trends and management outcomes. *J Pediatr Urol* 2018;14:394–401. [CrossRef]
  - Altinkilic B, Pilatz A, Weidner W. Detection of normal intratesticular perfusion using color coded duplex sonography obviates need for scrotal exploration in patients with suspected testicular torsion. *J Urol* 2013;189:1853–8. [CrossRef]
  - Teurneau-Hermansson K, Zindovic I, Jakobsson J, Navntoft A, Nozohor Ekmark A, Salö M, et al. Doppler ultrasound improves diagnostic accuracy for testicular torsion. *Scand J Urol* 2021;55:461–5. [CrossRef]
  - Sanson P, Hartman C, Palmerola R, Rahman Z, Siev M, Palmer LS, et al. Ultrasonographic assessment of testicular viability using heterogeneity levels in torsed testicles. *J Urol* 2017;197:925–30. [CrossRef]
  - Almaramhy HH. Surgical practice among pediatric surgeons and pediatric urologists in the Kingdom of Saudi Arabia for the management of suspected testicular torsion. *Saudi Med J* 2018;39:1232–7. [CrossRef]
  - van Doeveren T, Somani BK, 't Hoen LA, Haensel SM. Real-world management of testicular torsion: Level of adherence to the EAU Pediatric Urology guidelines. *J Pediatr Urol* 2023;19:117–24. [CrossRef]
  - Roberts CE, Ricks WA, Roy JD, Hartin CW, Alemyehy H. Testicular workup for ischemia and suspected torsion in pediatric patients and resource utilization. *J Surg Res* 2021;257:406–11. [CrossRef]
  - Demirbas A, Demir DO, Ersoy E, Kabar M, Ozcan S, Karagoz MA, et al. Should manual detorsion be a routine part of treatment in testicular torsion? *BMC Urol* 2017;17. [CrossRef]
  - Russo T, Cozzi DA, Gaglione G, Ceccanti S. The role of manual detorsion in pediatric testicular torsion during the global COVID-19 Pandemic: Experience from 2 centres. *Urology* 2023;180:227–34. [CrossRef]
  - Dias Filho AC, Oliveira Rodrigues R, Riccetto CLZ, Oliveira PG. Improving organ salvage in testicular torsion: Comparative study of patients undergoing vs not undergoing preoperative manual detorsion. *J Urol* 2017;197:811–7. [CrossRef]
  - Manivel V, Mirmiran B. Ultrasound-guided manual testicular detorsion in the emergency department. *J Emerg Med* 2020;58:85–92. [CrossRef]
  - Vasconcelos-Castro S, Flor-de-Lima B, Campos JM, Soares-Oliveira M. Manual detorsion in testicular torsion: 5 years of experience at a single center. *J Pediatr Surg* 2020;55:2728–31. [CrossRef]
  - van Welie M, Qu LG, Adam A, Lawrentschuk N, Laher AE. Recurrent testicular torsion post orchidopexy - an occult emergency: a systematic review. *ANZ J Surg* 2022;92:2043–52. [CrossRef]
  - Clement KD, Light A, Asif A, Chan VWS, Khadhoury S, Shah TT, et al. A BURST-BAUS consensus document for best practice in the conduct of scrotal exploration for suspected testicular torsion: the Finding consensus for orchidopexy In Torsion (FIX-IT) study. *BJU Int* 2022;130:662–70.
  - Moore SL, Chebbout R, Cumberbatch M, Bondad J, Forster L, Hendry J, et al. Orchidopexy for testicular torsion: a systematic review of surgical technique. *Eur Urol Focus* 2021;7:1493–503. [CrossRef]
  - Sells H, Moretti KL, Burfield GD. Recurrent torsion after previous testicular fixation. *ANZ J Surg* 2002;72:46–8. [CrossRef]
  - Piotrowska-Gall A, Stepien P, Wolak P. A survey of current practice in operative management of testicular torsion in Poland. *Child (Basel, Switzerland)* 2023;10. [CrossRef]
  - Bolln C, Driver CP, Youngson GG. Operative management of testicular torsion: current practice within the UK and Ireland. *J Pediatr Urol* 2006;2:190–3. [CrossRef]

## ORIJİNAL ÇALIŞMA - ÖZ

### Testis torsiyonunun yönetimi: Türk çocuk cerrahları ve çocuk ürologları arasında anket çalışması

Furkan Adem Canbaz, Gonca Gerçel, Sefa Sag

Sancaktepe Şehit Prof. Dr. İlhan Varank Eğitim ve Araştırma Hastanesi, Çocuk Cerrahisi Kliniği, İstanbul, Türkiye

**AMAÇ:** Bu çalışmada Türkiye'deki çocuk cerrahlarının ve çocuk ürologlarının testis torsiyonunun (TT) tanı ve tedavisine yönelik yaklaşımlarının ve European Association of Urology (EAU) pediatrik üroloji kılavuzuna uyumunun değerlendirilmesi amaçlandı.

**GEREÇ VE YÖNTEM:** Çalışmanın amacını açıklayan bir notla birlikte 19 sorudan oluşan bir anket, Haziran 2023 ve Temmuz 2023'te çocuk cerrahisi ve çocuk ürolojisi uzmanı hekimlere e-posta yoluyla gönderildi.

**BULGULAR:** Ankete katılan 95 kişiden %62.1'inin 10 yıldan fazla mesleki deneyimi vardı. %48.4'ü yılda 5'ten fazla TT vakasını tedavi ettiğini belirtti. Katılımcıların %87.4'ü skrotal Doppler ultrasonografiyi (US) her zaman kullandığını, %12.6'sı US'yi tanıda şüphe varsa kullandığını bildirdi. Tedaviyle ilgili olarak, %14.7'si manuel detorsiyonu daima yaptığını, %70.5'i hiç yapmadığını ve %14.7'si yalnızca ameliyathanein hemen müsait olmaması durumunda yaptığını belirtti. Katılımcıların %92.6'sı acil ameliyatı tercih etmekteydi. Manuel detorsiyon yapan katılımcıların %71.4'ü manuel detorsiyon başarılı olsa dahi 24 saat içinde ameliyat gerçekleştirmektedir. Kontralateral testisin fiksasyonu ile ilgili olarak %14.7'si hiç yapmamakta, %27.4'ü ise sadece torsiyone testise orşiektomi uyguladığında yapmaktaydı.

**SONUÇ:** Katılımcıların çoğu acil cerrahi müdahalede EAU pediatrik üroloji kılavuzunu takip ederken, manuel detorsiyon uygulama oranı oldukça düşüktür. Çok az katılımcı manuel detorsiyon sonrası acil ameliyatın yapılamayabileceğini belirtti. Katılımcıların tamamı torsiyone testisin fiksasyonu kılavuzuna uygun olarak gerçekleştirenken, karşı testiste aynı uyum gözlenmedi.

**Anahtar sözcükler:** Acil; anket; testis torsiyonu.

*Ulus Travma Acil Cerrahi Derg* 2024;30(9):685-693 DOI: 10.14744/tjtes.2024.52932