

# The effect of distal ureteral lateralization angle on ureteral trauma avoidance and successful ureteral access sheath placement

Metin Yiğman,<sup>1</sup> Hale Çolakoğlu Er<sup>2</sup>

<sup>1</sup>Department of Urology, Ankara Etlik Integrated Health Campus, Ankara-Türkiye

<sup>2</sup>Department of Radiology, Ankara Guven Hospital, Ankara-Türkiye

## ABSTRACT

**BACKGROUND:** The use of ureteral access sheaths (UAS), which offer advantages in flexible ureteroscopic lithotripsy (fURL), may lead to undesirable conditions such as ureteral injury, ischemia, and prolonged ureteral stenosis. The aim of this study was to investigate the effect of the distal ureteral lateralization angle on successful UAS placement.

**METHODS:** We analyzed the data of patients who underwent fURL for kidney and/or proximal ureteral stones retrospectively. Based on the preoperative computed tomographic examinations of the patients, the bladder outlet was considered the zero point. We calculated the angle values between the horizontal axis passing through this point and the most lateralized point of the distal ureter. The patients were divided into two groups: those to whom UAS was successfully placed and those to whom UAS placement failed.

**RESULTS:** No significant difference was detected between the groups with successful UAS placement (n=36) and those without UAS placement (n=12) in terms of sex, laterality, localization, number of stones, stone burden, and bladder volumes evaluated with preoperative computed tomography ( $p>0.05$ ). However, a significant difference was found between the two groups regarding age and distal ureteral lateralization angle ( $p<0.001$ ,  $p=0.013$ ).

**CONCLUSION:** The distal ureteral lateralization angle is considered to be an effective factor in the placement of UAS in patients scheduled for fURS.

**Keywords:** Ureteroscopy; ureterorenoscopy; ureteral access sheath; ureteral curvature; ureteral angle.

## INTRODUCTION

Flexible ureteroscopic lithotripsy (fURL) is generally recognized as an effective treatment for proximal ureter or kidney stones. In addition, ureteral access sheaths (UAS) are instruments extensively utilized in fURL, known for advantages such as providing better visual clarity, avoiding increased intrapelvic pressure, and increasing the effectiveness of the surgical procedure. However, the use of these instruments may lead to undesirable conditions such as ureteral injury, ischemia, and

long-term ureteral stenosis.<sup>[1,2]</sup>

Moreover, challenges are also experienced in placing UASs, which are used considering their advantages, into the ureter. <sup>[1]</sup> In the literature, failure rates in the placement of UAS vary between 3% and 22%.<sup>[3-6]</sup> This failure may occur due to ureteral strictures, narrow ureteral orifices, anatomical variations, and the inappropriate diameter of the UAS used. Additionally, in the first and only study in the literature, Cho et al. found that the ureteral angle, determined by the level of the bladder

Cite this article as: Yiğman M, Çolakoğlu Er H. The effect of distal ureteral lateralization angle on ureteral trauma avoidance and successful ureteral access sheath placement. *Ulus Travma Acil Cerrahi Derg* 2024;30:671-676.

Address for correspondence: Metin Yiğman

Ankara Etlik Integrated Health Campus, İstanbul, Türkiye

E-mail: m.yigman@hotmail.com

*Ulus Travma Acil Cerrahi Derg* 2024;30(9):671-676 DOI: 10.14744/tjtes.2024.67996

Submitted: 10.05.2024 Revised: 10.05.2024 Accepted: 08.08.2024 Published: 02.09.2024

OPEN ACCESS This is an open access article under the CC BY-NC license (<http://creativecommons.org/licenses/by-nc/4.0/>).



outlet and the most lateral portion of the distal ureter, may be a contributing factor to UAS placement failure.<sup>[7]</sup>

In such cases, the placement of a ureteral stent before the procedure is strongly recommended to help passively expand the ureter, enhancing the success rates of the procedure and reducing the complication rate.<sup>[8]</sup> However, in addition to the costs of two-stage surgery and the possibility of increased anesthesia complications, the stent placement is also likely to cause complaints such as frequency, urgency, dysuria, incomplete emptying, flank and suprapubic pain, incontinence, and hematuria.<sup>[9]</sup> For all these reasons, it is crucial for the surgeon to predict the success of the operation and counsel patients appropriately.

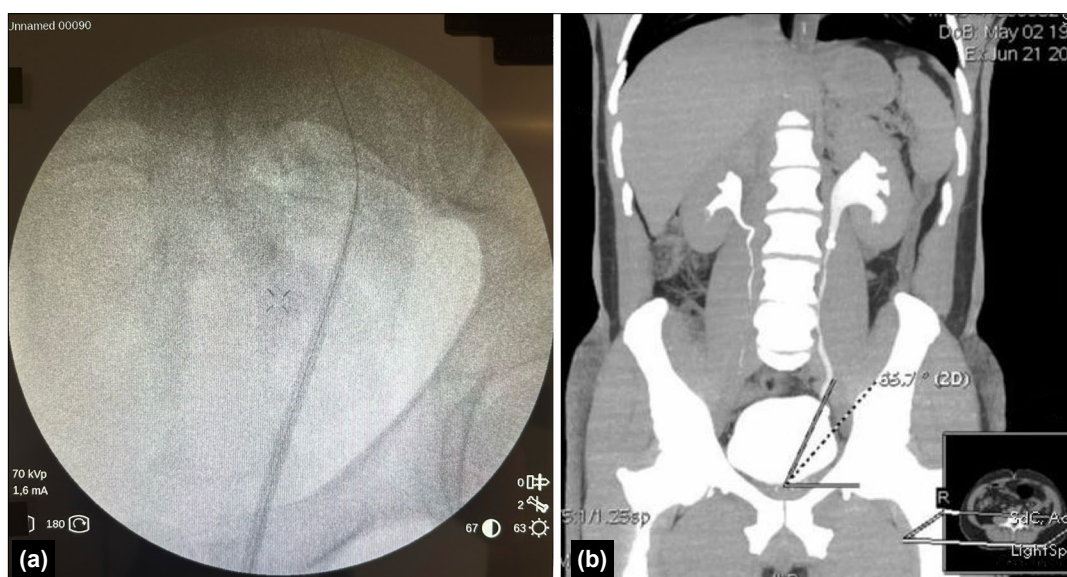
In our study, we aimed to investigate the impact of the distal ureteral lateralization angle on UAS insertion during fURL in a virgin ureter.

## MATERIALS AND METHODS

The study was approved by the University Faculty of Medicine Clinical Research Ethics Committee (Date: November 11, 2021, decision no: 2021.11.11.01/14). The data of patients who underwent the fURS procedure by a single surgeon for kidney and/or proximal ureteral stones between January 2020 and November 2021 were analyzed retrospectively. Patients with a diagnosis of primary urolithiasis were included in the study. Patients aged under 18 years, those who had undergone a previous ureteroscopy for any reason, had a ureteral stent placement, underwent extracorporeal shock wave lithotripsy (ESWL), had a history of spontaneous stone passage, as well as pregnant women and male patients with a prostatic median lobe, were excluded from the study. Patients were divided

into two groups: those in whom the ureteral access sheath was successfully placed during surgery and those in whom it was not placed in the distal ureter. The distal ureteral lateralization angle was calculated by a single radiologist, without reporting the patient groups, for patients whose computed tomography (CT) images were available in the hospital data system before the intervention.

Under general anesthesia, the urethral meatus was accessed under visualization with a 20 Fr cystoscope (Karl Storz®, Tuttlingen, Germany) in the dorsal lithotomy position. It was confirmed that there was no urethral stenosis, bladder neck stenosis, or prostatic median lobe. The ureteral orifice on the related side was dilated under direct monitoring with a 5 Fr / 5 mmx10 cm balloon dilator (Geotek®, Ankara, Türkiye) for 2 minutes at 18 atm pressure. Subsequently, the 9.5 Fr rigid ureteroscope (URS) (Karl Storz®, Tuttlingen, Germany) was utilized to reach the proximal part of the ureter, and it was confirmed that there were no pathological formations such as intraluminal stones or stenosis. The ureteroscope was removed after 0.035-inch hydrophilic nitinol sensor guidewires (Rüsch/Teleflex®, Athlone, Ireland) were advanced into the involved renal pelvis and left in the lumen. After the bladder was emptied with a cystoscope, a disposable 9.5/11.0 Fr UAS (Flexor™, Cook Medical®, Bloomington, IN, USA), 28 cm in female patients and 35 cm in male patients, was advanced through the guide under visualization with scopy (Fig. 1A). In patients with resistance to the progression of the UAS, a ureteral double J stent (Plasti-med®, Istanbul, Türkiye) was placed, and the procedure was postponed to a second session. Before ureteral double J stent placement, ureteral damage was checked by examining again under direct vision with URS. In patients with the UAS placed, the operation continued as planned. The same routine steps were conducted



**Figure 1.** (a). Endoscopic visualization of the ureteral access sheath unable to be advanced due to the distal ureteral lateralization angle. (b) Angle measurement calculation, depicted using a computed tomography (CT) urography phase from a patient in the study to enhance the clarity of the description compared to non-contrast CT.

by repeating, as all procedures were performed by a single surgeon.

**Imaging Technique:** CT imaging was performed on a 16-slice CT device (LightSpeed General Electric Company, Milwaukee, USA). Preoperative non-enhanced computed tomography for urinary stones was performed in all patients. No patient preparation was required, except for assuring a full urinary bladder. Patients were positioned supine on the CT table with their arms elevated. Then, scans were obtained from the dome of the liver to the ischial tuberosities using 1.25 mm slice thickness.

Bladder volumes were calculated for all patients to evaluate differences in bladder filling volume that may be effective in the placement of the UAS.<sup>[10]</sup> The stone burden was also calculated from CT images using the formula for ellipsoid volume ( $D1 \times D2 \times D3 \times \pi/6$ ).<sup>[11]</sup>

The angle between the bladder outlet and the most lateral part of the lower ureter was measured on a workstation (Advantage Workstation 4.6) using coronal reformatted images. The bladder outlet point was accepted as the zero point when measuring the angle between the bladder outlet and the most lateral part of the lower ureter (Fig. 1B).

### Statistical Analysis

Descriptive statistics were used to report the characteristics of the study groups stratified according to UAS success. Continuous variables were assessed for normal distribution using scatter plots and the Shapiro-Wilk test. Normally distributed data were reported using means and standard deviations and compared using the Student's t-test. Categorical variables were summarized as frequency distributions and percentages and compared with Fisher's exact test or the Chi-square test. Fisher's exact test was used when more than 20% of the cells in the table had fewer than five expected values; otherwise, the Chi-square test was used. Receiver operating characteristic (ROC) analysis was performed to evaluate the optimal cut-off values of the distal ureteral lateralization angle for UAS success. When the area under the curve was found to be significant, cut-off points were determined for the relevant variables according to the Youden index and summarized with the corresponding selectivity-sensitivity points. In our study, the type I error rate was accepted as 0.005, and IBM SPSS Statistics for Windows, Version 22.0 (IBM Corp., Armonk, NY, USA) was used for all analyses.

## RESULTS

A total of 48 patients were included in the study. The mean age of the patients was  $51 \pm 5.71$  years, and 34 (70.8%) were males while 14 (29.2%) were females. Regarding stone localization, 32 (66.7%) patients had single or multiple kidney stones, while 16 (33.3%) patients had proximal ureteral stones. The mean stone burden was  $1067.46 \pm 1205.01$  mm<sup>3</sup>, while the mean distal ureter lateralization angle was  $52.93 \pm 15.67^\circ$ . The complete demographic data are shown in Table 1.

**Table 1.** Main characteristics of included patients

Age (years) (mean $\pm$ SD)	51 $\pm$ 5.71
Sex	
Female (n,%)	14 (29.2%)
Male (n,%)	34 (70.8%)
Side	
Right (n,%)	22 (45.8%)
Left (n,%)	26 (54.2%)
Stone Localization*	
Kidney (n,%)	32 (66.7%)
Upper Calyx (n,%)	-
Mid Calyx (n,%)	6 (12.5%)
Lower Calyx (n,%)	8 (16.6%)
Pelvis (n,%)	18 (37.5%)
Proximal Ureter (n,%)	16 (33.3%)
Number of Stones	
Single (n,%)	32 (66.7%)
Multiple (n,%)	16 (33.3%)
Stone Size (mm <sup>3</sup> ) (mean $\pm$ SD)	1067.46 $\pm$ 1205.01
Distal Ureteral Lateralization Angle (degrees) (mean $\pm$ SD)	52.93 $\pm$ 15.67

\*For patients with multiple stones, the largest stone's localization was recorded.

When the patients were divided into two groups—those with successful UAS placement and those without—no significant differences were found between the groups in terms of sex, laterality, localization, the number of stones, stone burden, and bladder volumes evaluated with preoperative computed tomography ( $p > 0.05$ ). However, significant differences were found between the two groups in terms of age and distal ureteral lateralization angle ( $p < 0.001$  and  $p = 0.013$ , respectively) (Table 2).

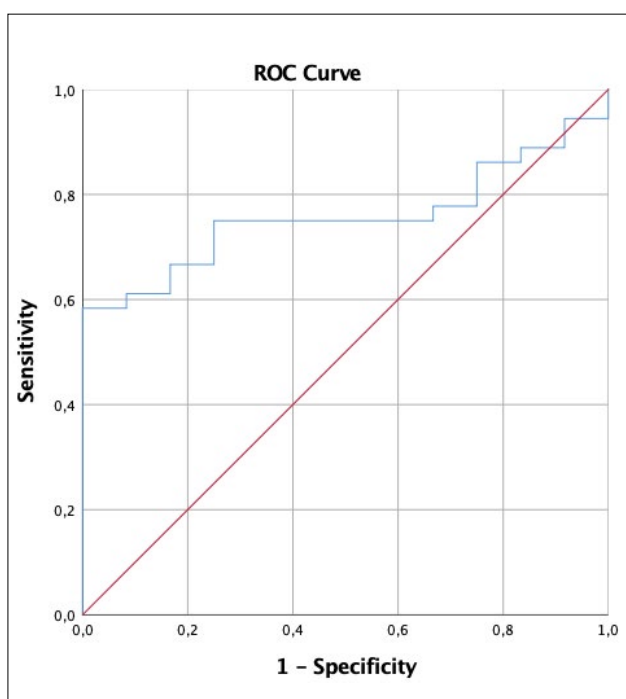
For the secondary outcomes of the study, receiver operating characteristic curves were analyzed to evaluate the optimal cut-off values of the distal ureteral lateralization angle for UAS success. The distal ureteral lateralization angle had a higher predictive value in ROC (area under the curve [AUC]=0.757, 95% confidence interval 0.625 to 0.889,  $p = 0.008$ ) (Fig. 2).

## DISCUSSION

Ureteral access sheaths, which are commonly used during surgery, may still impact the success of surgeries due to their failure in placement and their potential to cause ureteral trauma. It can be predicted that patients' misconception that a single procedure will be sufficient for treatment may negatively affect patient compliance and satisfaction in the event of possible failure. Hence, as well as informing the patient, assessing the factors that may affect success beforehand is also

**Table 2.** Comparison of parameters between cases with successful and failed ureteral access sheath (UAS) insertions

	UAS Successful Group (n=36)	Failure Group (n=12)	p value
Age (years)	52.78±5.25	45.67±3.22	<0.001
Sex (Female/Male)	10/26	4/8	0.726
Side (Right/Left)	16/20	6/6	0.738
Localization (Kidney/Proximal Ureter)	26/10	6/6	0.178
Number of Stones (Single/Multiple)	22/14	10/2	0.289
Stone Size (mm <sup>3</sup> )	1262.54±1334.9	482.22±190.36	0.051
Bladder Volume (mL)*	351.8±168.17	327.18±155.14	0.755
Distal Ureteral Lateralization Angle (degrees)	56.11±15.64	43.41±11.8	0.013

**Figure 2.** Receiver operating characteristic (ROC) curves illustrating the correlation between the distal ureteral lateralization angle and UAS success.

of great importance for surgeons.

Ureteral strictures, narrow ureteral orifices, anatomical variations, and the large-diameter instruments used may prevent UAS from being placed. However, despite the evaluation of the ureter under vision before UAS placement and the exclusion of pathological conditions, failures can still occur. The lateralization of the distal ureter and ureteral tone might be significant factors in this situation.

The urethra and ureteral lumens do not align in a straight line, and the ureteral access sheath does not follow a direct path. Cho et al., in their study with 11-13 French (Fr) UAS, revealed that the distal ureteral sidewall might be the first point

of resistance in the transition of the UAS to the proximal area after its passage through the bladder neck and ureter orifice, and that the angulation here impacts success.<sup>[7]</sup> In their angle calculations, they used the spatial coordinate system, which is more complex. Similarly, we obtained similar results in our study using the 10.7 Fr UAS. On the other hand, we evaluated our angle calculations in a planar way that can be calculated more easily. We associated the effective factor with the relevant angulation by excluding patients with a history of ureteroscopy, ureteral stent placement, extracorporeal shock wave lithotripsy, and spontaneous stone removal; patients younger than 18 years of age; pregnant women; and male patients with the presence of a prostatic median lobe, which may affect success.

Detailed knowledge of the biomechanical properties of the ureteral wall and their variation with axial position is critical for interventional procedures or surgery, as well as for ureteral canal function. As the ureter is a curved tube, a curved model may experience more wall stress than a straight model.<sup>[12]</sup> With age, the ureter undergoes significant geometric remodeling. In particular, the length of the ureter has been shown to increase gradually between the ages of 20 and 80.<sup>[12]</sup> This leads to an increase in the angle of the ureter with age.

Another reason for failure that we could not analyze in our study may be increased ureteral tone. The use of pharmacological methods to decrease the tone of the muscle tissue of the ureter could be helpful in the placement of a UAS and in eliminating related complications. Lildal et al., in their study on swine models, demonstrated that isoproterenol, a  $\beta$ -agonist, when applied topically in irrigation fluid, can inhibit ureteral muscle tone without causing systemic adverse effects, reduce pressure in the upper urinary system, and result in significantly higher successful UAS placement compared to the saline group.<sup>[13]</sup> Koo et al., on the other hand, revealed that preoperative use of tamsulosin resulted in a significant decrease in the force applied during UAS insertion, even at a similar level to patients who underwent pretesting.<sup>[14]</sup>

Preoperative stenting is considered to cause passive dilation of the ureter. Additionally, a dilated ureter would increase the odds of successful UAS placement. Numerous studies in the literature have demonstrated that preoperative stenting increases the success of UAS placement.<sup>[1,15-18]</sup> Yet, in the guidelines, it is still not required to be performed routinely.

In our study, we also found a correlation between UAS placement success and age, whereas we did not find a correlation between UAS placement success and sex. There are differing results on this issue in the literature. In their prospective study assessing the effective factors in UAS placement, Mogilevkin et al. reported that age, previous endoscopic surgeries, and pre-stenting were positive predictors of success.<sup>[17]</sup> On the other hand, Alkhomees et al., in their study on ureters that had not undergone any intervention before, concluded that age, sex, body mass index, laterality, history of spontaneous stone removal, and anesthesia type (general or spinal) did not impact the success of UAS placement.<sup>[19]</sup> It is considered that progressive enlargement of the ureter and loss of surrounding muscle mass with aging is culpable for this condition.<sup>[14]</sup> We also hypothesized that the sex factor might be effective due to the shorter and more flexible urethra in females and the presence of a prostate in males. However, in the results we reached, we could not find the effect of sex on successful UAS insertion. The presence of some young population and exclusion of patients with a prostatic median lobe may be a factor in benign prostatic hyperplasia that may occur in male patients.

Our study has some limitations. First, the number of patients included in the study was limited since our study was conducted at a private foundation university. It is controversial how well this sample size can represent the real population. As a second limitation, it could not be assessed whether the distal ureteral lateralization angle was exactly the same as the point where the UAS could not be advanced, and this was not confirmed by measuring the distance of this angle to the ureterovesical junction. However, the point where the ureteral access sheath could not be advanced was correlated with the portion of the distal ureter lateralized on fluoroscopy. Lastly, this retrospective study might show different results from prospective studies. Nevertheless, it should be noted that the limitations highlighted in the study's design and analysis, particularly the small sample size and the absence of confounding adjustment, are crucial considerations for the interpretation and generalization of the findings.

## CONCLUSION

In conclusion, the distal ureteral lateralization angle is considered to be an effective factor in the placement of UAS in patients scheduled for fURS. Preoperative assessment of this angulation will be a crucial issue for surgeons in terms of preoperative preparation and for patients in terms of being informed.

**Ethics Committee Approval:** This study was approved by the Ufuk University Ethics Committee (Date: 07.11.2021, Decision No: 12024861-75).

**Peer-review:** Externally peer-reviewed.

**Authorship Contributions:** Concept: M.Y.; Design: M.Y.; Supervision: H.Ç.E.; Resource: M.Y.; Materials: M.Y.; Data collection and/or processing: H.Ç.E.; Analysis and/or interpretation: H.Ç.E.; Literature search: M.Y.; Writing: M.Y.; Critical review: M.Y.

**Conflict of Interest:** None declared.

**Financial Disclosure:** The author declared that this study has received no financial support.

## REFERENCES

- Breda A, Territo A, López-Martínez JM. Benefits and risks of ureteral access sheaths for retrograde renal access. *Curr Opin Urol* 2016;26:70–5.
- Patel N, Monga M. Ureteral access sheaths: a comprehensive comparison of physical and mechanical properties. *Int Braz J Urol* 2018;44:524–35.
- Kawahara T, Ito H, Terao H, Ishigaki H, Ogawa T, Uemura H, et al. Preoperative stenting for ureteroscopic lithotripsy for a large renal stone. *Int J Urol* 2012;19:881–5. [\[CrossRef\]](#)
- Zhang J, Xu C, He D, Lu Y, Hu H, Qin B, et al. Flexible ureteroscopy for renal stone without preoperative ureteral stenting shows good prognosis. *PeerJ* 2016;4:e2728. [\[CrossRef\]](#)
- Netsch C, Knipper S, Bach T, Herrmann TR, Gross AJ. Impact of preoperative ureteral stenting on stone-free rates of ureteroscopy for nephroureterolithiasis: a matched-paired analysis of 286 patients. *Urology* 2012;80:1214–9. [\[CrossRef\]](#)
- Assimos D, Crisci A, Culkin D, Xue W, Roelofs A, Duvdevani M, et al; CROES URS Global Study Group. Preoperative JJ stent placement in ureteric and renal stone treatment: results from the Clinical Research Office of Endourological Society (CROES) ureteroscopy (URS) Global Study. *BJU Int* 2016;117:648–54. [\[CrossRef\]](#)
- Cho SY, Ryang SH, Lee DS. A presumptive role of lower ureteral angles in the difficulty of ureteral access sheath insertion during retrograde intrarenal surgery. *Int Urol Nephrol* 2020;52:1657–63. [\[CrossRef\]](#)
- Ordon M, Andonian S, Blew B, Schuler T, Chew B, Pace KT. CUA Guideline: Management of ureteral calculi. *Can Urol Assoc J* 2015;9:E837–51.
- Bourdoumis A, Tanabalán C, Goyal A, Kachrilas S, Buchholz N, Masood J. The difficult ureter: stent and come back or balloon dilate and proceed with ureteroscopy? What does the evidence say?. *Urology* 2014;83:1–3.
- Bih LL, Ho CC, Tsai SJ, Lai YC, Chow W. Bladder shape impact on the accuracy of ultrasonic estimation of bladder volume. *Arch Phys Med Rehabil* 1998;79:1553–6. [\[CrossRef\]](#)
- Park J, Kang M, Jeong CW, Oh S, Lee JW, Lee SB, et al. External validation and evaluation of reliability and validity of the modified seoul national university renal stone complexity scoring system to predict stone-free status after retrograde intrarenal surgery. *J Endourol* 2015;29:888–93.
- Petsepe DC, Kourkoulis SK, Papadodima SA, Sokolis DP. Regional and age-dependent residual strains, curvature, and dimensions of the human ureter. *Proc Inst Mech Eng H* 2018;232:149–62. [\[CrossRef\]](#)
- Lildal SK, Andreassen KH, Christiansen FE, Jung H, Pedersen MR, Osther PJ. Pharmacological relaxation of the ureter when using ureteral access sheaths during ureterorenoscopy: A randomized feasibility study in a porcine model. *Adv Urol* 2016;2016:8064648. [\[CrossRef\]](#)
- Koo KC, Yoon JH, Park NC, Lee HS, Ahn HK, Lee KS, et al. The impact of preoperative  $\alpha$ -adrenergic antagonists on ureteral access sheath insertion force and the upper limit of force required to avoid ureteral mucosal injury: a randomized controlled study. *J Urol* 2018;199:1622–30.
- Yuk HD, Park J, Cho SY, Sung LH, Jeong CW. The effect of preoperative

- ureteral stenting in retrograde Intrarenal surgery: a multicenter, propensity score-matched study. *BMC Urol* 2020;20:147. [CrossRef]
16. Sung LH, Cho DY. The role of preoperative ureteral stenting in retrograde intrarenal surgery in renal stone patients: a propensity score-matched study. *Transl Androl Urol* 2020;9:276–83. [CrossRef]
17. Mogilevkin Y, Sofer M, Margel D, Greenstein A, Lifshitz D. Predicting an effective ureteral access sheath insertion: a bicenter prospective study. *J Endourol* 2014;28:1414–7. [CrossRef]
18. Shields JM, Tunuguntla HS, Bhalani VK, Ayyathurai R, Bird VG. Construction-related differences seen in ureteral access sheaths: comparison of reinforced versus nonreinforced ureteral access sheaths. *Urology* 2009;73:241–4. [CrossRef]
19. Alkhamees M, Aljuhayman A, Addar A, Ghazwani Y, Alasker A, Hamri SB. Failure of ureteral access sheath insertion in virgin ureters: A retrospective tertiary care center study. *Urol Ann* 2020;12:331–4. [CrossRef]

## ORİJİNAL ÇALIŞMA - ÖZ

### Distal üreteral lateralizasyon açısının üreteral travmadan kaçınma ve başarılı üreteral erişim kılıfı yerleştirme üzerine etkisi

Metin Yığman,<sup>1</sup> Hale Çolakoğlu Er<sup>2</sup>

<sup>1</sup>Ankara Etlik Şehir Hastanesi, Üroloji Kliniği, Ankara, Türkiye

<sup>2</sup>Ankara Güven Hastanesi, Radyoloji Kliniği, Ankara, Türkiye

**AMAÇ:** Fleksibl üreteroskopik litotripside (fURL) avantajları olan üreteral erişim kılıflarının (ÜEK) kullanımında üreteral yaralanma, iskemi ve uzun süreli üreteral stenoz gibi istenmeyen durumlar ortaya çıkabilir. Çalışmanın amacı distal üreteral lateralizasyon açısının başarılı ÜEK yerleştirilmesi üzerindeki etkisini araştırmaktır.

**GEREÇ VE YÖNTEM:** Böbrek ve/veya proksimal üreter taşları için fURL prosedürü uygulanan hastaların verileri retrospektif olarak analiz edildi. Hastaların preoperatif bilgisayarlı tomografik incelemelerine dayanarak mesane çıkışı sıfır noktası olarak kabul edildi ve buradan geçen yatay eksen ile distal üreterin en lateralize noktası arasındaki açı değerleri hesaplandı. Hastalar ÜEK'nin başarılı bir şekilde yerleştirildiği ve yerleştirilemediği hastalar olarak 2 gruba ayrıldı.

**BULGULAR:** Başarılı ÜEK yerleştirilen (n=36) ve yerleştirilemeyen (n=12) gruplar arasında cinsiyet, lateralite, lokalizasyon, taş sayısı, taş yükü ve ameliyat öncesi bilgisayarlı tomografi ile değerlendirilen mesane hacimleri açısından anlamlı bir fark saptanmadı (p>0.05). Öte yandan, yaş ve distal üreteral lateralizasyon açısı açısından iki grup arasında anlamlı fark bulundu (p<0.001, p=0.013).

**SONUÇ:** Distal üreteral lateralizasyon açısının fURS planlanan hastalarda ÜEK yerleştirilmesinde etkili bir faktör olduğu düşünülmektedir.

**Anahtar sözcükler:** Üreteroskopi; üreterorenoskopi; üreteral erişim kılıfı; üreteral kurvatür; üreteral açısı.

*Ulus Travma Acil Cerrahi Derg* 2024;30(9):671-676 DOI: 10.14744/tjtes.2024.67996