

A rare cause of intestinal obstruction: right paraduodenal hernia

 Tuba Atak

Department of Surgery, Bursa Cekirge State Hospital, Bursa-Türkiye

ABSTRACT

Internal herniation is an extremely rare cause of intestinal obstruction. Paraduodenal hernias result from abnormal rotation of the bowel. Symptoms that may range from recurrent abdominal pain to acute obstruction may occur. If it is not diagnosed and treated in time, the disease may result in intestinal ischemia. This article aimed to present the diagnosis and treatment process of a 47-year-old male presenting with acute abdomen symptoms by evaluating retrospectively with the accompaniment of literature. During the abdominal exploration of the patient, nearly all of the intestines were observed to be herniated from the right paraduodenal region to the posterior area. The opening of the hernial sac was repaired primarily by reducing the intestinal bowel loops into the intraperitoneal region. The patient undergoing anastomosis by performing resection of the ischemic part after reduction of herniated bowel loops was discharged uneventfully on the post-operative 10th day. Paraduodenal hernia is a condition that should be considered in patients with abdominal pain and intestinal obstruction symptoms. Early diagnosis is of vital importance to prevent the complications which can develop.

Keywords: Bowel obstruction; paraduodenal hernia; strangulation.

INTRODUCTION

An internal herniation is defined as herniation of the small intestine loops through a mesenteric defect within the abdominal cavity.^[1] Internal hernia is a rare cause of acute abdomen and may lead to intestinal obstruction and ischemia if it is not diagnosed and treated in time.^[2,3] The right PDH is less frequently seen. It is observed in males three times more commonly than in females, and it is most commonly seen in the fourth and sixth decades of life.^[1,2] During a lifetime, approximately half of the patients carry a risk of intestinal obstruction or strangulation.^[2] This article aims to present a 47-year-old male undergoing surgery due to a right paraduodenal hernia.

CASE REPORT

A 47-year-old male patient who presented in the emergency department with complaints of abdominal pain and vomit-

ing was hospitalized at the clinic with a preliminary diagnosis of bowel obstruction. During the presentation, the patient's blood pressure, pulse rate, and temperature were measured to be 135/80 mmHg, 94/min, and 38.7°C, respectively. At the physical examination, there was widespread defense and rebound in all abdominal quadrants. Decompression through a nasogastric tube and intravenous fluid replacement were planned. The leukocyte count was 10930/mm³, the blood glucose level was 474 mg/dL, and other biochemical values were within normal limits. Clustered bowel loops were observed in the right upper quadrant of the computed tomography (Fig. 1). A laparotomy was performed on the patient due to an acute abdomen. On exploration at laparotomy, all of the small bowel loops except some parts of the terminal ileum were observed to have herniated posteriorly through an opening in the right paraduodenal region, and the mesentery was partially twisted (Fig. 2). Most of the small bowel loops were observed to be ischemic (Fig. 3). The small bow-

Cite this article as: Atak T. A rare cause of intestinal obstruction: right paraduodenal hernia. *Ulus Travma Acil Cerrahi Derg* 2024;30:226-228.

Address for correspondence: Tuba Atak

Department of Surgery, Bursa Cekirge State Hospital, Bursa, Türkiye

E-mail: drtuba81@yahoo.com

Ulus Travma Acil Cerrahi Derg 2024;30(3):226-228 DOI: 10.14744/tjtes.2023.20352

Submitted: 14.08.2023 Revised: 15.08.2023 Accepted: 23.11.2023 Published: 13.03.2024

OPEN ACCESS This is an open access article under the CC BY-NC license (<http://creativecommons.org/licenses/by-nc/4.0/>).



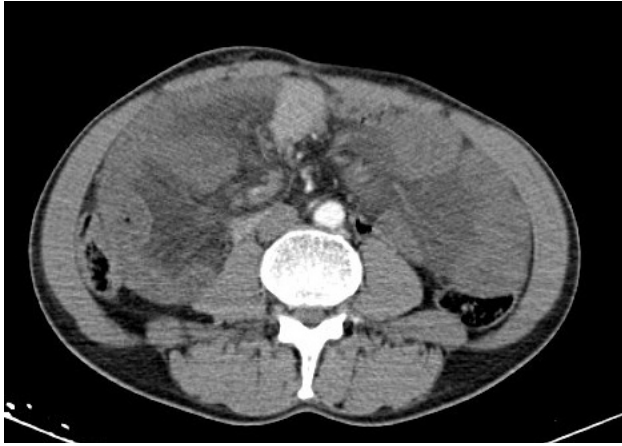


Figure 1. The appearance on the computerized tomography scan.

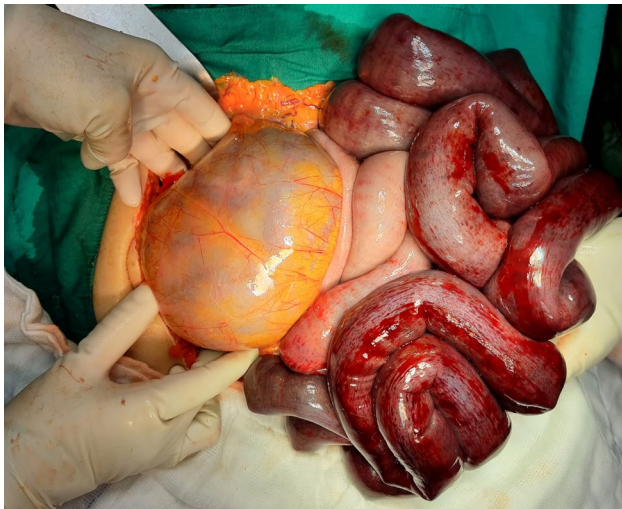

Figure 2. Most of the small bowel loops encapsulated within the hernia sac.

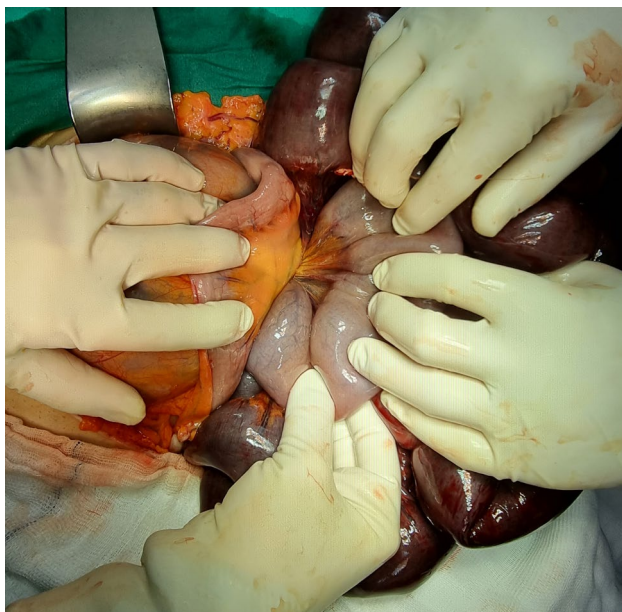

Figure 3. Necrotic small bowel loops.

el loops were reduced by manual traction. Necrotic, small bowel loops were resected. An end-to-end anastomosis was performed between the proximal portion of the jejunum approximately 100 cm distal to the ligament of Treitz, and the distal portion of the ileum approximately 40 cm distal to the terminal ileum. The defect was primarily repaired, and the operation was terminated. The post-operative period of the patient was uneventful, and he was discharged on the post-operative 10th day. It was considered to be extensive ischemic necrosis during the histopathological investigation. He had no complaints during the 8th-month post-operative follow-up, and his physical examination was evaluated to be within normal limits.

Written informed consent was obtained from the patient for the publication of the case report and the accompanying images.

DISCUSSION

Paraduodenal hernias are among the rare causes of intestinal obstruction. One percent of all small bowel obstructions result from internal herniation.^[1,3] Paraduodenal hernias account for 53% of all patients with intestinal obstruction.^[3] They may be acquired associated with intestinal resection or congenital due to embryonic malrotation of the midgut or an incomplete union of mesoepithelium during organogenesis. Since our patient had no history of abdominal surgery, the patient was considered to have a congenital right paraduodenal hernia.

Twenty-five percent of paraduodenal hernias are seen on the right side. When the literature knowledge was investigated, <50 cases of right paraduodenal hernia were reported until today. Furthermore, in our study, bowel herniation through Waldeyer's fossa on the right side (which is rarely seen) was detected.

It can be seen three times more commonly in males than in females.^[1] Although it can be seen at each age, it is most commonly seen in the fourth and sixth decades of life.^[1-5] Furthermore, our patient was male and in the fourth decade of life.

While the clinical course of the disease is asymptomatic in half of patients, the remaining half may have symptoms such as abdominal pain, nausea, vomiting, distension, inability to pass flatus, and stool developing due to ileus resulting from recurrent cramp-like abdominal pains or torsion. The severity of symptoms in patients is defined by the degree of obstruction. The symptoms were severe in our patients due to ischemia.

Imaging methods play an essential role in the diagnosis. With its higher rate of accuracy, abdominal computed tomography is the most critical non-invasive radiological imaging method that will accelerate the treatment process with its role in identifying the diagnosis, severity, and etiology of the disease.

At computed tomography, small bowel loops in the left paraduodenal hernia can be determined as clustering with abnormal localization behind the stomach and at the left side of the fourth portion of the duodenum or in the vicinity of the pancreas tail. In the right paraduodenal hernia, the clustering of dilated small bowel segments as if in a sac is a characteristic finding.

The treatment is surgical. Open surgery is commonly preferred, but a laparoscopic approach has also been performed in recent years.^[6-8] The basic principle of treatment is a surgical procedure based on the reduction of herniated bowel loops and the primary repair of the defect.^[7] The surgery that will be performed may differ according to delays in diagnosis. If there is no ischemia finding and the reduction of incarcerated small bowel loops is necessary, resection of the hernia sac and repair of the defect are recommended. A delay in diagnosis may cause an acute clinical picture that can result in incarceration and intestinal necrosis. In cases of the development of ischemia and necrosis in small bowel walls, resection of bowel loops may be necessary. The mortality rate in cases developing necrosis is higher than 50%.^[8-10] Furthermore, in our patient, necrosis was determined in the majority of small bowels, but mortality did not develop.

CONCLUSION

When a mechanical bowel obstruction is detected, internal herniation should be considered in patients without previous abdominal surgery. Considering the delay in diagnosis and treatment will considerably increase morbidity and mortality, early surgical treatment should be performed as fast as

possible.

Peer-review: Externally peer-reviewed.

Conflict of Interest: None declared.

Financial Disclosure: The author declared that this study has received no financial support.

REFERENCES

- Öztaş M, Can MF, Öztürk E, Yağcı G. Üst seviyeli intestinal obstrüksiyona neden olan nadir bir internal herniasyon olgusu: Sol paraduodenal fitik. *Ulusal Cer Derg* 2013;2013;92-5.
- Şen M, İnan A, Dener C, Bozer M. Paraduodenal internal hernia: Clinical analysis based on two cases. *Ulus Travma Acil Cerrahi Derg* 2007;13:232-6.
- Manfredelli S, Andrea Z, Stefano P, Giovanni L, Maria M, Angelo F, et al. Rare small bowel obstruction: Right paraduodenal hernia. Case report. *Int J Surg Case Rep* 2013;4:412-5. [CrossRef]
- Mehra R, Pujahari AK. Right paraduodenal hernia: Report of two cases and review of literature. *Gastroenterol Rep (Oxf)* 2016;4:168-71.
- Şen M, İnan A, Dener C, Bozer M. Paraduodenal internal herniler: İki olgu nedeniyle klinik analiz. *Ulus Travma Acil Cerrahi Derg* 2007;13:232-6.
- Parmar BP, Parmar RS. Laparoscopic management of left paraduodenal hernia. *J Min Access Surg* 2010;6:122-4. [CrossRef]
- Tong RS, Sengupta S, Tjandra JJ. Left paraduodenal hernia. Case report and review of literature. *ANZ J Surg* 2002;72:69-71. [CrossRef]
- Al-khyatt W, Aggarwal S, Birchall J, Rowlands TE. Acute intestinal obstruction secondary to left paraduodenal hernia: A case report and literature review. *World J Emerg Surg* 2013;8:5. [CrossRef]
- Zonca P, Maly T, Mole DJ, Stigler J. Treitz's hernia. *Hernia* 2008;12:531-4. [CrossRef]
- Manji R, Warnock GL. Left paraduodenal hernia: An unusual cause of small bowel obstruction. *Can J Surg* 2001;46:455-6.

OLGU SUNUMU - ÖZ

Nadir bir intestinal obstrüksiyon sebebi: sağ paraduodenal herni

Tuba Atak

Bursa Çekirge Devlet Hastanesi, Genel Cerrahi Kliniği, Bursa, Türkiye

İnternal herniasyon son derece nadir görülen bir intestinal obstrüksiyon sebebidir. Paraduodenal herniler, barsağın anormal rotasyonu sonucunda oluşmaktadır. Tekrarlayıcı karın ağrılarında akut barsak tıkanıklıklarına kadar değişebilen semptomlar oluşturmaktadır. Zamanında tanı konulup tedavi edilmezse barsakta iskemi ile sonuçlanabilmektedir. Bu yazıda, akut karın bulgularıyla gelen 47 yaşında erkek hastanın tanı ve tedavi süreci retrospektif olarak değerlendirilerek literatür eşliğinde sunulması amaçlanmıştır. Karın eksplorasyonunda ince barsakların tamamına yakın kısmının sağ paraduodenal bölgeden posteriora doğru herniye olduğu görüldü. İnce barsak ansları intraperitoneal alana redükte edilerek herni kesesinin girişi primer olarak tamir edildi. Redüksiyon sonrası iskemik kısım rezeke edilerek anastomoz yapılan hasta onuncu günde sorunsuz taburcu edildi. Paraduodenal herni, karın ağrısı ve intestinal obstrüksiyon bulguları olan hastalarda akılda tutulması gereken bir durumdur. Gelişebilecek komplikasyonları önleyebilmek için erken tanı hayati öneme sahiptir.

Anahtar sözcükler: Barsak obstrüksiyonu; paraduodenal herni; strangülyasyon.

Ulus Travma Acil Cerrahi Derg 2024;30(3):226-228 DOI: 10.14744/tjtes.2023.20352