

# Is TAPP the Right alternative for patients undergoing emergency surgery for incarcerated inguinal hernia?

Levent Eminođlu

Department of General Surgery, Ataşehir Florence Nightingale Hospital, İstanbul-Türkiye

## ABSTRACT

**BACKGROUND:** Incarcerated inguinal hernia requires emergency intervention. The incarcerated segment should be thoroughly inspected in order to evaluate the degree of ischemia and decide whether resection is required. The aim of this study is to evaluate the applicability of TAPP for patients seen in the emergency department for incarcerated inguinal hernias.

**METHODS:** The study was done retrospectively. Patients who presented to the emergency department and were operated with the TAPP technique were included. In all patients laparoscopic abdominal exploration was done to determine the extent of the incarcerated intestinal segment and evaluate the need for resection. TAPP technique was used to laparoscopically repair the hernia. The demographics of the patients, technique used for the hernia repair, necessity for resection, postoperative mortality and morbidity and recurrence rates were recorded.

**RESULTS:** 109 patients were seen for incarcerated hernia. 12 patients were excluded either because they were not suitable for or did not consent to laparoscopic repair. 97 patients had hernia repair with TAPP technique. In 6 patients spontaneous reduction of the incarcerated segment was observed after anesthesia induction. In 9 patients necrosis of the incarcerated segment was observed and resection and anastomosis was performed. 7 patients had laparoscopic 2 patients had open resections. Seroma was observed in 7, hematoma in 3 and wound infection in 2 patients postoperatively. No mortality was seen. 1 patient had a recurrence in the follow up period.

**CONCLUSION:** TAPP technique is a good alternative for selected patients undergoing emergency hernia repair because it provides the surgeon with the possibility to evaluate the incarcerated intestinal segment thoroughly while preserving the advantages of laparoscopic surgery.

**Keywords:** Emergency surgery; incarcerated hernia; TAPP.

## INTRODUCTION

Inguinal hernia repair is the second most frequently performed operation in general surgery. Annually, more than 20 million patients undergo surgery for inguinal hernias. Numerous techniques have been described, but eventually, mesh repair has become the most popular technique for open hernia repair.<sup>[1-3]</sup>

Laparoscopic surgery, introduced in the early 1980s, has gained popularity with increasing experience and technological progress, achieving similar success rates to open surgery.

In addition to these comparable success rates, laparoscopic operations offer the advantage of minimal trauma to the patients, thus enhancing the technique's popularity.<sup>[4]</sup>

Transabdominal preperitoneal (TAPP) and totally extraperitoneal (TEP) techniques are currently performed for laparoscopic hernia repairs. While both are highly popular for elective operations compared to open surgery, open surgery remains the treatment of choice for emergency surgeries.<sup>[5]</sup>

Our study aimed to investigate whether the laparoscopic TAPP technique is a viable treatment alternative for patients

Cite this article as: Eminođlu L. Is TAPP the right alternative for patients undergoing emergency surgery for incarcerated inguinal hernia? *Ulus Travma Acil Cerrahi Derg* 2024;30:97-100.

Address for correspondence: Levent Eminođlu

Department of General Surgery, Ataşehir Florence Nightingale Hospital, İstanbul, Türkiye

E-mail: eminlvnt@gmail.com

*Ulus Travma Acil Cerrahi Derg* 2024;30(2):97-100 DOI: 10.14744/tjtes.2024.63367

Submitted: 11.10.2023 Revised: 05.01.2024 Accepted: 12.01.2024 Published: 02.02.2024

OPEN ACCESS This is an open access article under the CC BY-NC license (<http://creativecommons.org/licenses/by-nc/4.0/>).



requiring emergency surgery for incarcerated or strangulated inguinal hernias.

## MATERIALS AND METHODS

Our study was conducted retrospectively. Patients who presented to our emergency department between January 2015 and June 2023 and required emergency hernia repair were included. All patients underwent a physical examination. If the hernia contents were manually irreducible, we defined them as incarcerated; if blood supply was compromised or obstructed, we defined them as strangulated. Strangulation was confirmed only after visual observation, either laparoscopically or in open surgery. When incarcerated hernia was suspected, ultrasonography was performed to confirm the diagnosis. Once the diagnosis was established, surgery was offered. Both open and laparoscopic alternatives were explained, and written information was provided. After obtaining written consent, all patients who opted for laparoscopy were included.

The TAPP technique was used for the laparoscopic approach. A 12 mm trocar was introduced through an infraumbilical incision, and pneumoperitoneum was established. Abdominal exploration was performed, and the incarcerated segment was evaluated. Depending on the site of the hernia, two additional 5 mm trocars were added. The incarcerated segment was reduced and evaluated for viability. When blunt maneuvers to free the incarcerated segment were unsuccessful, the internal ring was cut to facilitate reduction. After the segment was freed, we waited for ten minutes to observe if a demarcation line developed or if circulation was restored. We did not use indocyanine green (ICG) injection or other tissue perfusion control modalities, as we did not have the technical availability. If viability was uncertain, laparoscopic resection and primary anastomosis of the affected segment were performed, with the addition of a 12 mm port. The resected segment was sent for pathological examination.

The hernia was repaired with a 6 x 11 cm polypropylene mesh (Fig. 3). The peritoneum overlying the hernia was opened, the mesh was introduced to completely cover the myopectineal orifice, and secured with tackers. Then, the peritoneum was closed to prevent exposure of the mesh. Patients who required resection and anastomosis were further evaluated for additional morbidities related to the procedure.

Patient demographics, the operation performed, the requirement for resection, postoperative morbidity and mortality, and recurrence information were recorded. This study was approved by the ethics committee of SBU Kanuni Sultan Süleyman Teaching and Research Hospital.

## RESULTS

Between these dates, 121 patients with inguinal hernia presented to the emergency department. Physical examination and ultrasonographic exam revealed incarceration in 109 of

these patients, and strangulation was suspected in 54 patients.

Emergency surgery was offered to 109 patients. Risks and possible complications were explained. Two patients refused surgery. Six patients opted for open surgery. In four patients, the risk of general anesthesia was deemed too high at the anesthesia consultation, and these patients underwent open surgery under spinal anesthesia. Ninety-seven patients accepted laparoscopic surgery, of which 92 had inguinal hernias and five had femoral hernias. Among those with inguinal hernia, 81 were male and 11 were female. All five patients with femoral hernia were female, with a mean age of 43.

Of the five female patients operated on for femoral hernia, three had ischemia with a clear demarcation in the incarcerated intestinal segment. Laparoscopic resection and anastomosis

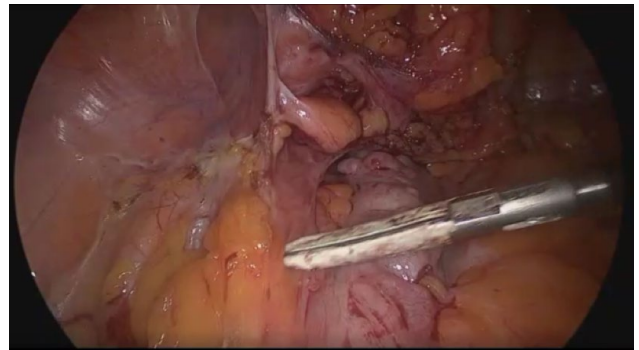

Figure 1. Laparoscopic resection of strangulated segment.

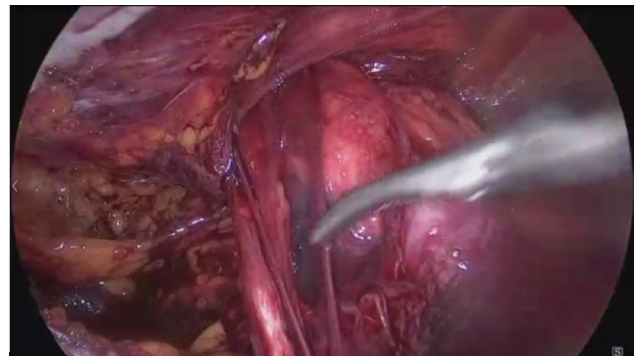


Figure 2. Reduction of hernia sac contents.

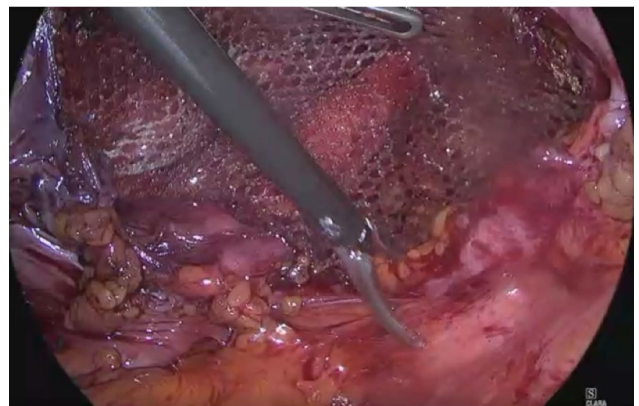

Figure 3. Hernia repair with mesh.

sis were performed in two of these patients. In one patient, the operation was converted to open surgery, and resection and anastomosis were performed in an open fashion.

In the 92 patients who were operated on for inguinal hernia, 22 had ischemic changes in the incarcerated intestinal segment. With the introduction of anesthesia, blood supply was restored in 16 patients, whereas in six patients, ischemia persisted. For these patients, resection and anastomosis were performed; five patients had a laparoscopic and one patient had an open approach.

The mean overall hospital stay was 1.5 days, and for patients with resection and anastomosis, the mean hospital stay was 3.4 days.

In patients operated on for inguinal hernia, seven had a seroma and three had a hematoma at the hernia site. In the nine patients who had resection and anastomosis, two had a wound infection. None of the patients required additional treatment. No mortality was observed.

## DISCUSSION

The term 'acute incarcerated abdominal hernia' is used for emergency cases in which local pain and swelling accompany a hernia sac whose contents may present with ischemia and intestinal obstruction.<sup>[6]</sup> Incarceration and strangulation significantly affect morbidity and mortality. Such cases present with a significant increase in therapeutic risk, which is typically low in hernia repair. Since physical examination and ultrasound (US) are not definitive in determining strangulation, the importance of surgical intervention is unquestionable. Evaluating the blood supply of the incarcerated segment in the acute phase can prevent the successive onset of ischemia and perforation. Laparoscopic exploration is more advantageous than open surgery in evaluating intestinal segments that have been spontaneously reduced following the introduction of anesthesia.<sup>[7]</sup>

Laparoscopic hernia repair has become routine in elective surgery, but open surgery continues to be more prominent in emergency cases.<sup>[8,9]</sup> This may be due to the difficulty in assessing the vascularization of the strangulated segment and performing resections if necessary. The longer preparation time required for laparoscopy in emergency cases and the feasibility of spinal anesthesia in patients with high anesthesia risk are the advantages of open surgery.

Our study, however, shows that in a center where laparoscopy is routinely utilized in everyday practice, laparoscopy can also be performed in emergency cases. Additionally, laparoscopic exploration provides the opportunity to evaluate segments that have reduced after the induction of anesthesia.

Watson et al. reported the first successful treatment of an incarcerated hernia with intestinal resection performed laparoscopically in 1993.<sup>[10]</sup> In 1996, Ishihara et al. reported a series of TAPP hernia repairs of incarcerated hernias and

assessment of the involved intestinal segment, with an average operative time of 88 minutes and only one complication requiring a laparotomy.<sup>[11]</sup> Subsequently, Leibl et al. reported on a series of 194 patients, some with chronic incarceration and some acute, undergoing TAPP repairs; the operative time averaged 55 minutes, with seven recurrences.<sup>[12]</sup> In another series, Rebuffat et al. reported on 28 patients with an average operating time of 72 minutes, three conversions to open surgery, one complication of an inguinal hematoma, and nine laparoscopically performed bowel resections in 2006.<sup>[13]</sup>

Zanoni et al. reported the safety and effectiveness of the laparoscopic transperitoneal hernia repair (TAPP) approach in the emergency setting with four years of follow-up, noting no recurrences or severe complications over four years.<sup>[14]</sup>

Jacob et al.<sup>[15]</sup> compared 89 patients with incarcerated and strangulated hernias operated on by laparoscopy to those undergoing open repair. This study showed that laparoscopic emergent repair of incarcerated hernias is a safe and feasible approach, with better short- and long-term results compared to the open approach. These and similar studies support our proposition that TAPP can be safely used in emergency cases.

Totally laparoscopic bowel resection can be done as per Rebuffat et al.<sup>[13]</sup> and Legnani et al.,<sup>[16]</sup> or it can be performed through a mini-laparotomy once the nonviable bowel has been located laparoscopically. As per Leibl et al.,<sup>[11]</sup> bowel segments and omentum requiring resection can be found in both incarcerated and strangulated hernias, more so in the latter group. They reported two cases requiring omental resection in the incarcerated group, whereas in the strangulated group, two patients required omentectomy, one needed small bowel resection, and one required appendiceal resection. In our study, nine patients required resection: seven were performed laparoscopically, and two necessitated mini-laparotomy.

## CONCLUSION

Our study aligns with previous publications which have shown that the use of laparoscopy in emergency hernia repairs for incarcerated or strangulated hernia patients is feasible and safe. Furthermore, it once again emphasizes the advantage of laparoscopy in reliably evaluating the viability of the incarcerated bowel segment.

**Ethics Committee Approval:** This study was approved by the Kanuni Sultan Suleyman Training Research Hospital Ethics Committee (Date: 23.05.2023, Decision No: 230516).

**Peer-review:** Externally peer-reviewed.

**Conflict of Interest:** None declared.

**Financial Disclosure:** The author declared that this study has received no financial support.

## REFERENCES

1. Reiner M, Bresnahan ER. Laparoscopic total extraperitoneal hernia repair outcomes. *J Soc Laparoendosc Surg* 2016;20:e2016.00043. [[CrossRef](#)]

2. Bittner R, Schwarz J. Inguinal hernia repair: Current surgical techniques. *Langenbecks Arch Surg* 2012;397:271–82. [CrossRef]
3. Bobo Z, Nan W, Qin Q, Tao W, Jianguo L, Xianli H. Meta-analysis of randomized controlled trials comparing Lichtenstein and totally extra-peritoneal laparoscopic hernioplasty in treatment of inguinal hernias. *J Surg Res* 2014;192:409–20. [CrossRef]
4. Bittner R, Arregui ME, Bisgaard T, Dudai M, Ferzli GS, Fitzgibbons RJ, et al. Guidelines for laparoscopic TAPP and endoscopic TEP treatment of inguinal Hernia [International Endohernia Society IEHS]. *Surg Endosc* 2011;25:2773–843. [CrossRef]
5. Sartori A, Balla A, Botteri E, Scolari F, Podda M, Lepiane P, et al. Laparoscopic approach in emergency for the treatment of acute incarcerated groin hernia: a systematic review and meta-analysis. *Hernia* 2023;27:485–501. [CrossRef]
6. Bessa SS, Abdel-fattah MR, Al-Sayes IA, Korayem IT. Results of prosthetic mesh repair in the emergency management of the acutely incarcerated and/or strangulated groin hernias: a 10-year study. *Hernia* 2015;19:909–14. [CrossRef]
7. Bozkurt MA, Gonenç M, Kocataş A, Temizgönül KB, Unsal MG, Alış H. Is Laparoscopy needed for incarcerated hernias that became reducible during induction of general anesthesia?. *American Surg* 2015;81:52–3.
8. Stoker DL, Spiegelhalter DJ, Singh R, Wellwood JM. Laparoscopic versus open inguinal hernia repair: randomised prospective trial. *Lancet* 1994;343:1243–5. [CrossRef]
9. Tschudi J, Wagner M, Klaiber C, Brugger J, Frei E, Krähenbühl L, et al. Controlled multicenter trial of laparoscopic transabdominal preperitoneal hernioplasty vs Shouldice herniorrhaphy. Early results. *Surg Endosc* 1996;10:845–7. [CrossRef]
10. Watson SD, Saye W, Hollier PA. Combined laparoscopic incarcerated herniorrhaphy and small bowel resection. *Surg Laparosc Endosc* 1993;3:106–8.
11. Ishihara T, Kubota K, Eda N, Ishibashi S, Haraguchi Y. Laparoscopic approach to incarcerated inguinal hernia. *Surg Endosc* 1996;10:1111–3.
12. Leibl BJ, Schmedt CG, Kraft K, Kraft B, Bittner R. Laparoscopic transperitoneal hernia repair of incarcerated hernias: Is it feasible? Results of a prospective study. *Surg Endosc* 2001;15:1179–83. [CrossRef]
13. Rebuffat C, Galli A, Scalambra MS, Balsamo F. Laparoscopic repair of strangulated hernias. *Surg Endosc* 2006;20:131–4. [CrossRef]
14. Zanoni AAG, Delcarro A, Ciccarese F, Villa R, Oldani A, Giorgi R, et al. Laparoscopic transperitoneal hernia repair (TAPP) in emergency: long-term follow-up in a high volume centre. *Hernia* 2022;26:1063–8. [CrossRef]
15. Jacob R, Guy SB, Kamila L, Idan C, Shlomi R, Youri M. Comparison of emergent laparoscopic and open repair of acutely incarcerated and strangulated hernias-short- and long-term results. *Surg Endosc* 2023;37:2154–62. [CrossRef]
16. Legnani GL, Rasini M, Pastori S, Sarli D. Laparoscopic trans-peritoneal hernioplasty (TAPP) for the acute management of strangulated inguino-crural hernias: a report of nine cases. *Hernia* 2008;12:185–8. [CrossRef]

## ORİJİNAL ÇALIŞMA - ÖZ

### İnkarsere herni nedeni ile acil operasyon planlanan hastalarda TAPP doğru bir alternatif midir?

#### Levent Eminođlu

Ataşehir Florence Nightingale Hastanesi, Genel Cerrahi Bölümü, İstanbul, Türkiye

**AMAÇ:** İnkarsere herni acil cerrahi müdahale gereken bir tablodur. Bağırsak iskemisinin değerlendirilip rezeksiyon kararının alınabilmesi için inkarsere segmentin tam olarak ortaya konması gerekir. Bu çalışmada amacımız acile başvurup inkarsere herni nedeniyle operasyon planlanan hastalarda yapılan TAPP'ın uygulanabilirliğini ortaya koymaktır.

**GEREK VE YÖNTEM:** Çalışma retrospektif olarak planlandı. Ocak 2015 ile Haziran 2023 tarihleri arasında hastanemiz acil servisine başvurup TAPP yöntemi ile ameliyat edilen hastalar çalışmaya dahil edildi. Tüm hastalarda laparoskopik eksplorasyon ile önce inkarsere olan segment ortaya kondu. Rezeksiyon gerekliliği değerlendirildi. Sonrasında laparoskopik yöntemle herni onarımı yapıldı. Hastaların demografik özellikleri, yapılan ameliyat, bağırsak rezeksiyon gerekliliği, postoperatif morbidite ve mortalite ve nüks yönünden sonuçları not edildi.

**BULGULAR:** Belirlenen süre içerisinde 109 hasta inkarsere herni nedeniyle başvurdu. Başvuran hastalardan 12'i laparoskopik cerrahiye uygun olmadığı veya laparoskopik ameliyat kabul etmediği için çalışma dışı bırakıldı. 97 hastaya TAPP uygulandı. 6 hastada anestezi induksiyonu sonrasında bağırsağın redükte olduğu izlendi. Hastaların 9'unda ise bağırsakta iskemi-nekroz izlendiği için rezeksiyon -anastomoz uygulandı, 7'sinde laparoskopik, 2'sinde açık teknik kullanıldı. Postoperatif 7 hastada seroma, 3'ünde hematoma 2'sinde ise yara enfeksiyonu görüldü. Mortalite izlenmedi. Yapılan takiplerde 1 hastada nüks görüldü.

**SONUÇ:** TAPP hem inkarsere anısı değerlendirme şansı vermesi hem de laparoskopinin avantajları nedeniyle seçili hastalarda acil cerrahi de uygulanabilecek bir prosedürdür.

**Anahtar sözcükler:** Acil cerrahi; inkarsere herni; TAPP.

Ulus Travma Acil Cerrahi Derg 2024;30(2):97-100 DOI: 10.14744/tjtes.2024.63367