

# Safe, fast, and minimally-assisted microsurgical anastomosis with combined open-loop suturing and airborne tying: a clinical and experimental study

✉ Gökhan Sert, M.D.,<sup>1</sup> ✉ Ahmet Hamdi Sakarya, M.D.,<sup>2</sup>

<sup>1</sup>Department of Plastic Reconstructive and Aesthetic Surgery, Ankara Training and Research Hospital, Ankara-Türkiye

<sup>2</sup>Department of Plastic Reconstructive and Aesthetic Surgery, Marmara University Faculty of Medicine, İstanbul-Türkiye

## ABSTRACT

**BACKGROUND:** The continuous open-loop technique accelerates anastomosis and eliminates the risk of inadvertently catching the back wall, which is the primary cause of technical failure when using interrupted sutures in microsurgical anastomosis. Combined with airborne suture tying, the total anastomosis time is significantly reduced. We conducted an experimental and clinical study to compare this combination to the conventional technique.

**METHODS:** Experimentally, anastomoses were performed on the femoral arteries (0.60 mm) of rats in two groups. The control group used simple interrupted suturing with conventional tying, while the experimental group employed open-loop suturing with airborne tying. We recorded the total time taken for anastomosis completion and patency rates. Clinically, we retrospectively analyzed replantation and free flap transfer cases using the open-loop suture and airborne tying technique for arterial and venous microvascular anastomoses, assessing total anastomosis time and patency rates.

**RESULTS:** Experimentally, a total of 40 anastomoses were performed in two groups. The control group required 779.65 seconds, and the experimental group needed 527.4 seconds for anastomosis completion; this difference was statistically significant ( $p < 0.001$ ). Immediate and long-term patency rates were similar ( $p = 0.5483$ ). Clinically, 18 replantations were performed on 16 patients, and 17 free flap transfers were performed on 15 patients, totaling 104 anastomoses. The anastomosis success rate was 94.2% (33 of 35) for free flap transfers and 95.1% (39 of 41) for replantation cases.

**CONCLUSION:** The open-loop suture technique with airborne knot tying allows surgeons to complete microvascular anastomoses safely and in less time with minimal assistance when compared to the simple interrupted suture technique.

**Keywords:** Airborne tying; anastomosis; continuous suture; microvascular; open-loop technique.

## INTRODUCTION

Flawless microvascular anastomosis is one of the most important steps, if not the most important, for tissue survival in free flap transfers and composite tissue allotransplantation, as well as for limb survival in replantation and revascularization cases. An ideal microvascular anastomosis technique, in terms of both suturing and knot tying, should be easy to perform and teach, fast, easy to control for technical failures,

and should reduce operative time and costs while providing stable patency rates. Various techniques have been described in the literature to come up with an ideal solution to address these features simultaneously.<sup>[1-5]</sup> The simple interrupted suture with conventional knot tying is considered by many microsurgeons as the gold standard technique for performing microsurgical anastomosis.<sup>[6]</sup> However, proper application of traction and intermittent irrigation of the lumen with the help of an assistant is usually needed to perform a safe

Cite this article as: Sert G, Sakarya AH. Safe, fast, and minimally-assisted microsurgical anastomosis with combined open-loop suturing and airborne tying: a clinical and experimental study. *Ulus Travma Acil Cerrahi Derg* 2023;29:00-00

Address for correspondence: Gökhan Sert, M.D.

Ankara Eğitim ve Araştırma Hastanesi, Plastik Rekonstrüktif ve Estetik Cerrahi Kliniği, Ankara, Türkiye

Tel: +90 312 - 305 17 62 E-mail: drgokhansert@gmail.com

*Ulus Travma Acil Cerrahi Derg* 2023;29(4):449-457 DOI: 10.14744/tjtes.2023.79702 Submitted: 13.01.2023 Revised: 16.01.2023 Accepted: 22.03.2023  
OPEN ACCESS This is an open access article under the CC BY-NC license (<http://creativecommons.org/licenses/by-nc/4.0/>).



anastomosis. If this is not the case, inadvertent catching of the back wall or inaccurate placement of sutures will not be uncommon when the simple interrupted technique is used, especially for inexperienced surgeons and residents continuing their microsurgical training.<sup>[7,8]</sup> Moreover, each suture is placed and tied in order in this technique. Therefore, this could potentially increase the ischemia time and compromise outcomes when performing multiple flap transfers, multi-digit replantation, or microsurgical revisions. Similarly, a transfer of a bowel flap, such as jejunum or colon, should be completed in a shorter time due to reduced tolerance to ischemia. In order to reduce the total microsurgical anastomosis time, several alternative suturing and knot tying techniques have been proposed in the literature.<sup>[2]</sup>

The continuous open-loop technique was first described by Lee et al. in 1984, primarily to eliminate the risk of inadvertently catching the back wall, which is the major cause of technical anastomotic failure when using the interrupted suture technique.<sup>[9]</sup> Correct application of the loose suture loops allows the surgeon to easily manipulate the vessel edges and creates the greatest advantage of the open-loop suture technique, which is the continuous visualization of the lumen during microsurgical anastomosis. Therefore, lower technical anastomotic failure rates can be expected with the open-loop technique when compared to the simple interrupted suture technique. Moreover, continuous placement of the sutures shares the time advantage of the standard continuous suture technique without the concerns of stricture formation or reduced blood flow rate with the latter.<sup>[10,11]</sup>

Airborne suture tying was first described by Chen et al.<sup>[12]</sup> in 2003 to allow quicker completion of a microvascular anastomosis. Although this technique does not contribute to improved patency rates of the anastomosis, as it is not related to suture placement, it does significantly speed up the anastomosis by preventing the suture ends from sticking to the tissue and alleviating the cumbersome process of picking the suture end off the surrounding structures.<sup>[3,4]</sup> With the utilization of the airborne knot tying technique, the total anastomotic time would be much less with the open-loop technique, which is a modification of continuous suturing.

The open-loop suture and airborne tying techniques are not innovations, and either technique or a combination is commonly preferred in some areas, such as Taiwan, where both authors completed their fellowships. However, these techniques have not been widely adopted around the world, and evidence of the benefits of this combination is scarce in the literature. Our aim was to demonstrate the advantages of this combination through an experimental and clinical study and to increase awareness of these useful, fast, and secure techniques.

## MATERIALS AND METHODS

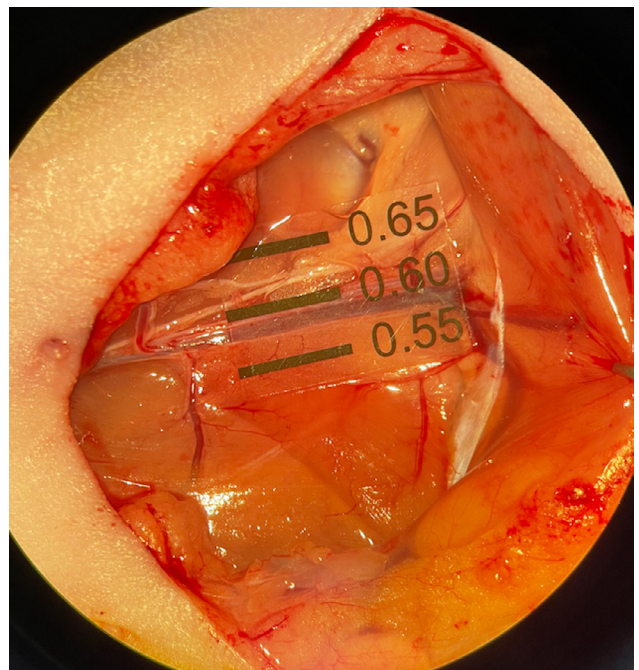
An experimental study was conducted to compare the combined open-loop suture and airborne knot tying technique

with the simple interrupted suture and conventional knot tying technique in terms of total anastomosis time and patency rates. To demonstrate the clinical benefits and feasibility of the open-loop suture with the airborne technique, the outcomes of patients who underwent free flap surgery utilizing the proposed combination in microvascular anastomoses were analyzed and discussed.

The experiments were conducted in the Ankara Training and Research Hospital Animal Laboratory, and ethical permission was obtained from the Ethics Board of Animal Experiments (approval no: 70/690-2022). The experimental study and postoperative animal care were conducted in compliance with the institution's ethical guidelines. The clinical study underwent ethical review and approval by the Ethical Board of the Provincial Health Department (approval no: 2020/1), and written consent was obtained from all the patients involved for their participation in the study.

## Experimental Study

Twenty adult male Wistar-Albino rats, weighing 300-350g, were randomized and divided into two groups according to the chosen anastomosis technique. Microsurgical anastomoses were performed on the bilateral femoral arteries of each rat, with a total of twenty anastomoses performed in each group (n=20). In the control group, the simple interrupted suture with conventional knot tying technique was used. In the experimental group, the open-loop suture with airborne knot tying technique was employed for microsurgical anastomosis. Anastomoses were performed at a level where the femoral artery's diameter was 0.60 mm (Fig. 1). Therefore, the total



**Figure 1.** Determining the level of the anastomosis with a micro scale ruler

number of sutures was even for each anastomosis, with a total of eight sutures. The total time for completion of the anastomosis was recorded individually using a digital timer, starting with the passage of the first suture and ending with the tying of the last knot. All of the animals were kept on a twelve-hour day and night cycle, in plastic cages with sawdust bedding in a standardized temperature (24°C) and humidity-controlled environment, and fed ad libitum. All the experimental cases were performed by the same author (G.S).

## Surgical Technique

The rats were anesthetized with an intraperitoneal injection of ketamine hydrochloride (80 mg/kg) and xylazine (10 mg/kg). Bilateral inguinal regions were shaved and cleaned with an antiseptic solution. A 2.5 cm skin incision was used to expose the femoral artery and vein. The superficial epigastric artery and vein were ligated and cut after complete mobilization of the fat pad. The artery was dissected off the vein, and limited adventitiectomy was performed with sharp micro-scissors. The artery was sharply cut after defining the level with a microscale ruler and placing double approximator Acland clamps. Intraluminal irrigation was performed using a diluted heparinized solution to wash out the remaining blood. Microsurgical anastomosis was completed with the specific technique using a 10-0 nylon micro suture on a 3/8 of a circle needle (Ethilon, Ethicon, United States) under a surgical microscope (16x magnification). Early patency was checked with a milking test, and the procedure was repeated on the contralateral side. Finally, the incisions were closed primarily with a running non-absorbable suture. On postoperative day twenty-eight, bilateral inguinal scars were re-incised, and the femoral arteries were exposed. Following this, long-term patency was checked using the milking test.

### Simple interrupted suture and conventional knot tying technique (Control Group)

Two stay sutures were placed at 0 and 180 degrees to ensure even spacing between the additional sutures on either wall. Simple interrupted sutures were placed on the opposing vessel ends, and knots were tied conventionally with an initial double throw, followed by an additional two single throws. Once suturing of the anterior wall was completed with three additional sutures, the clamp was rotated 180 degrees to suture the back wall in the same manner.

### Combined open-loop suture and airborne knot tying technique (Experimental Group)

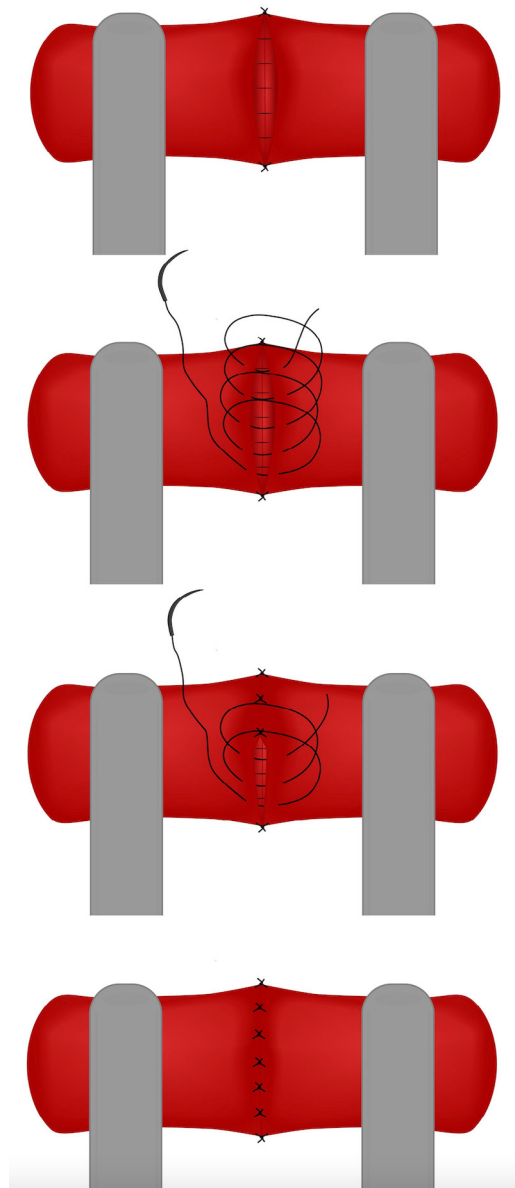
Two stay sutures were placed at 0 and 180 degrees. After this, the suture was passed continuously along the anterior wall to create two loops, starting from the far end and moving towards the surgeon (Fig. 2 and Fig. 3). All the sutures, including the stay sutures, were tied with the airborne technique in order, by cutting the loops sequentially. In the airborne knot tying technique, the suture is pulled through the vessel end so that the leading suture end is about three

times longer than the free end of the thread. The free end is passed behind the opposite end while the right forceps forms the knot and the free end leans on the adjacent loop. The free end is then picked up at its tip and pulled through the loop, completing the knot.

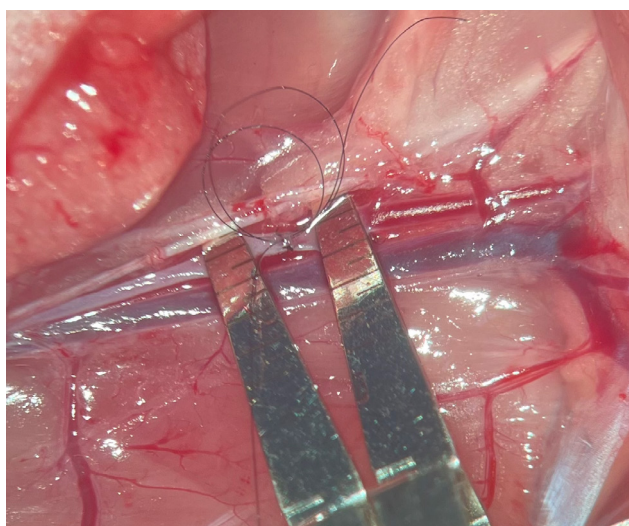
### Technical Notes and Tips:

We would like to emphasize several technical tips to facilitate the use of the open-loop suture technique and ease microvascular anastomosis.

The authors prefer to create small loops and leave the long thread in the first loop if the vessel size is relatively small, magnification is high, and the space is not wide enough to accommodate the redundant suture that tends to get stuck. However, in free flap surgeries with larger vessels and spaces,



**Figure 2.** Illustration of the open-loop suture technique



**Figure 3.** Completed loops in the femoral artery of a rat prior to knot tying.

larger loops and leaving a short thread end in the first loop can be preferred because this would accelerate the anastomosis without having to pull the suture each time for each loop.

Loops should be created from further to closer to the surgeon, or from left to right in vertical anastomosis if the surgeon prefers left micro forceps to tie the suture, and preferably each loop being larger or smaller to avoid suture entanglement. The clockwise rotation of the needle holder while pulling out the needle from the vessel edge is followed by a counterclockwise rotation to hold and reposition the needle back to continue for the next loop. The environment should be moist but not too wet. If it is too wet, loops can stick back to the pooled area. Irrigation after completing the loops helps the loops fix closer to the surgeon and ease the suture tying. Moist gauze around the surgical area helps to avoid the suture sticking or being trapped in unintended areas. If the loops are tangled and stuck, be gentle and patient when untangling.

The airborne technique is much easier to apply under less magnification with larger sutures. The authors suggest practicing in these conditions first. The long thread is generally preferred to be at least twice as long as the short thread. If the length of both threads is similar, more vertical use of the left forceps (for a right-handed surgeon) with more rotation would be needed.

Lastly, microsurgical instruments should be in good condition and clean for a higher level of precision.

### Statistical Analysis

Statistical analysis was performed using Windows SPSS 23.0 (IBM Corporation, Armonk, New York, United States). Both groups were analyzed for normal distribution using the Sha-

piro-Wilk test, and the homogeneity of the variances was analyzed with the Levene's test. The student t-test was used for the comparison of the quantitative data (total anastomosis time) of two independent groups. The chi-square test was used to compare the categorical data (patency of the anastomoses).

Descriptive statistics of the quantitative variables were presented as mean  $\pm$  standard deviation and distribution range (minimum-maximum). Categorical variables are reported as frequency (percentage) in the tables. All of the variables were examined at a 99% confidence level, and  $p < 0.01$  were considered statistically significant.

## RESULTS

### Anastomosis Time

The mean time required for completion of an anastomosis was 779.65 seconds (13 mins, range: 706-848 s) in the control group and 527.4 seconds (8.7 mins, range: 462-592 s) in the experimental group (Table 1). The difference in total anastomosis time between the two groups was statistically significant ( $p < 0.001$ ).

### Thrombosis Rates

A milking test conducted immediately after completion of the anastomosis revealed 100% patency rates in both groups (Table 2). Two anastomoses in group I and one anastomosis in group II were recorded as occluded when the milking test was repeated on postoperative day 28. The comparison of long-term patency rates of the two groups revealed no statistically significant difference ( $p = 0.5483$ ).

### Clinical Outcomes

The proposed technique was used in 35 microsurgical procedures, in a total of 31 patients. Eighteen replantations were performed in 16 patients, and 17 free flap transfers were performed in 15 patients. A total of 104 anastomoses were performed. The cases and outcomes are presented in detail in Table 3.

### Free Flap Transfers (n=17)

Three of the 15 patients were female and 12 were male. The patients' ages ranged between 4-47 years (mean 26.4, median 24). Five patients were in the pediatric group (4-17 years, mean 11, median 10).

Only one patient was operated on for a congenital defect, while the remaining 16 free flaps were used for treatment of traumatic defects. Thirteen of the 16 free flaps were performed for acute traumatic defects, such as gunshot injuries, mine explosions, traffic accidents, and landslide injuries. The remaining three flaps were used for treatment of chronic sequelae after an initial trauma: burn contracture, scaphoid nonunion, and Volkmann ischemic contracture. Six superficial

**Table 1.** Comparison of total anastomosis time between two groups

	n	Total anastomosis time (seconds)		p Value
		Mean±SD	Range (Min-Max)	
Group I	20	779,65±43,66	706-848	<0.001 <sup>a</sup>
Group II	20	527,4±34,80	462-592	

<sup>a</sup> Student-T test. SD: Standard deviation. Min: Minimum. Max:Maximum.

circumflex iliac artery perforator flaps (SCIP), five anterolateral thigh flaps (ALT), one gracilis muscle flap, one osteocutaneous fibula flap, one peroneal artery perforator flap, one deep circumflex iliac artery perforator flap (DCIAP), one iliac crest bone flap, and one femoral condyle chimeric cutaneous-osteoperichondrial flap were used in 15 patients. Eight flaps (one ALT, six SCIP, and one DCIAP) were harvested in a thin fashion; four of these eight flaps (three SCIP and one DCIAP) were elevated in a super-thin fashion. One patient was operated on with two free flaps due to a wide defect, and another patient was operated on with a secondary free flap to salvage the total loss of the first flap.

All venous anastomoses and 11 arterial anastomoses were performed in an end-to-end configuration, whereas 5 arterial anastomoses were performed in an end-to-side fashion. One arterial anastomosis was performed in a 'T' shape in order to restore distal vascularization to the affected limb. One vein graft was used for a vein defect.

Sixteen of the 17 flaps (94.1%) fully survived; however, one thin SCIP flap failed due to congestion. One end-to-side arterial anastomosis was revised and converted to an end-to-end fashion because of kinking and subsequent thrombosis. Another revision was conducted to salvage venous compression due to a hematoma without revising the anastomosis.

In total, 37 anastomoses (19 veins, 18 arteries) were performed in 17 free flap transfers. Anastomoses were technically successful in 33 of 35 cases, representing an anastomosis success rate of 94.2%; double artery repair for flow-through reconstruction and the use of a vein graft were counted as double anastomoses, yet double vein repair in one case was excluded.

The mean diameter of the anastomotic site was 1.8 mm (1.2-2.4 mm) for arterial anastomoses and 1.7 mm (1.1-2.6 mm) for venous anastomoses in free flap transfers. The mean time needed to complete a single arterial anastomosis was 551.9 seconds (9.1 minutes, range: 385-730 s), whereas 594.2 seconds (9.9 minutes, range: 435-745 s) were needed to complete a single venous anastomosis.

### Replantations (n=18)

A total of 18 replantations were performed on 16 patients

**Table 2.** Comparison of the anastomosis outcomes

	Outcome n, (%)				
			Immediate		
	Total	Patent	Total	Patent	
Group I	20	20 (100%)	Group I	20	20 (100%)
Group II	20	20 (100%)	Group II	20	20 (100%)

(Table 4). The patients' ages ranged from 4 to 69 years (mean 35, median 33). Four patients were in the pediatric group (4-17 years, mean 10.75, median 11.5). All of the patients were male, and the etiology was trauma in all cases. Four patients had clean-cut injuries, while the remaining patients had different types of crush-avulsion injuries. Fourteen patients underwent surgery for digital amputation, one patient for near-total ear amputation, and one patient for toe amputation. A total of 5 vein grafts were used, two for vein defects and three for artery defects. Two of the 18 replantations failed,

**Table 3.** Free flap transfers

Total number of patients	15
Total number of flaps	17
Age	4-47
Gender (Male/Female)	12/3
Flap type	
SCIP	6
ALT	5
Gracilis	1
Fibula	1
PAP	1
DCIAP	1
Iliac bone	1
Femoral condyle	
Recipient vessels	
Posterior tibial artery	4
Radial artery	3
Dorsalis pedis	3
Anterior tibial artery	2
Ulnar artery	1
Digital artery	1
Posterior circumflex radial artery perforator	1
Multiple anastomoses	
Double arterial anastomosis	1
Double vein anastomosis	1
Anastomoses with vein grafts	1
Flap success	16/17 (94.1%)

**Table 4.** Replantations

Total number of patients	16
Total number of replantations	18
Age	4-69
Gender (Male/Female)	16/0
Type of amputation	
Single digit	13
Three digits	1(3)
Single toe	1
Near-total ear	1
Number of the vein grafts used	
For Arterial Defect	3
For Vein Defect	2
Replantation success	16/18 (88.8%)

while the remaining 16 cases resulted in success without any anastomosis revision, representing an 88.8% success rate.

The mean diameter of the vessels was 0.75 mm (0.60-1.2 mm) for arterial anastomoses and 0.70 mm (0.5-1.1 mm) for venous anastomoses in replantation cases. The mean time needed to complete a single arterial anastomosis was 426.4 seconds (7.1 minutes, range: 385-540 seconds), whereas 465.6 seconds (7.7 minutes, range: 420-615 seconds) were required to complete a single venous anastomosis. In total, 67 anastomoses (39 veins, 28 arteries) were performed in 18 replantations, including vein grafts, multi-vein repairs, and double artery repairs. Excluding double vein and artery repairs but counting the vital vein grafts as two anastomoses, the known successful patency rate was 39/41 (95.1%) (Table 5).

## DISCUSSION

Our experimental and clinical results clearly show that the combination of these two techniques is safe, fast, and reduces the need for assistance. Our experimental study demonstrates an extremely high success rate (95-100%), which is similar to the literature (75-100%) and also comparable to the author's experimental study using the conventional technique (96%).<sup>[2,15]</sup> Our clinical study reveals a 94.2% success rate in

free flap surgery, which is also in line with the literature (91-99%).<sup>[16]</sup> A large series of replantations were reported by Fufa et al., with a digit survival rate of 57% in 121 digits, where 59% of these were due to sharp cuts.<sup>[17]</sup> Several reported outcomes were published outside of the U.S., with higher success rates reaching over 80%.<sup>[18]</sup> Although different types of mechanisms of injury, amputation levels, variable ischemia times, patient comorbidities, and numbers of patients make it difficult to objectively compare the outcomes between studies, we believe that our success rate (83.3%) is comparable to the literature and could be primarily attributed to the safety of the anastomosis technique.

The reported time advantage in our experimental study was 32% (13 minutes vs. 8.7 minutes) when compared to the simple interrupted suture technique with conventional knot tying. We performed the anastomoses on 0.60 mm arteries. We believe that the time advantage would be more significant when projected to anastomoses on vessels greater than 2.0 mm in diameter, which represents the general diameter of vessels used in commonly preferred free flaps. Not surprisingly, our clinical study (for free flap transfers) proved to be faster than conventional anastomosis (9.1-9.9 minutes vs. 16.4 minutes) and similar to coupler anastomosis when compared with the literature.<sup>[19,20]</sup>

Quick and safe microvascular anastomosis increases success in microsurgery, reduces ischemia time, and alleviates the surgeon's frustration when performing the most critical part of the procedure, as we know that the major cause of failure in free flap transfers is technical errors in microvascular anastomoses.<sup>[16]</sup> Among the described techniques for microvascular anastomosis, the continuous suture technique remains one of the fastest options while providing high patency rates.<sup>[21]</sup> However, Schlechter and Guyuron reported a 45% reduction in blood flow rate with the continuous suture group when compared to the interrupted suture group.<sup>[10]</sup> Therefore, microsurgeons should be careful to provide even tension throughout the suture line to reduce the risk of constriction at the anastomosis site. In addition, the whole suture line needs to be taken down to correct small errors encountered at the end of the anastomosis. Because of this, the continuous suture technique is rarely used in microsurgery and is mostly utilized in large vessels by cardiovascular surgeons.<sup>[22]</sup>

**Table 5.** Total number and success rates of the included anastomoses (\*double vein or artery repairs per limb or flap were excluded unless vital such as vein graft for vascularization or double artery repair for flow through anastomosis)

	Total Number of Anastomoses*	Anastomosis Success Rate
Experimental group	20	100% (20/20)
Free flap transfers	35	94.2% (33/35)
Replantations	41	95.1% (39/41)
Total	96	95.8% (92/96)

To reduce the total anastomosis time and to see the lumen clearly at all times, as in the continuous suture technique without being concerned with the related disadvantages, we prefer to use the open-loop suture technique – a continuous suture with the simple interrupted tying concept. Because the sutures are tied separately in this technique, similar to the conventional simple interrupted suture, a reduction in blood flow is not encountered as in the conventional continuous technique.

The conventional simple interrupted suture technique has certain disadvantages. This technique creates less and less space between sutures with each suture placement. Inserting micro forceps into a tight lumen space between sutures becomes more difficult and riskier with the last one or two sutures. In this situation, assistance is needed to retract a suture end, along with irrigation, to show the lumen clearly to the microsurgeon. In this situation, if the irrigation is not well-performed, suture placements are based on 'feel'. One can feel the tactile sensation of the muscle layer without actually seeing it. However, an unnoticed small piece of adventitia or foreign body might get in the anastomosis site. Surgeon fatigue, surgeon or assistant inexperience, a deep and narrow surgical field, or a bloody environment may ease an inadvertent catch of the back wall or adventitia, which results in anastomosis failure. On the other hand, in the open-loop technique, there is enough space between sutures because the sutures are tied last. This is why the surgeon can easily use the tip of the micro forceps to elevate the edge of the vessel. This elevation not only enables one to see the lumen clearly at all times instead of relying on 'feel', but also helps to evert the vessel edges while avoiding adventitia and muscle layer inversion into the vessel lumen. Moreover, finding readily available assistance is not possible at all times, and this technique avoids the requirement of an assistant to irrigate the lumen or retract the suture in most situations. Therefore, this technique becomes especially useful when there is no one to assist. Another disadvantage of the conventional technique arises when there is a tendency for intimal separation, as in atherosclerotic vessels. In these vessels, using traction in the sutures without micro forceps support beneath the intima may cause advanced separation. The wide space in the lumen, thanks to the open-loop technique, enables the surgeon to easily support the intima with micro forceps. The authors do not prefer traction techniques unless the position of the vessels is exceptionally difficult to perform a microsurgical anastomosis.

The airborne suture tying technique significantly speeds up the anastomosis by preventing the suture ends from sticking to the surrounding tissue.<sup>[3,4]</sup> This is especially useful in preventing the suture end from adhering to adjacent tissues or materials in a moist or bloody environment. Chen et al. advocate that, with experience, incorporating the airborne knot tying into interrupted suturing could potentially save 20% of anastomosis time.<sup>[12]</sup> In our experimental study, the reduction

of anastomosis time by 32% could be partially explained by the airborne technique and partially by the open-loop technique.

Venous anastomosis is considered to be more challenging and can often be technically demanding because of the thin vessel wall and collapse of the lumen during suture placement. Coupling anastomotic devices were introduced to the field of microsurgery to overcome the difficulties experienced with venous anastomoses, as well as to speed up the anastomosis. Patency rates were reported to be similar, whereas significantly decreased total anastomotic time was observed when coupling anastomotic devices were compared to hand-sewn anastomoses (9.5 minutes vs. 21 minutes, respectively), specifically when the simple interrupted suture technique is used.<sup>[23,24]</sup> In the clinical part of our study, 9.1-9.9 minutes were needed for a single anastomosis in free flap transfers and 7.1-7.7 minutes in replantation cases. These results are comparable to the reported results in the coupling devices' literature. Despite the time benefit of coupler devices, this technique has several disadvantages. The coupler device is far more suitable for venous anastomosis rather than arterial anastomosis due to the pliability of the vessel wall to be everted over the pins of the device.<sup>[25]</sup> Moreover, it is not suitable for vessels with small diameters and end-to-side anastomoses. It is not readily usable for many centers, and assistance is required during anastomoses. The high cost and the difficulty of its application when size discrepancy is encountered limit its wide acceptance, and hand-sewn anastomosis is still considered the gold standard technique to execute a microvascular anastomosis.

These techniques have a number of disadvantages, such as a steep learning curve. However, using the technical tips mentioned in the material method section, the learning curve to master the open-loop suture technique with airborne tying is not too steep, and we encourage microsurgeons to adopt this in their routine practice. Chen and Chiu advocate the use of a modification of the continuous suturing, spiral interrupted suture technique, by beginning knot tying and cutting all the loops at once.<sup>[26]</sup> We do not prefer this because the thread ends may stick to surrounding tissue or adventitia and this may complicate catching the threads and cause time loss. Nevertheless, there may be numerous modifications of these techniques and surgeons may develop their own methods with practice. For starters, the last two or three sutures can be completed using the open-loop technique for better visualization of the lumen, as well as for familiarizing oneself with the new technique. Another technical disadvantage is that there are conditions in which this combination is difficult to perform. For example, in liver transplantations, and in cases where the anastomosis site is deep, the stump is short or there is not enough room for the vessel approximator, the posterior wall first technique can be used for the posterior wall, and then the anterior wall can be completed with the open-loop technique.<sup>[27]</sup>

Our study includes a number of limitations and strengths. Firstly, the limited sample size in the clinical study and low failure rates make it difficult to come to a significant conclusion in terms of the safety of anastomoses. Secondly, there is no control group in the clinical part of the study, as both authors prefer these techniques routinely as their first choice. Thirdly, conducting a clinical anastomosis study is extremely challenging due to numerous variables that may affect patency, such as different patient characteristics, etiology of the defect, nature of trauma, recipient sites, flap types and vessel diameters, surgeon's experience and fatigue, and so on. However, our study diminishes these variables by incorporating an experimental study performed by a single surgeon, and a clinical study performed by another single surgeon, both of whom had already completed the learning curves in these techniques.

## Conclusion

The open-loop suture technique with airborne knot tying allows the surgeon to complete a microvascular anastomosis in a shorter time with minimal assistance when compared to the simple interrupted suture technique. Continuous visualization of the vessel lumen comprises a low risk of inadvertent catch of the back wall or adventitia during the anastomosis. The proposed technique in our study can be the technique of choice especially for less experienced microsurgeons, in order to decrease technical failure, or for experienced microsurgeons to speed up the anastomosis with minimal assistance under difficult conditions.

**Ethics Committee Approval:** This study was approved by the Ağrı State Hospital Clinical Research Ethics Committee (Date: 27.12.2019, Decision No: 5721253-799-1346).

**Peer-review:** Externally peer-reviewed.

**Authorship Contributions:** Concept: A.S.; Design: A.S.; Supervision: A.S.; Fundings: G.S., A.S.; Materials: G.S., A.S.; Data: G.S.; Analysis: G.S., A.S.; Literature search: G.S.; Writing: G.S.; Critical revision: G.S., A.S.

**Conflict of Interest:** The authors have no conflict of interest to declare.

**Financial Disclosure:** The authors declared that this study has received no financial support.

## REFERENCES

- Geierlehner A, Rodi T, Mosahebi A, Tanos G, Wormald JCR. Meta-analysis of venous anastomosis techniques in free flap reconstruction. *J Plast Reconstr Aesthet Surg* 2020;73:409–20. [\[CrossRef\]](#)
- Alghoul MS, Gordon CR, Yetman R, Buncke GM, Siemionow M, Afifi AM, et al. From simple interrupted to complex spiral: A systematic review of various suture techniques for microvascular anastomoses. *Microsurgery* 2011;31:72–80. [\[CrossRef\]](#)
- Sert G, Aksoyler D, Kara M, Bolletta A, Losco L, Cam SB, et al. Comparison of total anastomosis time between four different combinations of suturing and knot tying techniques in microsurgical anastomosis. *J Plast Surg Hand Surg* 2023;57: 240–6. [\[CrossRef\]](#)
- Agko M, Ciudad P, Chen HC. "Airborne" suture tying technique: Simple steps to make it easy. *Head Neck* 2017;39:2558–61. [\[CrossRef\]](#)
- Leclère FMP, Schoofs M, Buys B, Mordon SR. Outcomes after 1.9-microm diode laser-assisted anastomosis in reconstructive microsurgery: results in 27 patients. *Plast Reconstr Surg* 2010;125:1167–75. [\[CrossRef\]](#)
- Zhang Y, Wang T, Liu Y, He J, Dong J, Xu H. Three end-to-end techniques for microvascular anastomosis of vessels with different size discrepancy. *Ann Plast Surg* 2020;85:141–5. [\[CrossRef\]](#)
- Ghanem AM, Al Omran Y, Shatta B, Kim E, Myers S. Anastomosis Lapse Index (ALI): A validated end product assessment tool for simulation microsurgery training. *J Reconstr Microsurg* 2016;32:233–41. [\[CrossRef\]](#)
- Paladino JR, Gasteratos K, Akelina Y, Marshall B, Papazoglou LG, Strauch RJ. The benefits of expert instruction in microsurgery courses. *J Reconstr Microsurg* 2021;37:143–53. [\[CrossRef\]](#)
- Lee S, Hweidi SA, Skivlocki WP. An open-loop technique to facilitate microtubal anastomoses in the rat. *J Reconstr Microsurg* 1984;1:45–8.
- Schlechter B, Guyuron B. A comparison of different suture techniques for microvascular anastomosis. *Ann Plast Surg* 1994;33:28–31. [\[CrossRef\]](#)
- Sapountzis S, Kiranantawat K, Lim SY, Constantinides J, Ciudad P, Nicolli F, Wei MY, Sönmez TT, Chen HC. A novel "continuous-interrupted" method for microvascular anastomosis. *Microsurgery* 2014;34:82–4.
- Chen HC, Mardini S, Tsai FC. "Airborne" suture tying technique for the microvascular anastomosis. *Plast Reconstr Surg* 2004;113:1225–8. [\[CrossRef\]](#)
- Acland RD. *Microsurgery practice manual*. St Louis, MO: Mosby; 1979.
- Lee KT, Park BY, Kim EJ, Kim JH, Jang KT, Choi SH, et al. Superthin SCIP flap for reconstruction of subungual melanoma: Aesthetic functional surgery. *Plast Reconstr Surg* 2017;140:1278–89. [\[CrossRef\]](#)
- Sakarya AH, Uzun H, Türkkanı A, Çakar AN, Hsieh YH, Üstün GG, et al. Effects of systemic and local caffeine on vessel diameter, anastomosis patency, and intimal hyperplasia in the rat. *J Reconstr Microsurg* 2019;35:244–53. [\[CrossRef\]](#)
- Gardiner MD, Nanchahal J. Strategies to ensure success of microvascular free tissue transfer. *J Plast Reconstr Aesthet Surg* 2010;63:e665–73.
- Fufa D, Calfee R, Wall L, Zeng W, Goldfarb C. Digit replantation: experience of two U.S. academic level-I trauma centers. *J Bone Joint Surg Am* 2013;95:2127–34. [\[CrossRef\]](#)
- Dec W. A meta-analysis of success rates for digit replantation. *Tech Hand Up Extrem Surg* 2006;10:124–9. [\[CrossRef\]](#)
- Ardehali B, Morrill AN, Jain A. Systematic review: anastomotic microvascular device. *J Plast Reconstr Aesthet Surg* 2014;67:752–5. [\[CrossRef\]](#)
- Zhu Z, Wang X, Huang J, et al. Mechanical versus hand-sewn venous anastomoses in free flap reconstruction: A systematic review and meta-analysis. *Plast Reconstr Surg* 2018;141:1272–81. [\[CrossRef\]](#)
- Chen YX, Chen LE, Seaber AV, Urbaniak JR. Comparison of continuous and interrupted suture techniques in microvascular anastomosis. *J Hand Surg Am* 2001;26:530–9. [\[CrossRef\]](#)
- Tiwari A, Cheng KS, Salacinski H, Hamilton G, Seifalian AM. Improving the patency of vascular bypass grafts: the role of suture materials and surgical techniques on reducing anastomotic compliance mismatch. *Eur J Vasc Endovasc Surg* 2003;25:287–95. [\[CrossRef\]](#)
- Fitzgerald O'Connor E, Rozen WM, Chowdhry M, Patel NG, Chow WT, Griffiths M, et al. The microvascular anastomotic coupler for venous anastomoses in free flap breast reconstruction improves outcomes. *Gland Surg* 2016;5:88–92.
- Maruccia M, Fatigato G, Elia R, Ragusa LA, Vestita MG, Nacchiero E, et al. Microvascular coupler device versus hand-sewn venous anastomosis: A systematic review of the literature and data meta-analysis. *Microsur-*



- gery 2020;40:608–17. [CrossRef]
25. Adam D, Broderick D, Kyzas P, Vassiliou L. Microvascular anastomotic coupler devices versus hand-sewn technique for arterial anastomosis: a systematic review. *Br J Oral Maxillofac Surg* 2021;59:524–33. [CrossRef]
26. Chen L, Chiu DT. Spiral interrupted suturing technique for microvascular anastomosis: a comparative study. *Microsurgery* 1986;7:72–8. [CrossRef]
27. Harris GD, Finseth E, Buncke HJ. Posterior-wall-first microvascular anastomotic technique. *Br J Plast Surg* 1981;34:47–9. [CrossRef]

## DENEYSSEL ÇALIŞMA - ÖZ

### Kombine açık-ilmek/Airborne bağlama tekniği ile hızlı, güvenli ve minimal asistans gerektiren mikrovasküler anastomoz: Deneysel ve klinik çalışma

Dr. Gökhan Sert,<sup>1</sup> Dr. Ahmet Hamdi Sakarya<sup>2</sup>

<sup>1</sup>Ankara Eğitim ve Araştırma Hastanesi, Plastik Rekonstrüktif ve Estetik Cerrahi Kliniği, Ankara

<sup>2</sup>Marmara Üniversitesi Plastik Rekonstrüktif ve Estetik Cerrahi Ana Bilim Dalı, İstanbul

**AMAÇ:** Mikrovasküler anastomozda en sık kullanılan teknik basit aralıklı dikiş tekniğidir. Bu tekniğin en önemli riski, arka duvarın iğne ucuyla fark edilmeden yakalanması ve anastomozun başarısızlıkla tamamlanmasıdır. Çalışmamızda, bu riski ortadan kaldırmak ve anastomoz süresini kısaltmak için açık-ilmek tekniği ile Airborne bağlama tekniğinin kombinasyonu kullanıldı. Bu kombinasyonunun konvansiyonel teknik ile karşılaştırılması için deneysel ve klinik bir çalışma gerçekleştirildi.

**GEREÇ VE YÖNTEM:** Deneysel olarak sıçan femoral arterinde konvansiyonel tekniğin kullanıldığı (kontrol grubu) ve açık-ilmek/Airborne bağlama kombinasyonunun kullanıldığı (deneysel grup) iki deneysel gruptaki anastomozlarda, anastomoz patensi ve anastomoz süresi karşılaştırıldı. Klinik olarak ise açık-ilmek/Airborne bağlama kombinasyonunun kullanıldığı acil parmak replantasyonları ve serbest flep transferi vakalarındaki anastomoz patensleri ve anastomoz süreleri retrospektif olarak analiz edildi.

**BULGULAR:** Deneysel çalışmada iki grupta toplam 40 mikrovasküler arteriyel anastomoz gerçekleştirildi. Total anastomoz süresinin kontrol grubunda 779,65 saniye, deneysel grupta 527,4 saniye olduğu ve farkın istatistiksel olarak anlamlı olduğu görüldü ( $p<0.001$ ). Erken ve geç dönemdeki anastomoz patensleri arasında anlamlı fark bulunmadı ( $p=0.5483$ ). Klinik çalışma dahilinde 16 hastada 18 acil parmak replantasyonu ve 15 hastada 17 serbest flep transferi gerçekleştirildi (toplam 104 anastomoz). Anastomoz başarısının acil replantasyon vakalarında %94.2, serbest flep transferlerinde %95.1 olduğu görüldü.

**TARTIŞMA:** Konvansiyonel teknik ile karşılaştırıldığında açık-ilmek/Airborne kombinasyonu mikrocerrahin mikrovasküler anastomozu daha kısa sürede, güvenli ve asistans gerektirmeksizin tamamlamasına olanak sağlar.

**Anahtar sözcükler:** Açık ilmek; airborne; mikrocerrahi; mikrovasküler anastomoz; replantasyon.

*Ulus Travma Acil Cerrahi Derg* 2023;29(4):449-457 doi: 10.14744/tjtes.2023.79702