

# Effect of high volume enema in children with abdominal pain: Pediatric emergency department experience

 Serpil Sancar, M.D.,<sup>1</sup>  Esra Türe, M.D.,<sup>2</sup>  Seda Sinem Zonüzi, M.D.<sup>2</sup>

<sup>1</sup>Department of Pediatric Surgery, University of Health Sciences, Bursa City Hospital, Bursa-Türkiye

<sup>2</sup>Department of Pediatric Emergency Medicine, University of Health Sciences, Bursa City Hospital, Bursa-Türkiye

## ABSTRACT

**BACKGROUND:** Abdominal pain is one of the most common reasons for admission to the pediatric emergency clinic. The appropriate evaluation of clinical and laboratory clues to make the correct diagnosis is of great importance in terms of directing the treatment medically or surgically and preventing unnecessary investigations. The aim of our study was to evaluate the contribution of high-volume enema application among pediatric patients with abdominal pain in terms of clinical and radiological findings.

**METHODS:** Among the pediatric patients who applied to the pediatric emergency clinic of our hospital between January 2020 and July 2021 with abdominal pain, those who had intense gas stool image on abdominal X-ray and abdominal distension on physical examination and who underwent high-volume enema treatment were included in the study. The physical examination and radiological findings of these patients were evaluated.

**RESULTS:** During the study period, 7819 patients were admitted to the pediatric emergency outpatient clinic with abdominal pain. Classic enema was performed in 3817 of these patients who had a dense gaseous stool image and abdominal distention on abdominal X-ray graphy. Defecation occurred in 3498 (91.6%) of 3817 patients who underwent classical enema, and the complaints regressed after enema. High-volume enema was applied to 319 (8.4%) patients who did not find relief with classical enema. Complaints of 278 (87.1%) patients regressed after the high-volume enema. Control ultrasonography (US) was performed in the remaining 41 (12.9%) patients, 14 (34.1%) patients were diagnosed with appendicitis. US results of 27 (65.9%) patients who had repeated US were evaluated as normal.

**CONCLUSION:** High volume enema treatment is an effective and safe method in children with abdominal pain who are unresponsive to classical enema application in the pediatric emergency department.

**Keywords:** Abdominal pain; constipation; high volume enema; pediatric emergency clinic.

## INTRODUCTION

Abdominal pain is one of the most common reasons for emergency admissions among the pediatric population.<sup>[1,2]</sup> Although the causes of childhood abdominal pain mostly originate from the gastrointestinal system, these could be related to the other systems as well.<sup>[3,4]</sup> Taking a proper history and identifying the exact location of the pain might be challenging in the pediatric group. Therefore, it is crucial to assess clinical and laboratory clues carefully to make the correct diagnosis. This also plays a key role in the further management of patients, determining treatment options,

such as medical or surgical, and avoiding unnecessary imaging and over or incomplete treatments.<sup>[5-7]</sup>

Among those, who are admitted to the hospital with abdominal pain, only a small number of patients are diagnosed with serious conditions, and need further management. Most of them can be treated symptomatically.<sup>[8-10]</sup> On the other hand, even though they are rare, some severe cases might be missed, due to misleading short-term relief in the emergency department or suboptimal radiological imaging.<sup>[10-13]</sup> In addition, some children might also be irritated or agitated during the physical examination or radiological imaging

Cite this article as: Sancar S, Türe E, Zonüzi SS. Effect of high volume enema in children with abdominal pain: Pediatric emergency department experience. *Ulus Travma Acil Cerrahi Derg* 2023;29:364-369.

Address for correspondence: Serpil Sancar, M.D.

Sağlık Bilimleri Üniversitesi, Bursa Şehir Hastanesi, Çocuk Cerrahisi Kliniği, Bursa, Türkiye

Tel: +90 224 - 975 00 00 E-mail: sancar.serpil@gmail.com

*Ulus Travma Acil Cerrahi Derg* 2023;29(3):364-369 DOI: 10.14744/tjtes.2023.56866 Submitted: 20.12.2022 Revised: 25.01.2023 Accepted: 30.01.2023  
OPEN ACCESS This is an open access article under the CC BY-NC license (<http://creativecommons.org/licenses/by-nc/4.0/>).



procedure, especially during ultrasound scanning, due to intensive intestinal gas or constipation. This may cause wrong physical examination findings and suboptimal radiological results.<sup>[14,15]</sup> Enema procedures, which improve intestinal motion and help to pass stools, may be beneficial in the emergency department to make a reliable further assessment.<sup>[16–19]</sup> Most of the radiological studies are negatively affected by the extensive gas in the intestinal area and this ends up with inappropriate assessments.<sup>[14,20]</sup> The ultrasound scan, repeated after a proper enema application, would give a more certain diagnosis.<sup>[20,21]</sup> Therefore, enemas may help to decrease these issues either by alleviating the symptoms and increasing the quality of physical examination and radiological investigations. They provide benefits in both diagnosis and treatment with these effects.

The aim of this study is to draw attention to high-volume enema applications in children with abdominal pain, in which may both improve the patients' clinic and increase the accuracy of imaging modalities in our emergency department experience.

## MATERIALS AND METHODS

The clinical research was conducted in our hospital pediatric emergency clinic between the period of January 2020 and July 2021 with patients below 18 years of age. The study protocol was approved by the Institution Clinical Research Ethics Committee. The records of patients, who admitted to hospital with abdominal pain in this period, were investigated retrospectively. The patients whose clinical and radiological findings were consistent with abdominal distension, intestinal gas, or fecal and did not respond to classical enema application were included to the study. The patients who did not have any X-ray findings or responded to classical enema application were not included in the study. In addition, patients with missing documents, or whose records were not reached were excluded from the study. High-volume enema was applied for all patients included to study. While there is an available enema-kit in the emergency department, the procedure was done with the enema kit, in the absence of enema-kit, drip set, and proper catheters based on the patients' age were used for the application. 14-18 Fr catheters were preferred for children, while 12 Fr catheters were used for infants. Once catheter was lubricated, the patient was given a position by

lying on their left lateral side, then the catheter was pushed forward to the anus. The length of the enema kit inside the rectum, the amount of the given saline and the height of the saline bags were determined according to the age groups of patients. It was pushed through the rectum by 2.5–4 cm in infants, 5–7.5 cm in children, and 7.5–10 cm in adolescent. Normal saline was given to the patients via enema system by 50–150 mL for infants, 300 ml for pre-school children, 500–750 mL for school-aged children, and 500–1000 mL for adolescent groups. The height of saline bags was arranged as 15–20 cm in infants, 20–40 cm in children, and 45–60 cm in adolescent groups, respectively (Table 1).

The statistical analysis of our study was done by Statistical Package for the Social Sciences for Windows ver. 20.0 packet program. The n (%) was used for categorical variations. While in conformity with the normal distribution the mean±SD (standard deviation) was used for continuous variables, otherwise median, and inter Quantile range values were used. Descriptive analyses were used to analyze the distribution and frequency of the data and the Chi-square test was used to compare two independent groups in frequency series. Kolmogorov–Smirnov test was used for normality test. The level of significance was accepted as <0.05 in all statistical analyses.

## RESULTS

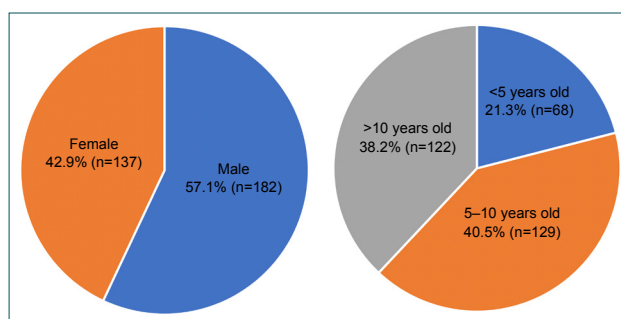
Between the dates of January 2020 and July 2021, 13,678 patients were admitted to our pediatric emergency department due to abdominal pain. On physical examination, abdominal distention was found in 7819 of them (57.2%) alongside abdominal pain. While 3441 (25.2%) patients had chronic constipation, it was found out that 3352 (24.5%) of them had not passed stools for the past 3 days. About 49.6% (6793 patients) of total patients presented with abdominal pain, who had symptoms of abdominal distension and constipation, underwent abdominal direct radiography. Four thousand two hundred and sixteen of these radiographies were consistent with intensive gas imaging. Then, classical enema was applied for those 3817 (90.5%) patients, who had abdominal pain and distension with supportive of abdominal radiography findings. Three thousand four hundred and ninety-eight of them passed stools, as well as significant clinical improvements. However, the rest 319 patients did not pass stools and those who had direct abdominal radiography

**Table 1.** The length of the enema kit inside the rectum, the amount of the given saline and the height of the saline based on the age groups

Age groups	Infants	Pre-school children	School-aged children	Adolescent
Length of the catheter in the rectum	2.5–4 cm	5–7.5 cm	5–7.5 cm	7.5–10 cm
Amount of the fluid given	50–150 ml	300 ml	500–750 ml	1000 ml
The height of saline bag	15–20 cm	20–40 cm	20–40 cm	45–60 cm

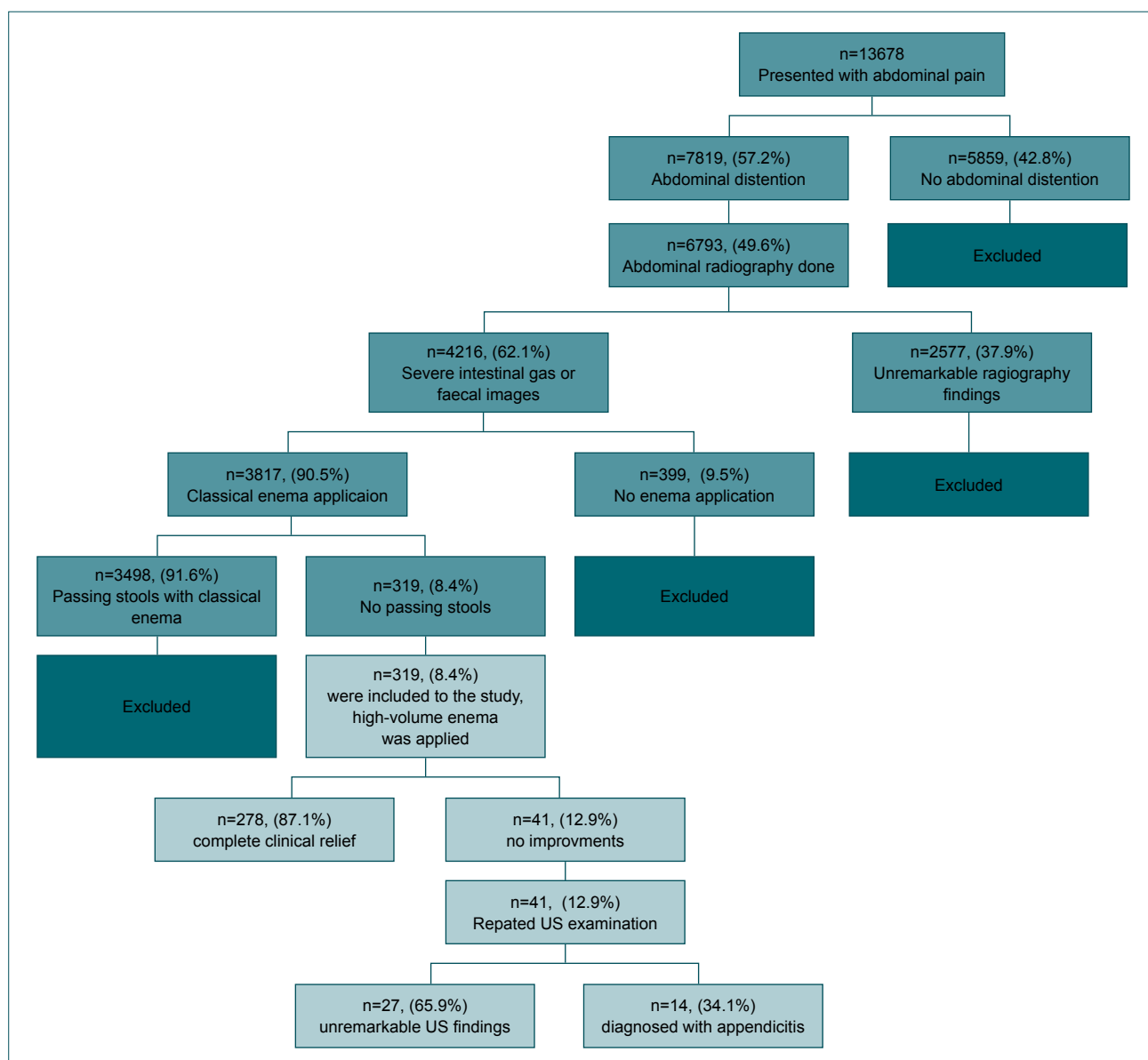
findings, such as abdominal distension, intestinal gas, or fecal imaging, and were not responsive to the classical enema application were included to the study (Fig. 1). High enema was tried for these 319 patients, whose symptoms were not relieved by initial enema application.

In total 319 patients' study groups accounted for 137 female (42.9%) and 182 male (57.1%), respectively. There was no statistically significant association found between genders and symptoms ( $p>0.05$ ). The mean age of all patients was  $6.21 \pm 1.12$  years. When patients were categorized according to age groups, 68 patients (21.3%) were under 5 years old, 129 patients (40.5%) were between the age of 5 and 10 and the rest 122 (38.2%) were older than the age of 10, respectively (Fig. 2). There was no statistically significant association found between age groups and symptoms ( $p>0.05$ ).

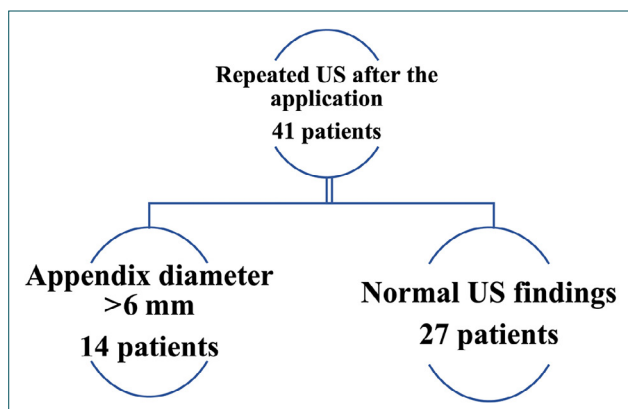


**Figure 2.** Gender and age distributions of patients included in the study.

All patients passed their stools after the high enema application, as well as 278 of them, had complete clinical relief. Forty-one patients, who had not shown clinical improvement, underwent abdominal ultrasonography (US). Fourteen of



**Figure 1.** Flowchart of exclusion and inclusion criteria, and the number of excluded and included patients.



**Figure 3.** Control ultrasonography results after the high volume enema.

them were diagnosed with appendicitis by measuring the appendix diameter over 6 mm, which was not detected by the initial US before high volume enema application. The rest of the US results were evaluated as unremarkable, and these 27 patients followed in our treatment room and after the improvement of their symptoms, they were discharged (Fig. 3).

## DISCUSSION

Abdominal pain is one of the most common complaints seen in the pediatric population and is responsible for the great amount of pediatric emergency admission.<sup>[1,2]</sup> The most common conditions, which may present with abdominal pain, are constipation, gastroenteritis, mesenteric lymphadenitis, urinary tract infections, pneumonia, viral infections, or functional abdominal pain. However, the main challenging for clinicians is identifying the life-threatening or urgent intervention requiring ones. Appendicitis, intussusception, volvulus, malrotation, incarcerated inguinal or umbilical hernia, bowel obstruction, necrotizing enterocolitis, testis or ovarian torsion, diabetic ketoacidosis, Hirschsprung disease, and primary bacterial peritonitis are some of these critical conditions. Therefore, abdominal pain should be assessed quickly and carefully, to detect these patients, who may need urgent intervention.<sup>[5-7]</sup> For the purpose of emergency diagnosis, enema applications are performed in patients with gas and stool retention in emergency services, both for the improvement of complaints and for the correct evaluation of physical examination and imaging findings. We shared our experience with high-volume enema in patients, who were unresponsive to classical enema in our pediatric emergency department. Our aim was to draw attention to this application, which may improve either patient's symptoms or quality of imaging modalities by this study.

Constipation is the common cause of abdominal pain. Magnúsdóttir et al.<sup>[8]</sup> found that non-specific abdominal pain (40%) and constipation (22%) were the most frequently seen abdominal pain causes among pediatric emergency admission due to abdominal pain. In another study conducted by Loening-

Baucke and Swidsinski,<sup>[22]</sup> acute or chronic constipation was detected in 48% of total pediatric emergency admissions of abdominal pain. In our study, the rate of patients suffering from constipation was at the forefront similar to the literature.

Constipation in children has generally functional origins. Functional constipation is defined as, suffering from one the followings passing stool less than twice a week, fecal incontinence at least once a week, taking a position of continence, painful defecation history, presence of big fecal mass in the rectum, and passing stool wide enough to obstruct the toilet according to revised 2016 Rome IV criteria.<sup>[23]</sup> A rectosigmoidal widening and distal colonic fecal retention were found in the radiological imaging of these children. Our patients had also intensive intestinal gas and bowel dilatation on their direct abdominal radiographies.

Management of constipation in the emergency departments consists of treatment and discharging of patients with medical therapy, applications of enema, and the other procedures and medications for dealing with the burden of feces. Even though constipation is not accepted as an emergency, low education, or sociocultural level of parents may end up with high rates of emergency admission for non-urgent conditions. Laxatives could be used for patients with functional constipation, when abdominal pain, gas and fecal retention, or abdominal distention occur. Enema applications may also provide symptomatic relief for those patients. Furthermore, improved abdominal distention and decreased intestinal gas can help to make the differential diagnosis by increasing the quality of clinical and radiological assessment.<sup>[16-19]</sup> Morrow et al.<sup>[24]</sup> showed in their study, which investigated the management of constipation in the emergency departments, that the rate of enema application was 12.9% for patients with diagnosed constipation, while it was 0.6% for those who did not have a diagnosis of constipation. Classical enema application may not always be sufficient for dealing with fecaloid or proximal intestinal gas retention.

After an initial assessment and physical examination, as a radiological imaging modality, an abdominal direct radiograph is one of the diagnostic procedures. It is valuable as a diagnostic tool, as it shows direct and indirect findings of the causes of abdominal pain.<sup>[14,20]</sup> However, the direct findings of functional constipation are gas/feces retention, these findings may also be seen due to the intra-abdominal pathologies. These are generally seen in patients presenting with abdominal pain. The enema applications for these patients groups would be helpful to resolve the retention. At this stage, if it was functional constipation, the patient would have been treated. Otherwise, if the retention occurred due to a condition, such as acute appendicitis, it could help for the assessment of more serious conditions hidden by intestinal gas or feces accumulation. The high-volume enema was tried for patients, who did not respond to the classical enema application in our study. This application is done through the spontaneous

flow (without any pressure on the catheter) by the enema kit or Foley catheter, which is placed into the patient's rectum while lying down on the lateral side. As the classical enema had been applied previously for these patients, their families were pleased with the high-volume enema. This patients and parents' satisfaction was our clinical observation during the application. Painless application without pressure was evaluated as a factor increasing satisfaction. In addition, compared to the classical enema, the increased clinical efficacy of high-volume enema applications by providing passing gas or stools will provide its widespread usage in children. Any complaints or complications related to high-volume enemas were not reported. There are no proper studies about high-volume enemas in the literature. Once our data and experiences with high-volume enema increase, it may be directly offered to particular patients' groups by assessing the previous results with high-volume enema applications. Furthermore, as it was a painless and comfortable procedure based on our clinical experience during the application, new studies, which measure patients and parents' satisfaction with the application, might be planned.

Abdominal gas and feces distention limits the physical examination, they may affect the US findings, as well. Resolving this distention contributes to making the definitive diagnosis by improving the quality of sonographic assessment.<sup>[20,21]</sup> In our study, 14 patients were diagnosed with appendicitis, which were not detected by initial US examination before the high-volume enema application, by control US assessment.

Consequently, this high-volume enema application, which was used in chosen pediatric patient groups with abdominal pain in our emergency department, improved both the patient's symptoms and clinical status, as well as the accuracy of the radiological modalities. Therefore, we believe that it is an effective and safe procedure for patients who do not response with the classical enema applications.

## Conclusion

In our study, we found that the patients, who did not respond to a classical enema, in terms of either defecation or symptomatic relief had good clinical results with the application of a high-volume enema. All of them passed stools after the high-volume enema, while 87.1% of them were provided with symptomatic relief. In addition, 14 appendicitis cases, which were not detected by the initial US, were diagnosed by the second US after the application. In conclusion, a high-volume enema is an effective and safe method for patients with abdominal pain who are unresponsive to classical enema applications in pediatric emergency departments.

**Ethics Committee Approval:** This study was approved by the Bursa City Hospital Clinical Research Ethics Committee (Date: 06.10.2021, Decision No: 2021-18/10).

**Peer-review:** Externally peer-reviewed.

**Authorship Contributions:** Concept: S.S., E.T.; Design: S.S., E.T., S.S.Z.; Supervision: S.S., E.T., S.S.Z.; Analysis: S.S., E.T., S.S.Z.; Literature search: S.S., E.T., S.S.Z.; Writing: S.S., E.T., S.S.Z.; Critical revision: S.S., E.T., S.S.Z.

**Conflict of Interest:** None declared.

**Financial Disclosure:** The authors declared that this study has received no financial support.

## REFERENCES

1. Kwak YH, Kim DK, Jang HY. Utilization of emergency department by children in Korea. *J Korean Med Sci* 2012;27:1222-8. [\[CrossRef\]](#)
2. Lawrence AE, Ervin E, Sebastião YV, Hewitt G, Minnici PC, Deans KJ. Emergency department evaluation of abdominal pain in female adolescents. *J Pediatr Adolesc Gynecol* 2021;34:649-55. [\[CrossRef\]](#)
3. Iyer R, Nallasamy K. Child with abdominal pain. *Indian J Pediatr* 2018;85:71-6. [\[CrossRef\]](#)
4. Smith J, Fox SM. Pediatric abdominal pain: An emergency medicine perspective. *Emerg Med Clin North Am* 2016;34:341-61. [\[CrossRef\]](#)
5. Marin JR, Alpern ER. Abdominal pain in children. *Emerg Med Clin North Am* 2011;29:401-28, ix-x. [\[CrossRef\]](#)
6. Eskelinen M, Lipponen P. Usefulness of history-taking in non-specific abdominal pain: A prospective study of 1333 patients with acute abdominal pain in Finland. *In Vivo* 2012;26:335-9.
7. Robinot DC, de Rojas CL, Pascual EA. Abdominal emergencies in pediatrics. *Urgencias abdominales en pediatría. Radiologia* 2016;58 Suppl 2:80-91. [\[CrossRef\]](#)
8. Magnúsdóttir MB, Róbertsson V, Þorgrímsson S, Rósmundsson Þ, Agnarsson Ú, Haraldsson Á. Abdominal pain is a common and recurring problem in paediatric emergency departments. *Acta Paediatr* 2019;108:1905-10. [\[CrossRef\]](#)
9. Caperell K, Pitetti R, Cross KP. Race and acute abdominal pain in a pediatric emergency department. *Pediatrics* 2013;131:1098-106. [\[CrossRef\]](#)
10. Moriel G, Tran T, Pham PK, Liberman DB. Reducing abdominal radiographs to diagnose constipation in the pediatric emergency department. *J Pediatr* 2020;225:109-16.e5. [\[CrossRef\]](#)
11. Pennel DJ, Goergen N, Driver CP. Nonspecific abdominal pain is a safe diagnosis. *J Pediatr Surg* 2014;49:1602-4. [\[CrossRef\]](#)
12. Kim D, Butterworth SA, Goldman RD. Chronic appendicitis in children. *Can Fam Physician* 2016;62:e304-5.
13. Benabbas R, Hanna M, Shah J, Sinert R. Diagnostic accuracy of history, physical examination, laboratory tests, and point-of-care ultrasound for pediatric acute appendicitis in the emergency department: A systematic review and meta-analysis. *Acad Emerg Med* 2017;24:523-51. [\[CrossRef\]](#)
14. John SD. Imaging of acute abdominal emergencies in infants and children. *Curr Probl Diagn Radiol* 2000;29:141-79. [\[CrossRef\]](#)
15. Hamid MA, Afroz R, Ahmed UN, Bawani A, Khan D, Shahab R, et al. The importance of visualization of appendix on abdominal ultrasound for the diagnosis of appendicitis in children: A quality assessment review. *World J Emerg Med* 2020;11:140-4. [\[CrossRef\]](#)
16. Yokoi A, Kamata N. The usefulness of olive oil enema in children with severe chronic constipation. *J Pediatr Surg* 2021;56:1141-4. [\[CrossRef\]](#)
17. Fernández EB, Herrero RS, González GS, Martín BG, Gutiérrez TE, Fernández JB. Saline enemas as treatment of faecal impaction in paediatric emergencies. *An Pediatr (Barc)* 2009;71:215-20. [\[CrossRef\]](#)
18. Casasnovas AB, Martín FA, Quintana LP, Allué IP, Ruiz FS, Calderón VV. Guidelines for the treatment of functional constipation. *An Pediatr (Barc)* 2011;74:51.e1-7. [\[CrossRef\]](#)

19. Svetanoff WJ, Dekonenko C, Dorman RM, Osuchukwu O, Carrasco A Jr., Gatti JM, et al. Optimization of pediatric bowel management using an antegrade enema troubleshooting algorithm. *J Surg Res* 2020;254:247–54. [CrossRef]
20. Blab E, Kohlhuber U, Tillawi S, Schweitzer M, Stangl G, Ogris E, et al. Advancements in the diagnosis of acute appendicitis in children and adolescents. *Eur J Pediatr Surg* 2004;14:404–9. [CrossRef]
21. PeyvasteH M, Askarpour S, Ostadian N, Moghimi MR, Javaherizadeh H. Diagnostic accuracy of barium enema findings in Hirschsprung's disease. *Arq Bras Cir Dig* 2016;29:155–8. [CrossRef]
22. Loening-Baucke V, Swidsinski A. Constipation as cause of acute abdominal pain in children. *J Pediatr* 2007;151:666–9. [CrossRef]
23. Vriesman MH, Koppen IJ, Camilleri M, Di Lorenzo C, Benninga MA. Management of functional constipation in children and adults. *Nat Rev Gastroenterol Hepatol* 2020;17:21–39. [CrossRef]
24. Morrow A, Dongarwar D, Salihu HM. Health disparities and constipation management among pediatric patients in the emergency department. *J Natl Med Assoc* 2020;112:541–9. [CrossRef]

## ORİJİNAL ÇALIŞMA - ÖZ

### Karın ağrısı olan çocuklarda yüksek volüm lavmanın etkisi: Çocuk acil klinik deneyimi

Dr. Serpil Sancar,<sup>1</sup> Dr. Esra Türe,<sup>2</sup> Dr. Seda Sinem Zonüzi<sup>2</sup>

<sup>1</sup>Sağlık Bilimleri Üniversitesi, Bursa Şehir Hastanesi, Çocuk Cerrahisi Kliniği, Bursa

<sup>2</sup>Sağlık Bilimleri Üniversitesi, Bursa Şehir Hastanesi, Çocuk Acil Kliniği, Bursa

**AMAÇ:** Karın ağrısı, çocuk acil polikliniğine en sık başvuru nedenlerinden biridir. Doğru tanıya gidebilmek için klinik ve laboratuvar ipuçlarının uygun şekilde değerlendirilmesi, tedavinin tıbbi ya da cerrahi olarak yönlendirilmesi ve gereksiz incelemelerin önüne geçilmesi açısından büyük önem taşır. Çalışmamızın amacı karın ağrılı çocuk hastalarda yüksek volüm lavman uygulamasının klinik ve radyolojik bulgulara katkısını değerlendirmektir.

**GEREÇ VE YÖNTEM:** Hastanemiz Çocuk Acil Kliniğine Ocak 2020–Temmuz 2021 tarihleri arasında karın ağrısı şikayeti ile başvuran çocuk hastalardan; fizik muayenede karın şişliği ve direkt karın grafisinde yoğun gaz, gaita retansiyonu olan ve yüksek volüm lavman tedavisi uygulanan hastalar çalışmaya dahil edildi. Bu hastaların fizik muayene ve radyolojik bulguları değerlendirildi.

**BULGULAR:** Çalışma tarihleri arasında 7819 hasta çocuk acil polikliniğine karın ağrısı ile başvurdu. Direkt karın grafisinde yoğun gaz, gaita imajı ve karın distansiyonu olan hastaların 3817'sine klasik lavman yapıldı. Klasik lavman yapılan 3817 hastanın 3498'inde (%91.6) gaita çıkışı ve lavman sonrası şikayetlerinde gerileme oldu. Klasik lavmanla rahatlama olmayan 319 (%8.4) hastaya yüksek volüm lavman uygulandı. Yüksek volüm lavman sonrası 278 (%87.1) hastanın şikayet ve bulguları geriledi. Kalan 41 (%12.9) hastaya kontrol ultrasonografi yapıldı, 14 (%34.1) hastaya apandisit tanısı konuldu. Ultrasonografi tekrarı yapılan 27 (%65.9) hastanın ise ultrasonografi sonucu normal olarak değerlendirildi.

**TARTIŞMA:** Çocuk acil kliniğinde, klasik lavman uygulamasına yanıt vermeyen karın ağrısı şikayeti olan çocuklarda yüksek volüm lavman tedavisi etkili ve güvenli bir yöntemdir.

**Anahtar sözcükler:** Çocuk acil kliniği; kabızlık; karın ağrısı; yüksek volüm lavman.

*Ulus Travma Acil Cerrahi Derg* 2023;29(3):364–369 doi: 10.14744/tjtes.2023.56866