

# Reduction of the scar burden at the donor area of the radial forearm flap with the aid of an endoscopic pedicle preparation

İD Mehmet Sağır, M.D.,<sup>1</sup> İD Erdem Güven, M.D.,<sup>1</sup> İD Aret Cerci Ozkan, M.D.,<sup>2</sup> İD Erol Kozanoğlu, M.D.<sup>3</sup>

<sup>1</sup>Department of Plastic Reconstructive and Aesthetic Surgery, Private Maslak Acıbadem Hospital, İstanbul-Türkiye

<sup>2</sup>Specialist of Plastic Reconstructive and Aesthetic Surgery, Private Practice, İstanbul-Türkiye

<sup>3</sup>Department of Plastic Surgery, İstanbul University, İstanbul Faculty of Medicine, İstanbul-Türkiye

## ABSTRACT

**BACKGROUND:** The radial forearm flap is one of the most commonly used flaps of reconstructive microsurgery with its long pedicle and thin structure. The donor site at the forearm is a visible anatomic region that has high mobility and functional importance. In this study, a longitudinal and large scar was avoided on the forearm during pedicle dissection of the conventional radial forearm flap with the utilization of an endoscope. Furthermore, arterial, venous, and nervous injuries were avoided by performing a separate incision of 2–3 cm at the cubital fossa to reduce flap failure and donor site morbidity.

**METHODS:** The patients who underwent pedicle dissection of the radial forearm flap with the aid of an endoscope for head-neck reconstruction between 2014 and 2021 were included in this study. The flap was harvested from the subfascial plane. The cephalic vein was used in all of the patients. When the pedicle dissection reached the antecubital region, an incision of 2–3 cm was performed from the skin. Two vein anastomoses were performed for each patient.

**RESULTS:** This retrospective study consists of 51 patients. While 45 of the patients were the result of head and neck cancer, six of them had a defect caused by trauma. The average area of skin islands was 40.3 cm<sup>2</sup>, while the full-thickness skin graft size was 24.2 cm<sup>2</sup>. An average of 2.6 cm of scar tissue was formed at the antecubital region. No venous or arterial compromise was observed in the post-operative period. There was no partial or total flap loss in any patient. Localized numbness persisted in the skin area where the superficial sensory branch of the radial nerve is located in 6 (11.7%) patients.

**CONCLUSION:** With endoscopic radial forearm flap harvesting, the longitudinal incision in the forearm and wound healing problems are avoided. The absence of partial or total flap loss has shown that endoscopic harvesting of the radial forearm flap is a safe and reliable method.

**Keywords:** Cephalic vein; endoscope; free flap; head and neck reconstruction; radial forearm flap.

## INTRODUCTION

The radial forearm flap is one of the most commonly used flaps of reconstructive microsurgery with its long pedicle and thin structure. It is frequently used in head and neck region, extremities, and penile reconstructions those requiring thin flaps.<sup>[1-4]</sup> Its fasciocutaneous form is used in soft-tissue recon-

struction and its osteofasciocutaneous form is used in mandible reconstruction.<sup>[2,5]</sup>

The donor site at the forearm is a visible anatomic region that has high mobility and functional importance. The radial forearm flap may have some complications and morbidities in both the donor and the recipient areas.<sup>[1]</sup> Many studies have been

Cite this article as: Sağır M, Güven E, Ozkan AC, Kozanoğlu E. Reduction of the scar burden at the donor area of the radial forearm flap with the aid of an endoscopic pedicle preparation. *Ulus Travma Acil Cerrahi Derg* 2023;29:1296-1302.

Address for correspondence: Mehmet Sağır, M.D.  
Private Maslak Acıbadem Hospital, İstanbul, Türkiye  
E-mail: mdmehmetsagır@gmail.com



*Ulus Travma Acil Cerrahi Derg* 2023;29(11):1296-1302 DOI: 10.14744/tjtes.2023.62186 Submitted: 25.07.2023 Revised: 30.09.2023 Accepted: 07.10.2023  
OPEN ACCESS This is an open access article under the CC BY-NC license (<http://creativecommons.org/licenses/by-nc/4.0/>).

carried out to solve this donor site morbidity.<sup>[1,6-12]</sup> Studies have focused on scarring and wound healing problems in the donor area, and motor and sensory deficits in the extremities.<sup>[2,6,12]</sup> Regardless of the reconstructive necessity and nature of these procedures, recently, patients may claim less scarring due to the increasing esthetic image perception.

In modern plastic reconstructive and esthetic surgical procedures, the endoscope has been used for many flap harvesting procedures.<sup>[13,14]</sup> However, studies on the utilization of endoscope in radial forearm flap harvesting are very limited. Two studies could be attained that focus on the utilization of an endoscope for the pedicle dissection of the radial forearm flap.<sup>[1,6]</sup>

In this study, a longitudinal and large scar was avoided on the forearm during pedicle dissection of the conventional radial forearm flap with the utilization of an endoscope. Furthermore, arterial, venous, and nervous injuries were avoided by performing a separate incision of 2–3 cm at the cubital fossa to reduce flap failure and donor site morbidity.

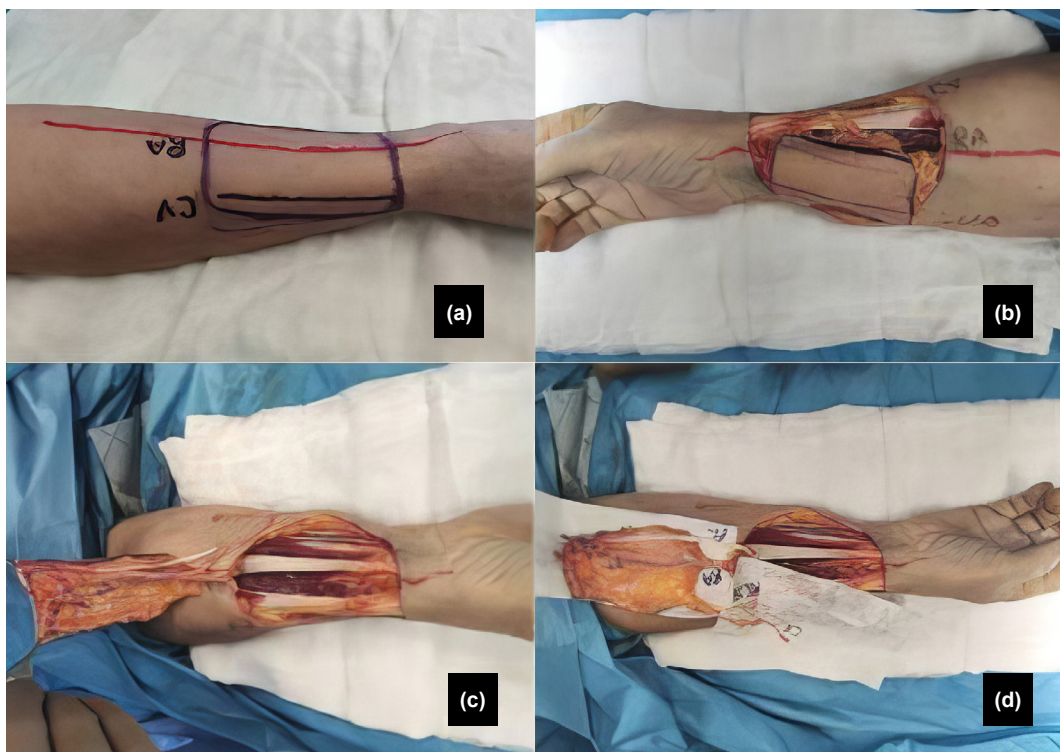
## MATERIALS AND METHODS

The patients who underwent pedicle dissection of the radial forearm flap with the aid of an endoscope for head-neck reconstruction between 2014 and 2021 were included in this study.

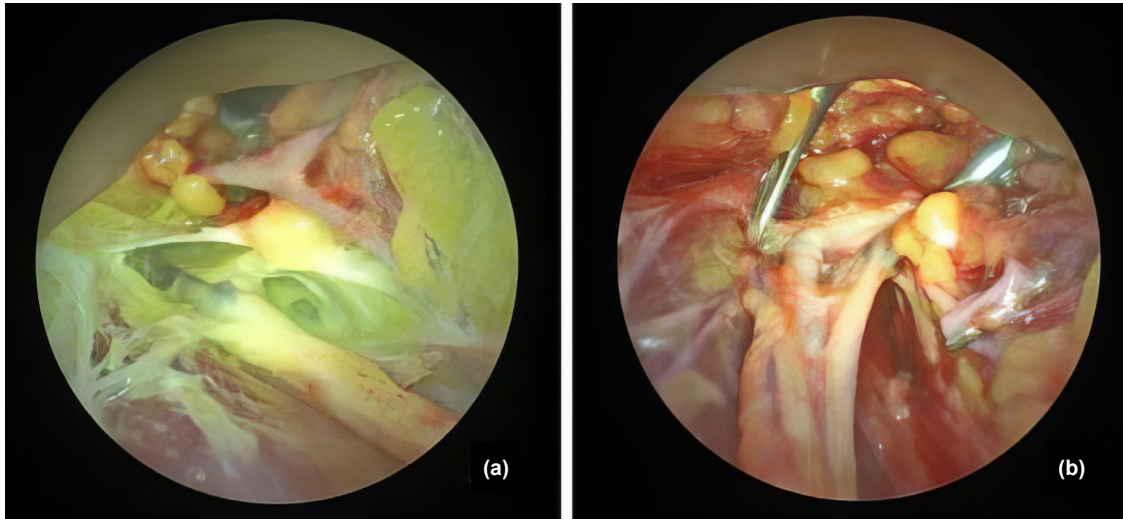
## Surgical Technique

The non-dominant upper extremity was chosen as the flap donor site in all patients. Allen's test was performed preoperatively on all patients, and the test was repeated immediately before the beginning of the operation. A 90° shoulder abduction was performed at the selected upper extremity while the patient was in a supine position. The projection of the radial artery was drawn with the aid of the hand-held Doppler device. The flap was designed at the forearm with the dimensions adjusted and tailored according to the size of the defect to be repaired. The cephalic vein was included in all flaps (Fig. 1a).

The operation was continued under a tourniquet following the design of the flap. The radial artery and the cephalic vein were ligated distally after distal skin and subcutaneous incision. The flap was harvested from the subfascial plane and the paratenons of tendons were preserved. The superficial branches of the radial nerve were preserved as much as possible. After the flap was elevated until its proximal limit, the pedicle, and cephalic vein were dissected with a Carl Storz 10-mm 30° angled endoscope. The branches of the vessels were ligated with hemoclips and cut with scissors (Fig. 2a). When the pedicle dissection reached the antecubital region, an incision of 2–3 cm was performed from the skin, through which the cephalic vein, radial, and ulnar arteries and veins, lateral antecubital nerve, and other nerves were found and



**Figure 1.** (a) Endoscopic radial forearm flap design. (b) The skin island of the flap after the skin and subcutaneous tissue incisions from all edges. (c) The skin island of the flap after the flap elevation. (d) The main structures of the flap (RA: Radial artery, CV: Cephalic vein, RCN: Radial cutaneous nerve (superficial), PL: Palmaris longus tendon, UA: Ulnar artery).



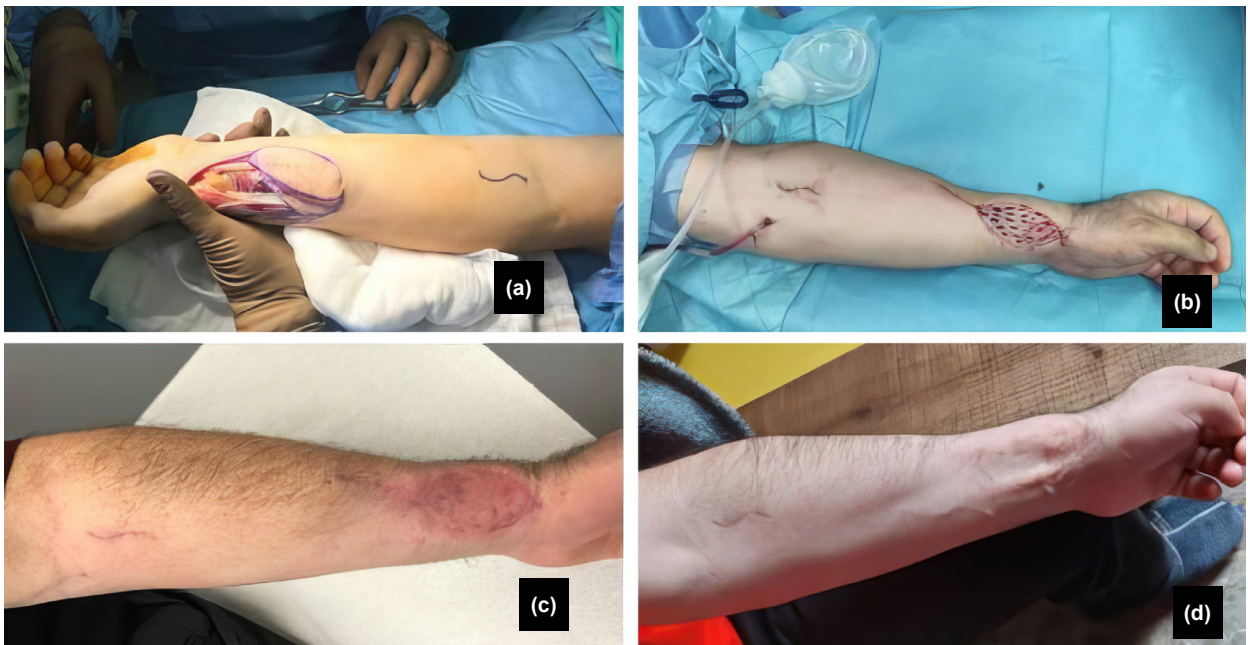
**Figure 2.** (a) Endoscopic view of the radial artery and cephalic vein. (b) The adventitia dissection of the radial artery with the help of a forceps that was inserted through the incision in the antecubital region.

preserved (Fig. 3a). The adventitial dissections of the radial artery and the veins were performed through this incision (Fig. 2b). The ulnar artery was protected by suspending it with a vessel suspender inserted through the antecubital incision. Branches of the cephalic vein suitable for anastomosis and vena comitantes were included at the flap. The median cubital vein was preserved and included the cephalic vein if it will be used (Figures 1b-d).

The tourniquet was deflated to regain circulation and the possible bleeding spots were checked and controlled on the flap. The arteries and veins were ligated with the help of an incision in the antecubital region, and the flap was freed and

transferred to the recipient area. The time between the beginning of the vessel dissection and the transfer of the flap was measured and the hemostasis of the donor site was performed with the aid of the endoscope.

At the recipient area, the radial artery was end-to-end anastomosed to the terminal branches of the external carotid artery and two end-to-end vein anastomoses were performed for each patient. The radial vein was anastomosed with the internal jugular vein system and the cephalic vein was anastomosed with the subclavian vein system. After ensuring the flap circulation, the subsequent stages of the operation were performed.



**Figure 3.** (a) The design of the incision at the antecubital region. (b) The size of the donor area was reduced by primary suturing from the proximal and distal edges. The donor site was repaired with a full-thickness skin graft. (c) The donor site in the 4th post-operative month. (d) The donor site in the 13th post-operative month.

The flap was monitored by observing the skin surface color, the turgor, and the capillary refill. A hand-held Doppler device was utilized hourly for the first 3 days and every 3 h for the next 4 days.

The flap donor area was reduced by the advancement of the adjacent skin and by primary closure from the corners. The sensory branches of the radial nerve were buried under the advanced skin flaps and the branches that could not be covered were ligated. The full-thickness skin graft (FTSG) was harvested from the inguinal region and it was thinned with scissors before being transferred over the donor-site defect (Fig. 3b).

The donor upper extremity was immobilized with a short-arm splint for 3 weeks. All patients were referred to the hand physiotherapy unit for extremity rehabilitation. The patients were seen in the 1st, 2nd, and 4th post-operative weeks and the 3rd, 6th, and 12th post-operative months (Figures 3c and d).

Informed consent was obtained from all patients. Ethical approval was obtained from Acibadem University Ethical Committee (ATADEK) (No: 2023–11/379).

## RESULTS

Fifty-one patients were included in this study. While 45 of the patients were the result of head and neck cancer, six of them had a defect caused by trauma. The demographic characteristics and the operative indications of the patients are shown in Table 1.

All flaps were harvested by the same surgeon. The endoscopic part of the procedure was not switched to the conventional method for any reason in any patient.

The patients were divided into three groups according to the order in which they were operated on. The first 17 patients were grouped as group 1, the second 17 patients were grouped as group 2, and the third 17 patients were grouped as group 3. The average pedicle dissection time for the first, second, and third groups was 35 min, 32 min, and 26 min respectively.

The minimum area of skin islands was at least 24 cm<sup>2</sup>, maximum of 80 cm<sup>2</sup> with an average of 40.3 cm<sup>2</sup>, while FTSG size was at least 18 cm<sup>2</sup>, maximum of 64 cm<sup>2</sup>, and an average of 24.2 cm<sup>2</sup>, as shown in Table 2. Partial graft loss occurred in 5 patients and healed with secondary intention. Tendon exposure did not occur in any patient. Hypertrophic scar occurred at the donor area in two patients. An average of 2.6 cm of scar tissue was formed at the antecubital region, as shown in Table 2.

Numbness and tingling of the medial cutaneous antebrachial sensory area were seen in three patients and they resolved completely in 6 months. Numbness and tingling of the lateral cutaneous antebrachial sensory area were seen in six patients and they resolved completely in 6 months. No sensory prob-

**Table 1.** The demographic characteristics of the patients

	Number
Age	36–73 (mean: 53.3)
Male	43 (84.3)
Female	8 (15.6)
Cancer	45 (88.2)
Trauma	6 (11.7)
Smoke	28 (54.9)
Comorbidity (diabet, hypertension, peripheral vascular disease)	15 (29.4)
Neoadjuvant chemotherapy	4 (7.8)
Adjuvant chemotherapy	28 (54.9)
Neoadjuvant radiation therapy	2 (3.9)
Adjuvant radiation therapy	39 (76.4)

**Table 2.** Measurements of pedicle and cephalic vein length, size of donor and full-thickness graft area, and scar length in the antecubital region

Flap pedicle length (Average)	11-17 cm (13.2 cm)
Cephalic vein length (Average)	13-19 cm (14.1 cm)
Flap skin island size (Average)	24-80 cm <sup>2</sup> (40.3 cm <sup>2</sup> )
Full thickness skin graft size (Average)	18-64 cm <sup>2</sup> (24.2 cm <sup>2</sup> )
Scar length in the antecubital region (average)	1.9-2.8 cm (2.6 cm)

lem was seen at the median cutaneous nerve sensory area. Localized numbness at the sensory area of the superficial sensory branch of the radial nerve persisted in 6 patients (11.7%) in the 1st post-operative year.

Vein grafts were not utilized in any patient. Neither arterial nor venous compromise was seen in any flap during the perioperative period. There was no partial or total flap loss in any patient. The mean follow-up period was 15 months.

No statistical assessments were performed. The data were calculated manually.

## DISCUSSION

Head and neck region defects may occur after cancer surgery or trauma. The radial forearm flap is widely used in defects in this region. Donor site problems such as functional restriction and scar visibility at the upper extremity may discourage the utilization of a radial forearm flap. On the other hand, this flap has many advantages such as its thin structure, reliabil-

ity, versatility, and pliability. For this reason, it may be more logical to reduce the donor site complications. This study has consisted of cases in which the endoscope is utilized for pedicle dissection to get rid of the longitudinal incision of the conventional radial forearm flap. In addition, a small incision made in the cubital fossa preserved the arteries, veins, and nerve structures in this region.

Recently, the endoscope is used for several procedures in numerous surgical branches and it reduces post-operative scar formation.<sup>[15-17]</sup> The requirement of an endoscope and the presence of a learning curve may be regarded as the disadvantages of this technique. The gradual decrease in pedicle dissection time in patient groups may be related to increased experience in time. Unlike the study of Van Kouwenberg et al.,<sup>[1]</sup> we attribute the long dissection time to the fact that cephalic vein dissection and adventitia dissection were performed in the donor area. Of course, adventitia dissection prolongs pedicle dissection time in the donor area. However, since this procedure is performed before the flap ligated the vessel, the ischemia time of the flap is not increased on the contrary, it is shortened.

The primary closure of the donor area in the forearm can be performed in small defects.<sup>[18]</sup> D'arpa et al. used local flaps in selected cases to close the donor area according to the adequacy of the tissues around the donor area in the forearm.<sup>[8]</sup> Although closure methods such as the ulnar flap,<sup>[19]</sup> the bilobed flap,<sup>[20]</sup> Z-plasty,<sup>[21]</sup> and V-Y closure<sup>[22]</sup> may be utilized, they may further distort the forearm appearance. Since our philosophy and the main concern were to reduce the scar burden on the forearm, such methods were not utilized.

Split-thickness (STSG) or FTSG skin grafts can be used to repair the defect.<sup>[8]</sup> Compared to STSG, FTSG provides less contraction and better esthetic and functional results.<sup>[3]</sup> Van Kouwenberg et al. used Integra followed by STSG in most cases for skin defect closure.<sup>[1]</sup> They encountered a complication of 40% in the donor area in cases where they used Integra and 28.57% in cases where they did not use Integra.<sup>[1]</sup> In their four-case series, Kim et al. used allogenic dermis for skin defects.<sup>[6]</sup> Neither Integra nor allogenic dermis was utilized in this study due to the considerable cost of these foreign materials. If the defect was suitable for primary closure, primary closure was performed. If it was not possible, the FTSG was preferred, which was taken from the inguinal region. The inguinal graft donor site is a distant and concealable region.

The blood supply of the forearm skin is provided by the large subcutaneous vascular plexus superficial to the deep investing fascia and from the septocutaneous perforators.<sup>[8]</sup> In a cadaveric study, it is stated that an average of 18.5 perforators emerged from the radial artery.<sup>[23]</sup> During the flap harvest, all perforators were sacrificed except the perforator of the flap skin. Each perforator on the skin communicates with one another.<sup>[23]</sup> Thanks to this communication, the circulation in the skin island parts fed by the sacrificed branches is provided

by the neighboring vessels. In endoscopic pedicle dissection, a longitudinal skin incision is not performed on the forearm, and these connections among the vessels under the skin are not cut. In addition, there are no wounds and/or healing problems in the longitudinal incision or T-junction area as seen with the conventionally harvested radial forearm flap.

The perforators that nourish the lateral cutaneous antebrachial nerve (LACN) arise from the radial artery.<sup>[24]</sup> It is thought that one of the reasons see more complications related to this nerve compared to medial antebrachial cutaneous (MACN) in the early period is the sacrifice of these perforators and the compression of the nerve during the dissection of the cephalic vein due to its proximity.

The cubital fossa has a complex anatomy. There are many variations of the superficial veins in this region.<sup>[25]</sup> In 82% of cases, the cephalic and basilic veins are connected obliquely with the median cubital vein.<sup>[25]</sup> Here, the cephalic vein and its branches, the accessory cephalic and radial vein, surround the radial artery.<sup>[25]</sup> The LACN is adjacent to the cephalic vein in this region.<sup>[24,25]</sup> The median cutaneous nerve passes either superficially or deep to the median cubital vein in 83% of cases.<sup>[25]</sup> Another feature of the median cutaneous vein is that it has the least valve concentration (4%) among the superficial veins in the arm, and all of these valves are on the ulnar side of the vein.<sup>[25]</sup> Van Kouwenberg et al., added the cephalic vein to the flap in endoscopic radial forearm flap harvesting if it was unfavorable to the concomitant vein anastomosis and revised the skin island design accordingly.<sup>[1]</sup> In their four-case series, Kim et al. ligated the cephalic vein.<sup>[6]</sup> It is advocated that the inclusion of the median cubital vein and its branch of the cephalic vein in the flap for two reasons: The cephalic vein has lengthened, and, in case of a diameter mismatch, it is possible to enlarge the diameter by either using the median cubital vein/cephalic vein branch or by cutting it from the bifurcation and this problem has been resolved.

Several important structures are in close proximity in the cubital fossa. With a small skin incision made in this region, the vein structures and nerve structures in this region can be dissected easily and safely. The ulnar artery can be suspended from this incision with a vascular suspender and can be secured. In addition, in endoscopic dissection, the adventitia dissection may be completed with the help of this incision before ligating the vessels. This maneuver may prevent possible vascular injury because while its separation from the vascular bed, it may contract and the dissection of the adventitia in the recipient area may become more challenging.

The flap is separated from its vascular axis and carried to the recipient site at the last step of flap harvest during both conventional and endoscopic radial forearm flap harvest. The ischemia time begins after the ligation of the pedicle. The endoscopic flap dissection involves the steps before the ligation of the pedicle and this technique does not have any effect on ischemia time.

The retrospective design, the low number of cases, the non-homogeneous patient groups, the requirement of special types of equipment, the steep learning curve, the limited exposure, and the cubital fossa scarring may be regarded as the limitations of this study. Prospective and comparative studies with large case series and experienced surgeons may further develop this new technique.

## CONCLUSION

With endoscopic radial forearm flap harvesting, the longitudinal incision in the forearm is avoided. Wound healing problems due to this incision do not occur in the early period, and scarring does not occur in the long term. With a small incision made in the cubital fossa, important structures in the cubital fossa can be preserved; venous structures and their branches that were suitable for anastomosis were included in the flap. In addition, with the help of this incision, adventitia dissection can be performed before the transaction of the vessels. The absence of partial or total flap loss has shown that endoscopic harvesting of the radial forearm flap is a safe and reliable method.

**Ethics Committee Approval:** This study was approved by the Acibadem University Ethics Committee (Date: 13.07.2023, Decision No: 2023-11/379).

**Peer-review:** Externally peer-reviewed.

**Authorship Contributions:** Concept: M.S., E.G., A.C.Ö., E.K.; Design: M.S., E.G., A.C.Ö., E.K.; Supervision: M.S., E.G., A.C.Ö., E.K.; Resource: M.S., E.G., A.C.Ö., E.K.; Materials: M.S., E.G., A.C.Ö., E.K.; Data collection and/or processing: M.S., E.G., A.C.Ö., E.K.; Analysis and/or interpretation: M.S., E.G., A.C.Ö., E.K.; Literature search: M.S., E.G., A.C.Ö., E.K.; Writing: M.S., E.G., A.C.Ö., E.K.; Critical review: M.S., E.G., A.C.Ö., E.K.

**Conflict of Interest:** None declared.

**Financial Disclosure:** The author declared that this study has received no financial support.

## REFERENCES

1. Van Kouwenberg EA, Yan A, Patel A, McLaughlin RL, Northrup P, Cintron M, et al. Endoscopic-assisted radial forearm free flap harvest: A novel technique to reduce donor site morbidity. *J Reconstr Microsurg* 2019;35:22–30. [CrossRef]
2. Selvaggi G, Monstrey S, Hoebeke P, Ceulemans P, Van Landuyt K, Hamdi M, et al. Donor-site morbidity of the radial forearm free flap after 125 phalloplasties in gender identity disorder. *Plast Reconstr Surg* 2006;118:1171–7. [CrossRef]
3. Avery CM. Review of the radial free flap: Is it still evolving, or is it facing extinction? Part one: Soft-tissue radial flap. *Br J Oral Maxillofac Surg* 2010;48:245–52. [CrossRef]
4. Loeffelbein DJ, Al-Benna S, Steinsträßer L, Satanovskij RM, Rohleder NH, Mücke T, et al. Reduction of donor site morbidity of free radial forearm flaps: What level of evidence is available? *Eplasty* 2012;12:e9.
5. Zenn MR, Hidalgo DA, Cordeiro PG, Shah JP, Strong EW, Kraus DH. Current role of the radial forearm free flap in mandibular reconstruction. *Plast Reconstr Surg* 1997;99:1012–7. [CrossRef]
6. Kim JY, Kim YK, Lee S, Nam W. Minimization of radial forearm flap donor-site scar using endoscopy and allogeneic dermal matrix. *J Oral Maxillofac Surg* 2018;76:1825.e1–3. [CrossRef]
7. Ahmed A, Visavadia B, Ujam A, Gilhooly M. Minimal-access technique for harvest of the radial forearm flap. *Br J Oral Maxillofac Surg* 2016;54:1136–7. [CrossRef]
8. D'arpa S, Cillino M, Mazzucco W, Rossi M, Mazzola S, Moschella F, et al. An algorithm to improve outcomes of radial forearm flap donor site. *Acta Chir Belg* 2018;118:219–26. [CrossRef]
9. Winslow CP, Hansen J, Mackenzie D, Cohen JJ, Wax MK. Pursestring closure of radial forearm fasciocutaneous donor sites. *Laryngoscope* 2000;110:1815–8. [CrossRef]
10. Sidebottom AJ, Stevens L, Moore M, Magennis P, Devine JC, Brown JS, et al. Repair of the radial free flap donor site with full or partial thickness skin grafts. A prospective randomised controlled trial. *Int J Oral Maxillofac Surg* 2000;29:194–7. [CrossRef]
11. Wax MK, Winslow CP, Andersen PE. Use of allogenic dermis for radial forearm free flap donor site coverage. *J Otolaryngol* 2002;31:341–5.
12. Kolker AR, Coombs CJ, Meara JG. A method for minimizing donor site complications of the radial forearm flap. *Ann Plast Surg* 2000;45:329–31. [CrossRef]
13. Seify H, Jones G, Sigurdson L, Sherif A, Refky M, Bolitho G, et al. Endoscopic harvest of four muscle flaps: Safe and effective techniques. *Ann Plast Surg* 2002;48:173–9. [CrossRef]
14. Iglesias M, Gonzalez-Chapa DR. Endoscopic latissimus dorsi muscle flap for breast reconstruction after skin-sparing total mastectomy: Report of 14 cases. *Aesthetic Plast Surg* 2013;37:719–27. [CrossRef]
15. Ulku CH. Endoscopy-assisted ear surgery for treatment of chronic otitis media with cholesteatoma, adhesion, or retraction pockets. *J Craniofac Surg* 2017;28:1017–20. [CrossRef]
16. Yu YZ, Zou YP, Zou XL. Endoscopy-assisted vitrectomy in the anterior vitreous. *Int J Ophthalmol* 2018;11:506–11.
17. Jackson HT, Kane TD. Advances in minimally invasive surgery in pediatric patients. *Adv Pediatr* 2014;61:149–95. [CrossRef]
18. Shiba K, Iida Y, Numata T. Ipsilateral full-thickness forearm skin graft for covering the radial forearm flap donor site. *Laryngoscope* 2003;113:1043–6. [CrossRef]
19. Juretic M, Car M, Zambelli M. The radial forearm free flap: Our experience in solving donor site problems. *J Craniomaxillofac Surg* 1992;20:184–6. [CrossRef]
20. Hsieh CH, Kuo YR, Yao SF, Liang CC, Jeng SF. Primary closure of radial forearm flap donor defects with a bilobed flap based on the fasciocutaneous perforator of the ulnar artery. *Plast Reconstr Surg* 2004;113:1355–60. [CrossRef]
21. Hui KC, Zhang F, Lineaweaver WC. Z-plasty closure of the donor defect of the radial forearm free flap. *J Reconstr Microsurg* 1999;15:19–21.
22. van der Lei B, Spronk CA, de Visscher JG. Closure of radial forearm free flap donor site with local full-thickness skin graft. *Br J Oral Maxillofac Surg* 1999;37:119–22. [CrossRef]
23. Sham E, Masia JA, Reddy TJ. Vascular analysis of radial artery perforator flaps. *Ann Maxillofac Surg* 2018;8:66–72. [CrossRef]
24. Cegarra-Escolano M, Jaloux C, Poumellec MA, Balaguer T, Baqué P, Bronsard N, et al. Vascularization of the lateral and medial antebrachial cutaneous nerves by cutaneous perforator arteries: An anatomical study. *Hand Surg Rehabil* 2021;40:241–9. [CrossRef]
25. Mikuni Y, Chiba S, Tonosaki Y. Topographical anatomy of superficial veins, cutaneous nerves, and arteries at venipuncture sites in the cubital fossa. *Anat Sci Int* 2013;88:46–57. [CrossRef]

## ORİJİNAL ÇALIŞMA - ÖZ

**Radyal ön kol flebinde endoskop yardımıyla pedikül hazırlanarak donör bölgesindeki iz yükünün azaltılması****Dr. Mehmet Sağır,<sup>1</sup> Dr. Erdem Güven,<sup>1</sup> Dr. Aret Cerci Ozkan,<sup>2</sup> Dr. Erol Kozanoğlu<sup>3</sup>**<sup>1</sup>Özel Maslak Acıbadem Hastanesi, Plastik Rekonstrüktif ve Estetik Cerrahi Kliniği, İstanbul, Türkiye<sup>2</sup>Özel Muayene Hekimi, Plastik Rekonstrüktif ve Estetik Cerrahi, İstanbul, Türkiye<sup>3</sup>İstanbul Üniversitesi, İstanbul Tıp Fakültesi, Plastik Rekonstrüktif ve Estetik Cerrahi Ana Bilim Dalı, İstanbul, Türkiye

**AMAÇ:** Radyal önkol flebi, uzun pedikülü ve ince yapısı ile rekonstrüktif mikrocerrahinin en sık kullanılan fleplerinden birisidir. Ön koldaki donör bölge, fonksiyonel önemi olan ve görünür bir anatomik bölgedir. Bu çalışmada konvansiyonel radial ön kol flep pedikülünün diseksiyonunda endoskop kullanılarak ön kolda uzunlamasına ve büyük bir izin kalmasının önüne geçildi. Ayrıca flep başarısızlığını ve donör saha morbiditesini azaltmak için kübital fossada 2-3 santimetrelik ayrı bir insizyon yapılarak arteriyel, venöz ve sinir yaralanmaları önlendi.

**GEREÇ VE YÖNTEM:** Bu çalışmaya 2014-2021 yılları arasında baş-boyun bölgesi rekonstrüksiyonunda radial ön kol flebinin pedikül diseksiyonu için endoskop kullanılan hastalar dahil edildi. Flep subfasyal plandan kaldırıldı. Sefalik ven bütün hastalarda kullanıldı. Pedikül ve sefalik ven endoskop yardımıyla diseke edildi. Pedikül diseksiyonu antekübital bölgeye ulaştığında deriden 2-3 cm'lik bir kesi yapıldı. Her hasta için iki ven anastomozu yapıldı.

**BULGULAR:** Bu retrospektif çalışma 51 hastadan oluşmaktadır. 45 hastada baş boyun bölgesi kanser cerrahisine, 6 hastada ise travmaya bağlı defekt vardı. Cilt adasının boyutu ortalama 40.3 cm<sup>2</sup> iken deri greftinin alanı ortalama 24.2 cm<sup>2</sup> idi. Antekübital bölgede iz ortalama 2.6 cm idi. Ameliyat sonrası dönemde venöz veya arteriyel dolaşım bozukluğu gözlenmedi. Hiçbir hastada kısmi veya tam flep kaybı olmadı. Altı (%11.7) hastada radial sinirin yüzeysel duyu dalının olduğu cilt bölgesinde lokalize uyuşma devam etti.

**SONUÇ:** Endoskopik radyal önkol flebi ile ön koldaki uzunlamasına kesinin ve bu bölgedeki yara iyileşme problemlerinin önüne geçilmektedir. Kısmi veya tam flep kaybının olmaması, radyal önkol flebinin endoskopik olarak çıkarılmasının güvenli ve güvenilir bir yöntem olduğunu göstermiştir.

**Anahtar sözcükler:** Baş boyun bölge rekonstrüksiyonu; endoskop; free flep; radyal ön kol flebi; sefalik ven.

Ulus Travma Acil Cerrahi Derg 2023;29(11):1296-1302 DOI: 10.14744/tjtes.2023.62186