

Blunt cardiac injury: case report of salvaged traumatic right atrial rupture

Muna Al Ayyan, M.D., Tanim Aziz, M.D., Amgad El Sherif, M.D., Omar Bekdache, M.D.

Department of Surgery, Tawam Hospital – Johns Hopkins Affiliate - Al Ain, United Arab Emirates

ABSTRACT

The incidence of cardiac rupture following blunt trauma is rare, occurring in 0.3%–0.5% of all blunt trauma patients. It can be fatal at the trauma scene, and is frequently missed in the emergency room setting. The severity of a cardiac trauma is based on the mechanism and degree of the force applied. The objective of this study was to report the case of a 32-year-old male patient who was involved in a motor vehicle collision and presented to the emergency room with signs of hypovolemic shock. The patient was found to have severe chest trauma associated with massive hemothorax requiring immediate intervention. The patient had an emergent thoracotomy revealing a right atrial injury. Repair of the atrial injury reversed the state of shock. The patient was discharged after 35 days of hospitalization in good condition.

Key words: Blunt cardiac injury (BCI); non-penetrating cardiac injuries; traumatic atrial rupture.

INTRODUCTION

Traumatic thoracic injuries are a leading cause of death. The incidence of cardiac rupture following blunt trauma is rare, occurring in 0.3%–0.5% of all blunt trauma patients. It can be fatal at the trauma scene, and is frequently missed in ER setting. The severity of a cardiac trauma is based on the mechanism and degree of the force applied.^[1–4] Prompt diagnosis and treatment can improve chances of survival.

CASE REPORT

In this study, the case of a 32-year-old man who sustained blunt cardiac injury secondary to motor vehicle collision was reported. The patient was a non-restrained driver and was brought to the emergency room with signs of hypovolemic shock. Initial evaluation of the chest showed right sided flail chest and hemothorax requiring drainage. Clinically, no signs of tension pneumothorax or cardiac tamponade were ob-

served. Abdominal exam was within normal limits and Focused Assessment Sonography for Trauma ‘FAST’ scan was negative. Immediately after chest tube insertion, 1.7 liter of fresh blood was drained. The patient was vigorously resuscitated with blood products and IV fluids and was rushed to the operating theater for an emergent thoracotomy.

A right posterolateral thoracotomy was quickly performed. After entering the thoracic cavity, a paraesophageal posterior mediastinal hematoma was encountered, which was associated with severe multiple right lung contusions and multiple ribs fractures with sharp ends protruding into the pleural cavity. Despite continuous resuscitation, the patient continued to be hemodynamically unstable. Exploration of the mediastinal hematoma was performed, which then revealed the presence of active bleeding coming from a small tear in the pericardium. Further surgical opening of the pericardial tear revealed an injury to the free anterior wall of the right atrium that was actively bleeding with each cardiac contraction. Control was made by the application of a small satinsky clamp (Fig. 1a). The injury was successfully repaired using interrupted 4/0 prolene stitches on pledgets with hemostatic closure resulting in a regain of the hemodynamic stability (Fig. 1b).

The patient was transferred to the intensive care unit for close post-operative care. His hospital stay was remarkable for the development of pneumonia, bilateral pleural effusions, recurrent pericardial effusion, and a left wrist drop secondary to positional compression, all of which were treated with

Address for correspondence: Omar Bekdache, M.D.
Tawam Street 15258 Al Ain, United Arab Emirates
Tel: +971 - 3 - 7677444 E-mail: obekdache@tawamhospital.ae

Quick Response Code



Ulus Travma Acil Cerrahi Derg
2015;21(6):527–530
doi: 10.5505/tjtes.2015.12574

Copyright 2015
TJTES

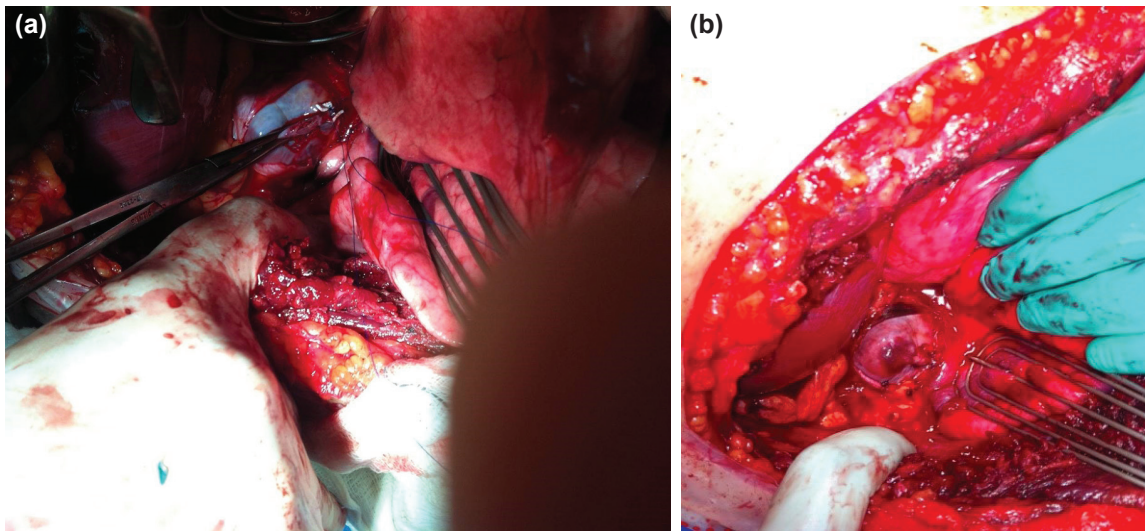


Figure 1. (a) Vascular clamp applied to the atrial rupture area. (b) Complete hemostatic closure suture line.

favorable outcome. The patient was discharged home after thirty-five days in stable condition in terms of his cardiopulmonary status.

DISCUSSION

Traumatic thoracic injuries are infrequently associated with cardiac injuries. Prompt diagnosis and treatment can improve chances of survival by nearly 80% for patients suffering from this type of devastating injury. Unfortunately, there is no universally accepted diagnostic criteria for the assessment of atrial rupture as there has been many documented presentations for such an injury in the literature. The diagnosis of blunt cardiac injury remains difficult due to other associated injuries that divert the physician's attention, as well as the lack of specific physical findings and the lack of specificity of noninvasive tests available in an emergency room for the diagnosis of such an injury.

The mechanism of blunt cardiac injury is often the result of a high-speed impact. The most common source of such an impact is a motor vehicle collision; however, bicycle crashes, falls, blast injuries, sports related injuries, and assaults can all result in blunt injury to the heart. Blunt trauma can also cause secondary penetrating cardiac injury, which can be seen when a sternal fracture results in right ventricular perforation, or fractured ribs lacerating the right or left ventricle.^[3,5-8]

The right heart is the most common site of blunt cardiac injury. Concurrent injuries to more than one chamber has been documented in over 50% of blunt cardiac injury patients. Of those patients who experience rupture of a cardiac chamber, only a small fraction reaches the emergency room alive.^[9-16] Initial evaluation of the patients at risk for blunt cardiac injury should include an appropriate history and physical exam, combined with obtaining a chest radiograph and a 12-lead Electrocardiogram. A 24-hour period of observation, which

includes electrocardiogram telemetry, should be employed if the patient suspected to have blunt cardiac injury is hemodynamically stable and has one of the following: an abnormal electrocardiogram, an age greater than 55 years or history of cardiac disease. If the patient is suspected to have blunt cardiac injury, has any unexplained hypotension or evidence of cardiac dysfunction, the patient should be admitted to an intensive care unit. There is no clear evidence about the role of cardiac enzymes in patients with blunt cardiac injury.^[14,19]

Electrocardiogram changes that correspond to clinically significant blunt cardiac injury are usually present at the time of admission. These changes; however, are occasionally detected after admission, but usually within the first 24 hours after injury. The findings are usually nonspecific, since similar changes occur in the setting of several metabolic abnormalities associated with significant trauma, such as hypoxia, hypovolemia, acidosis, and electrolyte imbalances.^[13-18]

Multiple studies have shown that cardiac enzymes lack the specificity for the risk of developing complications secondary to blunt cardiac injury. More recently, cardiac Troponin I (cTnI) and cardiac Troponin T (cTnT) have been used to screen for blunt cardiac injury. The specificity of both cTnI and cTnT for blunt cardiac injury (BCI) is greater than CPK and CK-MB, since neither cTnI nor cTnT is released with skeletal muscle injury. The sensitivity of cTnI and cTnT may not exceed CPK and CK-MB; however, the specificity was 97% and 100%, respectively.^[8,9,12-16]

Echocardiography plays an important role in the assessment of cardiac function after blunt cardiac injury. Additionally, echocardiography assists in the diagnosis of non-cardiac injuries, including aortic rupture, intracardiac thrombi, pericardial effusion, and pleural effusion. Unfortunately, echocardiography has little utility as a screening test for clinically significant blunt cardiac injury in the hemodynamically stable patient.

[11,19] It is worth mentioning that the experience of a general surgeon who works in a hospital lacking surgical cardiovascular section plays a vital role in order to evaluate and determine the proper treatment for patients experiencing cardiac and/ or vascular issues.^[20]

There are only few studies that have evaluated the long-term effects of blunt cardiac injury. These studies have shown that long term cardiac function is not affected. Lindstaedt et al. have demonstrated in their prospective study of 118 patients with blunt thoracic injury that blunt cardiac injury was identified in only 14 patients using a combination of echocardiographic, cardiac enzyme, and electrocardiographic criteria. Echocardiographic hypokinesis or akinesis was detected in 13 patients during hospitalization for their injuries. None of the blunt cardiac injury patients required treatment for a complication related to their cardiac injury. Follow-up electrocardiography, echocardiography, and a bicycle ergometry evaluated the patients 3 and 12 months after injury. Three of the 14 patients with blunt cardiac injury were lost to follow. One patient was found to have a left ventricular thrombus 12 months after injury. Echocardiographic evidence of akinesis or hypokinesis was present in only 4 out of 11 patients at 1-year follow-up. These results appear to indicate that blunt cardiac injury patients who do not develop acute complications will have acceptable cardiac function within the first year of their injury.^[21,22]

A study of nearly 10,000 trauma patients admitted to the Shock Trauma Center of the Maryland Institute for Emergency Medical Systems with blunt trauma showed an incidence of 0.14% for right atrial rupture. Once cardiac rupture is suspected, surgical management is indicated. Although some centers advocate emergency department thoracotomy rather than subxiphoid approach for decompression of possible traumatic cardiac tamponade, some centers recommend subxiphoid pericardial drainage in the emergency room in patients who only have little chance to survive without any intervention, such as a cardiac arrest patient with a pericardial effusion. When cardiac injuries are first identified on exploratory thoracotomy for a massive haemothorax, shifting to median sternotomy should be performed without hesitation if the visualization is limited and surgical assistance is difficult. Onan et al. have recruited 104 patients over 10 years suffering thoracic traumatic injuries. They have found that overall morbidity is approximately 43.2%. They have noted that atelectasis is the first cause of morbidity followed by respiratory failure. The overall mortality was approximately 18%, which is eventually affected by the hemodynamic stability of the patient and their timing.^[23]

In our case, the pericardium was luckily injured and opened to the mediastinal pleura leading to the decompression of the continuously accumulating cardiac tamponade venting into the right chest and helping in maintaining an acceptable cardiac activity. The wide right posterolateral thoracotomy

exposed the right cardiac chambers appropriately leading to the successful repair of the injury and the favorable outcome.

Patients with cardiac rupture who arrive to the emergency department with persistent vital signs belong to a selective group who has a chance of survival. It should be as well kept in mind the rarity of such injuries and the need of education of such cases to the emergency department personnel as well as the trauma team due to the very high mortality rate. The first step in managing these injuries is to have a high index of suspicion. Although adjuncts such as electrocardiograms, echocardiogram and cardiac markers are helpful, they do not provide definite diagnosis at the trauma bay. These tests can be performed in a hemodynamically stable patient, but those unstable with a higher suspicion of blunt cardiac injury would preferentially be operatively assessed. Immediate, adequate, and safe surgery is also very important for the success of the management of such a rare injury.

Conflict of interest: None declared.

REFERENCES

1. Fujiwara K, Naito Y, Komai H, Yokochi H, Enomoto K, Shinozaki M. Right atrial rupture in blunt chest trauma. *Jpn J Thorac Cardiovasc Surg* 2001;49:476–8. [CrossRef](#)
2. Martin TD, Flynn TC, Rowlands BJ, Ward RE, Fischer RP. Blunt cardiac rupture. *J Trauma* 1984;24:287–90. [CrossRef](#)
3. Fulda G, Brathwaite CE, Rodriguez A, Turney SZ, Dunham CM, Cowley RA. Blunt traumatic rupture of the heart and pericardium: a ten-year experience (1979-1989). *J Trauma* 1991;31:167–73. [CrossRef](#)
4. Perchinsky MJ, Long WB, Hill JG. Blunt cardiac rupture. The Emanuel Trauma Center experience. *Arch Surg* 1995;130:852–7. [CrossRef](#)
5. Parmley LF, Manion WC, Mattingly TW. Nonpenetrating traumatic injury of the heart. *Circulation* 1958;18:371–96. [CrossRef](#)
6. Scorpio RJ, Wesson DE, Smith CR, Hu X, Spence LJ. Blunt cardiac injuries in children: a postmortem study. *J Trauma* 1996;41:306–9. [CrossRef](#)
7. Patetsios P, Priovolos S, Slesinger TL, Sclafani SJ, O'Neill PA. Lacerations of the left ventricle from rib fractures after blunt trauma. *J Trauma* 2000;49:771–3. [CrossRef](#)
8. Sutherland GR, Driedger AA, Holliday RL, Cheung HW, Sibbald WJ. Frequency of myocardial injury after blunt chest trauma as evaluated by radionuclide angiography. *Am J Cardiol* 1983;52:1099–103. [CrossRef](#)
9. Prêtre R, Chilcott M. Blunt trauma to the heart and great vessels. *N Engl J Med* 1997;336:626–32. [CrossRef](#)
10. Schultz JM, Trunkey DD. Blunt cardiac injury. *Crit Care Clin* 2004;20:57–70. [CrossRef](#)
11. Karalis DG, Victor MF, Davis GA, McAllister MP, Covalesky VA, Ross JJ Jr, et al. The role of echocardiography in blunt chest trauma: a transthoracic and transesophageal echocardiographic study. *J Trauma* 1994;36:53–8. [CrossRef](#)
12. Kato K, Kushimoto S, Mashiko K, Henmi H, Yamamoto Y, Otsuka T. Blunt traumatic rupture of the heart: an experience in Tokyo. *J Trauma* 1994;36:859–64. [CrossRef](#)
13. Paone RF, Peacock JB, Smith DL. Diagnosis of myocardial contusion. *South Med J* 1993;86:867–70. [CrossRef](#)
14. Foil MB, Mackersie RC, Furst SR, Davis JW, Swanson MS, Hoyt DB, et al. The asymptomatic patient with suspected myocardial contusion. *Am J Surg* 1990;160:638–43. [CrossRef](#)
15. Potkin RT, Werner JA, Trobaugh GB, Chestnut CH 3rd, Carrico CJ,

- Hallstrom A, et al. Evaluation of noninvasive tests of cardiac damage in suspected cardiac contusion. *Circulation* 1982;66:627–31. [CrossRef](#)
16. Healey MA, Brown R, Fleischer D. Blunt cardiac injury: is this diagnosis necessary? *J Trauma* 1990;30:137–46. [CrossRef](#)
17. Walsh P, Marks G, Aranguri C, Williams J, Rothenberg SJ, Dang C, et al. Use of V4R in patients who sustain blunt chest trauma. *J Trauma* 2001;51:60–3. [CrossRef](#)
18. Mooney R, Niemann JT, Bessen HA, Mena I, French S, Laks MM. Conventional and right precordial ECGs, creatine kinase, and radionuclide angiography in post- Ann Emerg Med 1988;17:890–4. [CrossRef](#)
19. Cachecho R, Grindlinger GA, Lee VW. The clinical significance of myocardial contusion. *J Trauma* 1992;33:68–73. [CrossRef](#)
20. Kamalı S, Aydın MT, Akan A, Karatepe O, Sarı A, Yüney E. Penetrating cardiac injury: factors affecting outcome. *Ulus Travma Acil Cerrahi Derg* 2011;17:225–30. [CrossRef](#)
21. Sturaitis M, McCallum D, Sutherland G, Cheung H, Driedger AA, Sibbald WJ. Lack of significant long-term sequelae following traumatic myocardial contusion. *Arch Intern Med* 1986;146:1765–9. [CrossRef](#)
22. Lindstaedt M, Germing A, Lawo T, von Dryander S, Jaeger D, Muhr G, et al. Acute and long-term clinical significance of myocardial contusion following blunt thoracic trauma: results of a prospective study. *J Trauma* 2002;52:479–85. [CrossRef](#)
23. Onan B, Demirhan R, Öz K, Onan IS. Cardiac and great vessel injuries after chest trauma: our 10-year experience. *Ulus Travma Acil Cerrahi Derg* 2011;17:423–9. [CrossRef](#)

OLGU SUNUMU - ÖZET

Künt kardiyak yaralanma: Tamir edilebilir travmatik sağ atriyal yaralanma olgusu

Dr. Muna Al Ayyan, Dr. Tanim Aziz, Dr. Amgad El Sherif, Dr. Omar Bekdache

Tawam Hastanesi-(Johns Hopkins)- Cerrahi Kliniği, Al Ain, Birleşik Arap Emirlikleri

Künt travma sonrası kardiyak rüptür insidansı nadirdir ve tüm künt travma hastalarının %0.3 ile 0.5'inde görülür. Bu travma olay yerinde ölümcül olabilir ve sık olarak acil servis ortamında tanı atlanabilir. Kardiyak travma şiddeti maruz kalınan kuvvetin şiddeti ve mekanizmasına bağlı olarak değişir. Burada hipovolemik şok belirtileri ile acil servise başvuran, motorlu araç çarpışmasına karışmış, 32 yaşındaki erkek olguyu sunmaktayız. Hastanın göğüs travmasına bağlı acil müdahale gerektiren hemotoraksı olduğu tespit edildi. Hastaya sağ atriyal yaralanmayı ortaya çıkaran acil torakotomi yapıldı. Atriyal yaralanma tamiri hastanın şok durumundan kurtulmasına yardımcı olmuştur. Hasta 35 gün sonra iyi durumda hastaneden taburcu edilmiştir.

Anahtar sözcükler: Künt kardiyak yaralanma; non-penetrant kalp yaralanmaları; travmatik atriyal rüptür.

Ulus Travma Acil Cerrahi Derg 2015;21(6):527–530 doi: 10.5505/tjtes.2015.12574