

# Intraorbital wooden foreign body: clinical analysis of 32 cases, a 10-year experience

Süleyman Taş, M.D., Hüsamettin Top, M.D.

Department of Plastic Reconstructive and Aesthetic Surgery, Trakya University Faculty of Medicine, Edirne

## ABSTRACT

**BACKGROUND:** We aimed to describe herein the clinical features, diagnosis and treatment of intraorbital wooden foreign body injuries.

**METHODS:** A case series review of orbital injuries managed at Trakya University Faculty of Medicine between 2002 and 2012 was performed retrospectively. The clinical analysis of 32 intraorbital wooden foreign body injuries was reviewed.

**RESULTS:** Among the 32 cases, injuries in 16 were caused by a tree branch, in 10 by a pencil, in 5 by a stick, and in 1 by a bush. With respect to preoperative vision, postoperative vision was improved in 69% of patients. Time lapse from injury to presentation was correlated with the size of the foreign body. The subjects were comparable in etiological factor; and distribution of injury according to orbit was as follows: superior 28%, medial 25%, lateral 22%, inferior 16%, and posterior 9%. Computerized tomography (CT) for foreign body was definitive in 72% (n=23) and suggestive in 28% (n=9).

**CONCLUSION:** The diagnosis of orbital wooden foreign body is difficult because it may be missed clinically and from the imaging perspective. If a foreign body is suspected, optimal patient management should be done. Prior to the surgery, imaging modalities should be maximally utilized. A careful preoperative evaluation, imaging studies, which are event-specific, a high index of suspicion, and rigorous surgery and postoperative care are the keys in the management of orbital wooden foreign body injuries.

**Key words:** Foreign body; orbit; trauma; wooden.

## INTRODUCTION

Intraorbital foreign bodies (IOFBs) are a global injury and occur with a frequency of one in six orbital injuries.<sup>[1]</sup> However, a wood FB is uncommon.<sup>[2]</sup> Intraorbital wooden foreign bodies (IOWFBs) carry the risk of damaging the orbital contents, intracranial extension due to the conical shape of the orbit, and infection.<sup>[3]</sup>

For various reasons, the diagnosis and management of IO-WFBs are difficult. The history and external signs of injury are often scant or absent (e.g. conjunctiva entry), and the FB

may be missed by imaging modalities.<sup>[4]</sup> Most entry points of IOWFBs are the eyelids and conjunctiva, and these occasionally may be quite small and hard to determine even with lamp examination.<sup>[4]</sup> In many studies, there is a long delay between injury and presentation. Moreover, the first injury may have been forgotten and received different diagnoses.<sup>[4,5]</sup>

Most of what is known about IOWFB has been gleaned from case reports. As the present study is the largest series in the literature, we aimed to present our clinical experience with respect to the clinical features, diagnosis, treatment, and results in IOWFBs, in an effort to facilitate an algorithm for their treatment.

## MATERIALS AND METHODS

This study was performed under an institutional ethics review board-approved protocol. We conducted a retrospective chart review of 32 patients who admitted to Trakya University Faculty of Medicine and were diagnosed with IO-WFB from 2002 through 2012. Medical records of all patients included patient history, clinical examination and evaluation, mechanism and location of injury, and nature of the FB. For each case, we determined the preoperative findings (age,

Address for correspondence: Süleyman Taş, M.D.

Trakya Üniversitesi Tıp Fakültesi, Plastik Rekonstrüktif ve Estetik Cerrahi Anabilim Dalı, Edirne, Turkey

Tel: +90 284 - 236 09 09 E-mail: drsuleymantas@live.com

Quick Response Code



Ulus Travma Acil Cerr Derg  
2014;20(1):51-55  
doi: 10.5505/tjtes.2014.93876

Copyright 2014  
TJTES

sex, characteristic of trauma, preoperative vision acuity, time lapse from injury to presentation) and postoperative findings (results of wound cultures, response to antibiotic therapy, type of imaging modality, postoperative vision acuity, complications). We compared the complications, results and long-term follow-up. Written informed consents were obtained from the patients. This study adhered to the principles of the Declaration of Helsinki.

## RESULTS

The results are summarized in Table 1. There were 32 cases, and the majority were male (75%, n=24). The mean age was 21 years (range, 4-52 years). The distribution of FB was as follows: tree branch (50%, n=16), pencil (31%, n=10), stick (16%, n=5), and bush (3%, n=1).

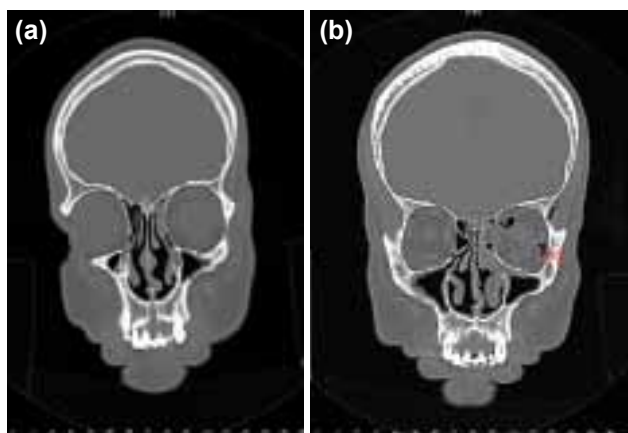
Preoperative vision ranged between 20/50 and 20/400 in 31% (n=10) of the patients (with injured globe) and remained the same postoperatively. In 13% (n=4) of the patients (with injured globe), preoperative vision ranged between counting fingers (CF) to light perception (LP) and improved to 20/400 postoperatively. In 56% (n=18) of the patients (with intact globe), vision ranged between 20/20 and 20/40 and increased postoperatively. None of the patients demonstrated worsened visual acuity after surgery.

The time lapse from injury to presentation (range, 3 hours-22 months; mean, 54 days) was correlated with the size of the FB (first 72 hours for >2 cm, after 72 hours <2 cm). However, 69% (n=22) of patients presented within 72 hours of the injury. The initial visual acuity was associated with presentation lag.

**Table 1.** Summary of preoperative status and postoperative outcomes

Etiology	n	Type of foreign body	Site of injury	Preop vision acuity	Postop vision acuity	Size of foreign body	Presentation time after injury
Woodsman	16	Tree branch (50%)	n=3 medial, 19%	20/20 to 20/40	Improved	Range: 1-5 cm	5 hours to 2 years
			n=4 superior, 25%	n=10	11	>2 cm, n=11	first 72 hours, n=9
			n=2 posterior, 12%	20/50 to 20/400	No change	<2 cm, n=5	11 days to 22 months, n=7
			n=3 lateral, 19%	n=5	5		
	10	Pencil (31%)	n=5 medial, 46%	CF to LP n=1 20/20 to 20/40	Worsened 0 Improved		
Fall			n=4 superior, 36%	n=6	7	Range: 4-6 cm	3 hours to 1 year
			n=1 posterior, 9%	20/50 to 20/400	No change	>2 cm, n=10	3 hours to 14 days, n=9
	1	Bush (3%)	n=1 inferior, 9%	n=4	4	<2 cm, n=1	30 days to 1 year, n=2
Physical assault	5	Stick (16%)	n=5 lateral, 100%	20/20 to 20/40	Improved	Range: 3-5 cm	4 hours to 26 hours
				n=2	4	>2 cm, n=5	4 hours to 26 hours, n=5
				20/50 to 20/400	No change	<2 cm, n=0	After 26 hours, n=0
Total	32		25% medial	20/20 to 20/40, 56%	69% improved	81% >2 cm	69% first 72 hours
			28% superior	20/50 to 20/400, 31%	31% No change	19% <2 cm	31% after 72 hours
			9% posterior	CF to LP, 13%	0% Worsened		
			22% lateral 16% inferior				

CF: Counting fingers; LP: Light perception.



**Figure 1.** (a) Preoperative image in normal setting and soft tissue window: the IOWFB is not recognizable. (b) In bone window, with the setting of 4000 HU width, 400 HU level, the IOWFB (red arrows) can be demonstrated easily.

The location of periocular trauma was distributed according to the etiological factor and presented in superior (28%), medial (25%), lateral (22%), inferior (16%), and posterior (9%) orbits. In all cases, computerized tomography (CT) studies were performed. The radiologist recognized IOWFB in 72% of subjects and noted possible FB in 28% of subjects. In these patients, the radiologist requested magnetic resonance imaging (MRI) for two cases and encouraged investigation of the possibility of IOWFB (Figure 1a, b).

In 66% of subjects (n=21), wound cultures were taken during the operation, and many species were isolated, including *Staphylococcus epidermidis*, *Staphylococcus aureus*, *Enterobacter agglomerans*, and *Clostridium perfringens*. There was no particular predominant species. No mycobacterium or fungus was isolated, even when specific cultures were done. The majority of subjects (62%, n=20) were treated with intravenous antibiotics on admission.

The treatment approach in all cases was empiric antibiotic therapy (ampicillin-sulbactam), immediate removal of the FB, acquisition of wound culture, adequate debridement, primary

wound closure, and final antibiotic agent based on wound culture results.

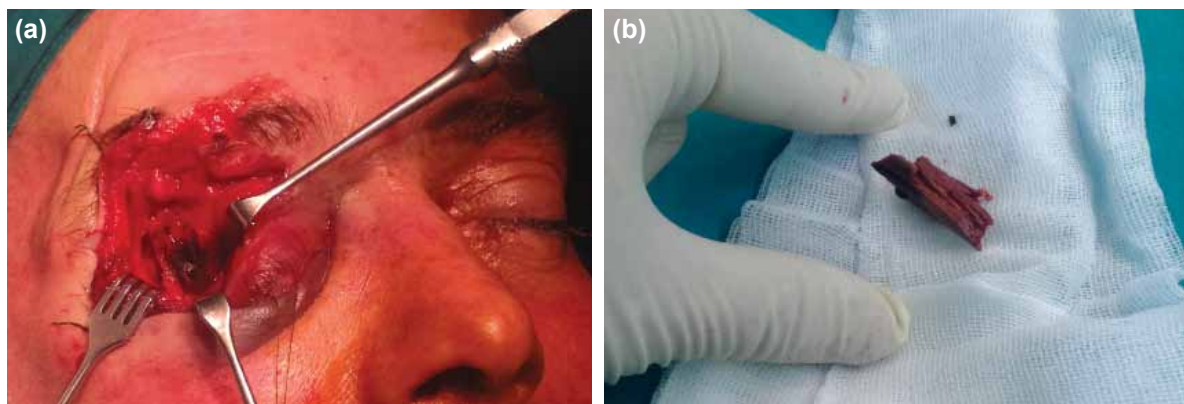
The upper lid injuries postoperatively included ptosis in 9% (n=3) of subjects, and these cases had a tissue defect of the upper lids (Figure 2a, b). Strabismus surgery was necessary postoperatively in one patient (3%).

## DISCUSSION

As our region is in close proximity to the forest and many people are woodsmen by profession, accidents occurring while cutting trees are encountered frequently, including IO-WFBs, due to the habit of not wearing protective masks. This explains the high number of cases of IOWFB seen in our institution, although such cases are rare in the literature.

The diagnosis of IOWFB can be difficult due to the sometimes negligible external signs of injury and the late presentation after the injury. Some authors have argued that management of such cases should be conservative and that surgical exploration should be done only in the case of complication.<sup>[6]</sup> However, we recommend surgical removal of the FB because organic materials carry a high risk of infection.<sup>[2-4]</sup> In clinical practice, we encountered late presentation cases with a complication (e.g., abscess formation, fistula, granuloma). To our knowledge, there has been no study demonstrating the complications rate when conservative treatment is chosen.

Infection risk increases with organic FBs, regardless of the anatomic site.<sup>[4]</sup> Because of the possibility of rapid progression of infection in the orbital area, empiric antibiotic therapy is advised.<sup>[4]</sup> If there is a suspicion of intracranial penetration, the empiric antibiotic therapy should include a third-generation cephalosporin and vancomycin.<sup>[4,7]</sup> Though we did not encounter any intracranial penetration, as a rule, FB removal should not be attempted until sufficient imaging has been performed. Consistent with our study, the previous studies have shown no predominant organism. However, cocci, rods, and anaerobes were predominant (*S. epidermidis*, *S. aureus*, *E. ag-*



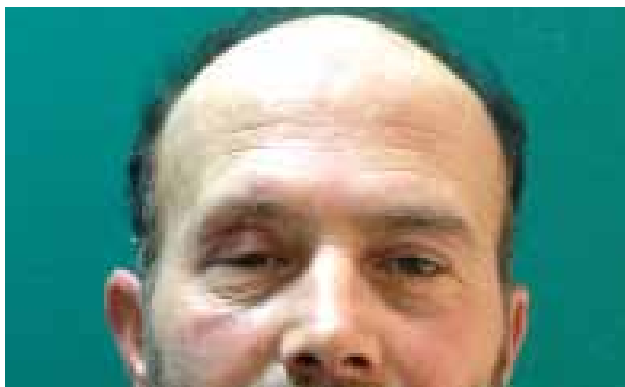
**Figure 2.** (a) Intraoperative IOWFB was explored. (b) A 4 cm wooden piece was removed.

*glomerans*, *C. perfringens*).<sup>[2,8,9]</sup> Fungal organisms do not play a significant role in IOWFB.<sup>[2]</sup>

Imaging of IOWFB is complex with respect to modality (plain X-ray, ultrasonography [USG], CT, MRI), hydration of the wood (dry vs. fresh), type of wood (soft vs. hard), size of wood, and wood treatments (preservatives, paint). In the prior studies, these subjects have been investigated extensively, and the outcomes and suggestions are substantial for reviewing. Plain X-ray does not work for viewing IOWFB because it is hard to visualize wood with this modality.<sup>[10,11]</sup> USG has a very limited role as it requires expertise and is not reliable for imaging the orbital apex.<sup>[10,12]</sup> Moreover, it can image the proximity of the orbital cavity in the absence of orbital imaging. CT and MRI are the available modalities for the diagnosis of IOWFB. However, these modalities have limitations and require fine-tuning to maximize their diagnostic potential.

In the literature, it is reported that standard CT image is not an appropriate method for showing acute IOWFB due to the possibility of its mimicking air images.<sup>[13]</sup> However, bone window with parameters of 4000 HU width/400 HU level and simultaneous axial and coronal imaging is certainly more effective for detecting IOWFB (Fig. 3).<sup>[13,14]</sup> Thus, CT is currently the gold standard for detecting IOWFB with its additional advances over the other imaging modalities (i.e., cheaper, more available, fast result, suitable in children). However, it is important that radiologists be informed regarding the width and level settings when there is a suspicion of IOWFB.<sup>[2]</sup>

Magnetic resonance imaging (MRI) in certain settings may be helpful as an adjunct to CT. In T-1-weighted images, the signal from an IOWFB is uniform and more diagnostic than T-2-weighted or proton density images.<sup>[15]</sup> In T-2 images, the signal from an IOWFB is indiscernible from the surrounding soft tissue, independent of its hydration. Further, since T-2 images are obtained over a longer period than T-1 images, the possibility of motion artifact may increase. On T-1 images, the IOWFB is hypointense from surrounding soft tissue, independent of its hydration, although this is not a uniform finding and ring enhancement with gadolinium may be seen initially in some cases.<sup>[15,16]</sup> In our series, in line with these rec-



**Figure 3.** Postoperative early result: a mild ptosis was observed.

ommendations, we needed MRI images for only two patients at the beginning of the study. As the radiologist's experience increased, CT images were adequate.

Organic FBs are well-known causes of infection, regardless of the anatomical site. In the presence of an intracranial penetration, the management of the infection will be more complicated, and antibiotics, which have good blood-brain barrier penetration, are recommended.<sup>[17-20]</sup> In the current study, we did not experience any such case of an infectious complication, which we attribute to the sufficient debridement and our close consultation with the Infectious Diseases Department and compliance with their recommendations. Our culture results were similar to those in the literature, and no particular dominant organism was identified.

In the literature, no IOWFB with eyelid defect was reported. In our series, we observed three such cases. We repaired the lacerated levator muscle and reconstructed the skin defect with advancement flaps after accurate debridement and irrigation with antibiotic solutions. In these cases, as a fundamental principle, if there is a suspicion of inadequate debridement, a secondary closing should be planned. In these cases, there is risk of ptosis or lagophthalmus due to injury to the levator and Muller's muscles. Thus, in defects of the upper eyelids, care should be given in repairing the levator muscle. Because the majority of the cases were woodsmen, we stress the importance of wearing protective masks in such occupations to avoid these types of injuries.

We observed that young men had the highest risk for IOWFB, as in prior studies (75% had a mean age of 21 years).<sup>[2]</sup> The most common site of IOWFB is not clear in prior case series. In our report, we observed that the site of IOWFB depended on the etiology of the injury. In the woodsmen group, we could not determine the most frequent site because the site changed with changes in the positioning of the electrical saw. In the group suffering a fall, superior and medial orbit were frequent, which can be explained by neck hyperextension as a reflex to prevent the injury.<sup>[17]</sup> In the group that suffered physical assault with a stick, the lateral orbit was frequent (the rarest site in the literature), and again, this could be attributed to turning one's head as a reflex mechanism.

In a prior study, the presentation time after injury was variable (range, 1 day to over 1 year).<sup>[2]</sup> However, we reported that it was compatible with the size of the WFB. The presentation time was <2 days for WFB >2 cm and >2 days for WFB <2 cm. This information is extremely important to anticipate the size of the FB.

In conclusion, satisfactory results can be achieved in IOWFBs in the presence of a careful history and physical examination, CT imaging (with the radiologist well-informed of the optimal settings), a timely exploratory surgery, removal of the

foreign body with a heightened level of attention, postoperative antibiotic prophylaxis, and close consultation with the Infectious Diseases Department. However, this report is the largest series in the literature, and thus more definitive for the clinical features of IOWFBs. We believe it will shed light on the management of IOWFBs.

Conflict of interest: None declared.

## REFERENCES

1. Boncoeur-Martel MP, Adenis JP, Rulfi JY, Robert PY, Dupuy JP, Maubon A. CT appearances of chronically retained wooden intraorbital foreign bodies. *Neuroradiology* 2001;43:165-8. [CrossRef](#)
2. Shelsta HN, Bilyk JR, Rubin PA, Penne RB, Carrasco JR. Wooden intraorbital foreign body injuries: clinical characteristics and outcomes of 23 patients. *Ophthal Plast Reconstr Surg* 2010;26:238-44. [CrossRef](#)
3. Dunn IF, Kim DH, Rubin PA, Blinder R, Gates J, Golby AJ. Orbitocranial wooden foreign body: a pre-, intra-, and postoperative chronicle: case report. *Neurosurgery* 2009;65:383-4. [CrossRef](#)
4. Miller CF, Brodkey JS, Colombi BJ. The danger of intracranial wood. *Surg Neurol* 1977;7:95-103.
5. Herman TE, Shackelford GD, Tychsen L. Unrecognized retention of intraorbital graphite pencil fragments: the role of computerized tomography. *Pediatr Radiol* 1995;25:535-7. [CrossRef](#)
6. Agarwal PK, Kumar H, Srivastava PK. Unusual orbital foreign bodies. *Indian J Ophthalmol* 1993;41:125-7.
7. Roos KL. Principles of neurologic infectious diseases. New York, NY: McGraw-Hill; 2005.
8. Jabaly-Habib HY, Muallm MS, Garzosi HJ. An intraorbital injury from an occult wooden foreign body. *J Pediatr Ophthalmol Strabismus* 2002;39:300-2.
9. Sullivan TJ, Patel BC, Aylward GW, Wright JE. Anaerobic orbital abscess secondary to intraorbital wood. *Aust N Z J Ophthalmol* 1993;21:49-52.
10. Ho VT, McGuckin JF Jr, Smergel EM. Intraorbital wooden foreign body: CT and MR appearance. *AJNR Am J Neuroradiol* 1996;17:134-6.
11. Lagalla R, Manfrè L, Caronia A, Bencivinni F, Duranti C, Ponte F. Plain film, CT and MRI sensibility in the evaluation of intraorbital foreign bodies in an in vitro model of the orbit and in pig eyes. *Eur Radiol* 2000;10:1338-41. [CrossRef](#)
12. Mutlukan E, Fleck BW, Cullen JF, Whittle IR. Case of penetrating orbitocranial injury caused by wood. *Br J Ophthalmol* 1991;75:374-6. [CrossRef](#)
13. Dalley RW. Intraorbital wood foreign bodies on CT: use of wide bone window settings to distinguish wood from air. *AJR Am J Roentgenol* 1995;164:434-5. [CrossRef](#)
14. Yamashita K, Noguchi T, Mihara F, Yoshiura T, Togao O, Yoshikawa H, et al. An intraorbital wooden foreign body: description of a case and a variety of CT appearances. *Emerg Radiol* 2007;14:41-3. [CrossRef](#)
15. Glatt HJ, Custer PL, Barrett L, Sartor K. Magnetic resonance imaging and computed tomography in a model of wooden foreign bodies in the orbit. *Ophthal Plast Reconstr Surg* 1990;6:108-14. [CrossRef](#)
16. Smely C, Orszagh M. Intracranial transorbital injury by a wooden foreign body: re-evaluation of CT and MRI findings. *Br J Neurosurg* 1999;13:206-11. [CrossRef](#)
17. Miller CF, Brodkey JS, Colombi BJ. The danger of intracranial wood. *Surg Neurol* 1977;7:95-103.
18. Mandell GL, Bennett JE, Dolin R, (editors). Principles and practice of infectious disease. 6th ed. Philadelphia, PA: Elsevier Churchill Livingstone; 2005.
19. Nasr AM, Haik BG, Fleming JC, Al-Hussain HM, Karcioğlu ZA. Penetrating orbital injury with organic foreign bodies. *Ophthalmology* 1999;106:523-32. [CrossRef](#)
20. Fulcher TP, McNab AA, Sullivan TJ. Clinical features and management of intraorbital foreign bodies. *Ophthalmology* 2002;109:494-500. [CrossRef](#)

## KLİNİK ÇALIŞMA - ÖZET

### İntraorbital tahta cisim yaralanmaları: Otuz iki olgunun klinik analizi, 10 yıllık deneyim

Dr. Süleyman Taş, Dr. Hüsamettin Top

Trakya Üniversitesi Tıp Fakültesi, Plastik Rekonstrüktif ve Estetik Cerrahi Anabilim Dalı, Edirne

**AMAÇ:** Bu yazıda, intraorbital tahta cisim yaralanmalarının klinik özellikleri, tanı ve tedavi rejimlerini tanımlamak amaçlandı.

**GEREÇ VE YÖNTEM:** 2002 ile 2012 yılları arasında Trakya Üniversitesi Tıp Fakültesine başvuran orbital yaralanmalar geriyeye dönük olarak incelendi. Tespit edilen 32 intraorbital tahta cisim yaralanması değerlendirildi.

**BULGULAR:** Otuz iki yaralanmanın, 16'sı ağaç kabuğu, 10 tanesi kalem, 5 tanesi çubuk, 1 tanesi ise çalidan kaynaklanmaktaydı. Ameliyat öncesi görme keskinliği ameliyat sonrası genellikle arttı (%69). Yaralanma zamanı ile başvuru zamanlaması arasındaki süre, yabancı cismin boyut ile kolere bulundu. Yaralanma lokalizasyonu, yaralanmanın etiyojisi ile ilişkili olup, %28'i superior, %25'i medial, %22'si lateral, %16'sı inferior, %9'u ise posterior orbita yerleşmişti. Bilgisayarlı tomografi olguların %72'sinde tanıda tek başına yeterli iken, kalan %28'inde muhtemel yabancı cisim kanısı verdi.

**TARTIŞMA:** İntraorbital tahta cisim yaralanmalarının tanısı, klinik ve radyolojik olarak fark edilmesi güç olduğundan zordur. Alınan anamnezde eğer bir şüphe varsa, optimal hasta yönetimi gerçekleştirilmelidir. Cerrahi öncesi, görüntüleme yöntemlerinden maksimum faydalanmalıdır. Dikkatli bir ameliyat öncesi değerlendirme ve görüntüleme, yüksek klinik şüphe, titiz cerrahi ve ameliyat sonrası bakım intraorbital tahta cisim yaralanmalarının anahtar noktalarıdır.

**Anahtar sözcükler:** Orbita; tahta; travma; yabancı cisim.

Ulus Travma Acil Cerr Derg 2014;20(1):51-55 doi: 10.5505/tjtes.2014.93876