

Novel use of Lodox® Statscan® in a level one trauma center

Birinci basamak travma merkezinde *Lodox® Statscan®*'in yeni kullanım şekli

**Bardia AMIRLAK,¹ Bishop ZAKHARY,² Katie WEICHMAN,² Hardeep AHLUWALIA,³
Armour R FORSE,⁴ Ray D GAINES⁴**

Trauma continues to be a large source of poor outcomes for patients in the United States. While clinical guise is very important in the acute setting, objective physical data is becoming increasingly important in the diagnosis of many injuries sustained during trauma. Radiography has always been the primary diagnostic modality applied in trauma situations but it continues to be a time-consuming and unwieldy part of the acute resuscitation of the patient. The novel use of the Lodox® Statscan® (Lodox® Systems (Pty), Ltd., Benmore, South Africa), a type of digital radiography, as a means to help combat these problems was evaluated at Creighton University Medical Center, Omaha, Nebraska. This new machine uses a linear beam technology to scan the entire body in 13 seconds. Here, we describe this digital radiography system, its introductory use in the trauma bay, and discuss cases where it has proven valuable. Based upon our preliminary experience, the use of the device in large centers shows promise for improving morbidity and mortality outcomes in trauma patients.

Key Words: Digital imaging; injury; Lodox®; morbidity; mortality; Statscan®; trauma.

Travma, Birleşik Devletler'de hastalarda olumsuz sonuçlara neden olmayı sürdürmektedir. Klinik görünüş akut durumlarda çok önemli olmakla birlikte, nesnel fiziksel veriler, travma sonucu gerçekleşen çoğu yaralanmanın tanısında giderek artan bir önem kazanmaktadır. Radyografi her zaman travma durumlarında uygulanan primer tanı yöntemi olmuşsa da bu yöntem hastanın akut resüsitasyonunun zaman alıcı ve kullanışsız bir ögesi olmayı sürdürmektedir. Bu problemlerle mücadeleye yardım etmek üzere, dijital radyografinin bir tipi olan Lodox® Statscan®'in (Lodox® Systems (Pty), Ltd., Benmore, Güney Afrika) yeni kullanım şekli Creighton Üniversitesi Tıp Merkezi'nde (Omaha, Nebraska) değerlendirildi. Bu yeni araç, baştan sona tüm vücudu 13 saniyede tarayan lineer ışın teknolojisi kullanmaktadır. Burada, dijital radyografi sistemi ve onun travmadaki başlangıç niteliğindeki kullanımı tanımlandı ve yöntemin değerli olduğunun kanıtlandığı olgular tartışıldı. Ön hazırlık niteliğindeki deneyimimiz, buluşun büyük merkezlerde kullanımı, travma hastalarındaki morbidite ve mortalite sonuçlarını düzeltmekte başarılı olacağını göstermektedir.

Anahtar Sözcükler: Dijital görüntüleme; yaralanma; Lodox®; morbidite; mortalite; Statscan®; travma.

Trauma in urban settings is one of the largest definable causes of patient morbidity and mortality. Development of protocols and imaging technology that help decrease the morbidity and mortality of trauma-related injuries is a major area of interest and innovation in today's medical community. However, developments based upon changes in the trauma protocols alone have demonstrated inconclusive effects on morbidity and mortality.^[1-7] On the other hand, innovative computer-based radiographic technology holds promise, if and when combined with particular

focus on the expeditious triage and identification of injuries during the acute resuscitation.^[8]

The Focused Assessment with Sonography for Trauma (FAST) examination is one such radiographic technology in which hand-held ultrasound equipment is used to rapidly assess the abdominal cavity. While the FAST exam has reduced the time spent in identifying intra-abdominal injuries,^[9,10] conventional radiography is still required to detect acute life-threatening injuries such as pneumothorax, aor-

¹Case Western School of Medicine, Cleveland, Ohio;

²New York University School of Medicine, Ny, New York;

³Duke University School of Medicine, Durham, North Carolina;

⁴Creighton University School of Medicine, Omaha, Nebraska, USA.

¹Case Western Tıp Fakültesi, Cleveland, Ohio;

²New York Üniversitesi Tıp Fakültesi, New York;

³Duke Üniversitesi Tıp Fakültesi, Durham, Kuzey Carolina;

⁴Creighton Üniversitesi Tıp Fakültesi, Omaha, Nebraska, ABD.

tic dissection, and cervical spine injuries. As such, the evaluation of the trauma patient continues to be a time-consuming, inefficient, and operator-dependent entity.

Digital radiography is on the horizon as innovative technology that not only decreases the time spent obtaining radiographs but also offers ease of image transmissibility while reducing the dose of radiation delivered. The Lodox® Corporation is the pioneer in the development of such technology and is currently marketing these systems throughout the United States and Europe.

Lodox®'s Statscan® (LS), named for its low-dose of x-ray exposure, is a flexible digital imaging system with anticipated use in a myriad of radiological patients including: trauma, military/ disaster, pediatric, and bariatric. Development of the system takes its roots in South Africa where it was initially used by the De Beers Diamond Company in an effort to detect pirated diamonds hidden in garb and/or swallowed. The goals, therefore, were to develop a scan that was not only cost-effective and expeditious, but also offered low enough doses of radiation so as to be used on a daily basis.^[11,12]

Medical imaging consultants involved in the development of this technology were quick to identify

the digital system's potential for use in emergency and trauma venues. With the help of De Beers Consolidated Mines, Industrial Development Group of South Africa, and Netcare Hospital Management, Lodox® Systems modified the Statscan® for use in trauma bays and emergency departments throughout the world. Our institution was selected to trial evaluate this new machine and further delineate its benefits relative to that of traditional plain radiography.

Protocol

The following algorithm was developed by our trauma team in fitting the LS into the trauma protocol (Table 1).

Case Reports

The following are some cases in which the LS was used at our institution.

Case 1- A 76-year-old male was brought to the trauma bay by the rescue squad following a motor-vehicle accident (MVA) in which the patient was hit on the passenger side. On presentation, his vital signs were stable and a chest X-ray showed multiple left-sided rib and clavicle fractures (Fig. 1a). The patient soon started to decompensate, and required intubation. He was moved to the LS where whole-body imaging revealed a widened mediastinum and frac-

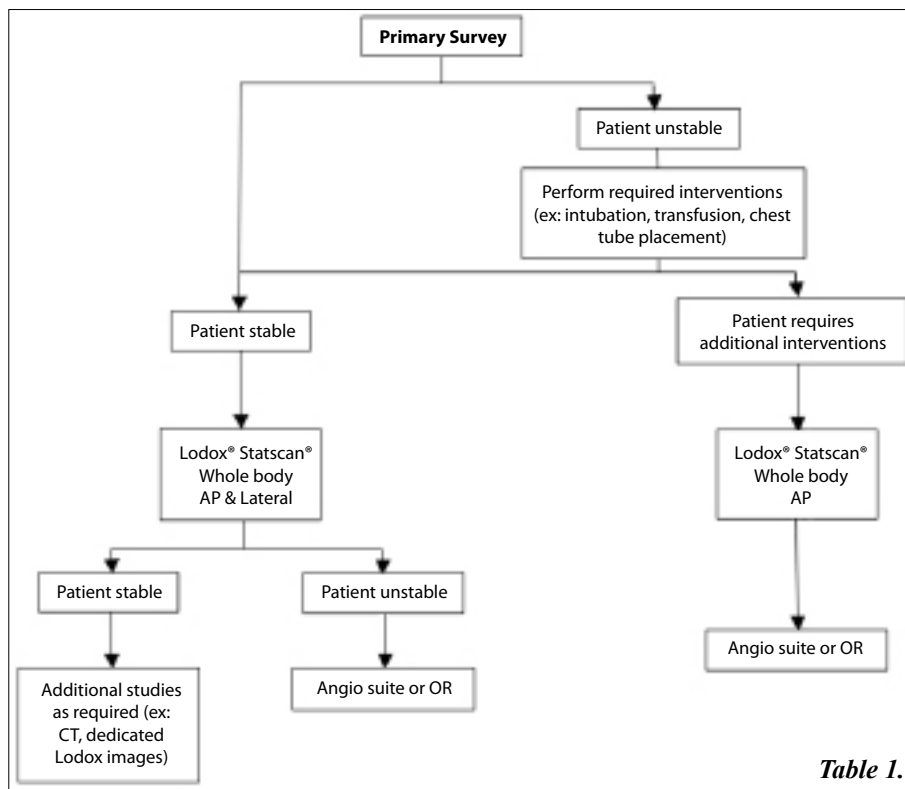


Table 1.

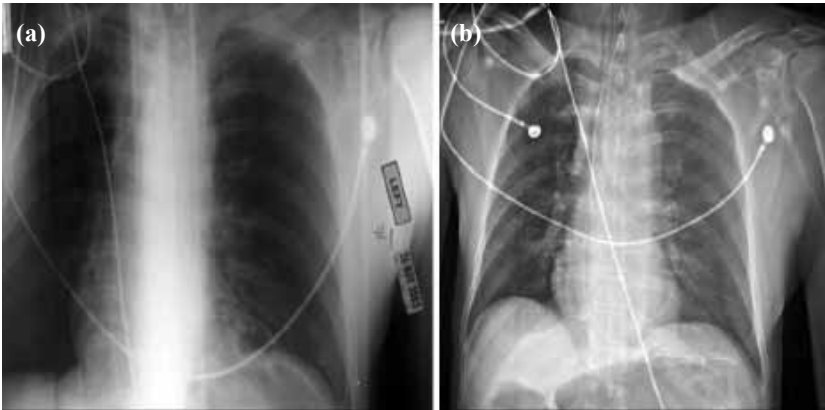


Fig. 1. A 76 year-old male with multiple fractures following a motor vehicle accident. Traditional and Statscan® chest radiographs taken within 10 minutes of each other are presented for comparison. (a) A traditional chest x-ray shows multiple left-sided rib and clavicle fractures. (b) Statscan® imaging reveals the same fractures as well as a widened mediastinum.

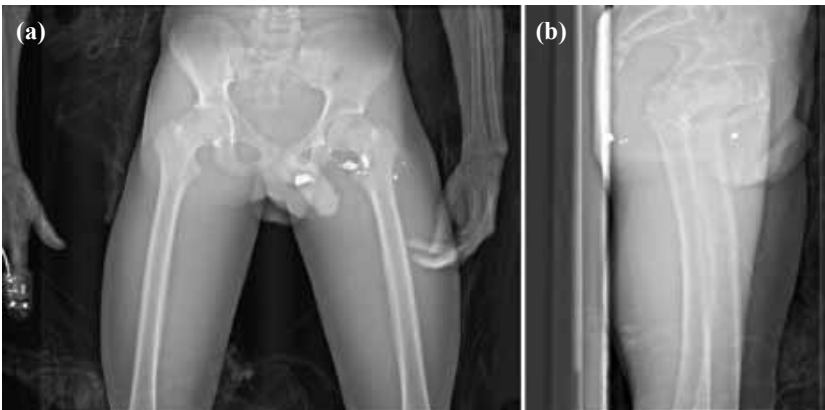


Fig. 2. A 33 year-old male presented to the trauma bay unresponsive following a gun-shot wound. (a) Anteroposterior and (b) lateral Statscan® images localize a bullet fragment near the rectum. On exploratory laparotomy, a perforated rectum was found and repaired.

tures of the left lower extremity (Fig. 1b). The patient was then taken to the operating room (OR), where an exploratory laparotomy and thoracotomy revealed a diaphragmatic injury and right ventricular rupture. Prompt radiographic evidence guided a more rapid response, while whole body imaging aided the identification of additional injuries, otherwise missed on initial assessment. Traditional and Statscan® chest radiographs taken within 10 minutes of each other are presented for comparison.

Case 2- A 33-year-old male was brought to the trauma bay after sustaining a gunshot wound (GSW) to the abdomen. An entry wound was identified in the left lower quadrant but no exit wound was found. The patient had an acute abdomen, and emergent exploratory laparotomy was indicated. An anteroposterior Statscan® image localized the bullet within the left lower quadrant (Fig. 2a). Moreover, on lateral imaging, a bullet fragment was found inferior to the coccyx near the rectum (Fig. 2b). The patient was then taken to the OR for exploratory laparotomy based upon location of the bullet on lateral view. Careful examination of the rectum revealed a small perforation necessitating colostomy placement. This case demonstrates that in unstable patients with missile injury, who require immediate exploration with

little time wasted, further imaging with the Lodox® whole body scan can be obtained. In this case, LS effectively localized the bullet fragment leading to appropriate care of the patient.

Case 3- A 42-year-old female was brought to the trauma bay following a MVA, in which the patient was involved in a head-on collision. The patient was unresponsive, with a Glasgow coma scale (GCS) of 8, requiring intubation at the scene. After the patient was stabilized, she was taken to the LS. The whole body scan revealed a right femur fracture (Fig. 3), which was subsequently repaired in the OR. This case demonstrates that in stable patients who are unresponsive or otherwise unable to localize pain, whole body Statscan® can accurately screen for orthopedic injury.

Discussion

Statscan® is an integrated digital imaging system that is currently being used for most of our trauma patients. Employment of this machine during the 'golden hour' is considered to be the crux of its efficacy.

When patients are transported into the trauma bay, they are immediately placed on the Statscan®'s

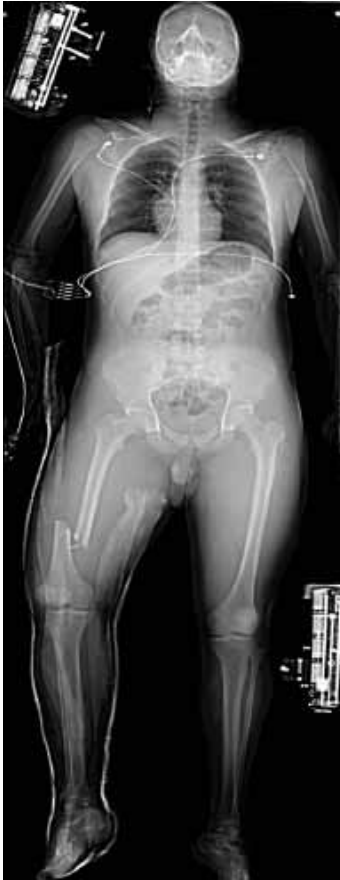

Fig. 3. A 42 year old female involved in a motor-vehicle accident requiring intubation at the scene. After stabilization, whole-body Statscan® imaging revealed a right femur fracture.

unique carbon-fiber gridded table. This table not only provides an effective initial resuscitation unit but also eliminates the need to move patients when obtaining radiological images. This is particularly valuable when suspected spinal injury mandates extra caution. The weight capacity of the carbon-fiber bed far exceeds the capacity of a standard computed tomography (CT) scanner, thereby providing

increased radiological opportunities for bariatric patients. Also of note, the table serves to demarcate the patient's size as quantified by a letter system. This value is subsequently entered into the radiology technologist's control station so that the Statscan®, via a specialized algorithm, provides the optimum dose of radiation.

The Statscan® consists of a unique Arm Scanning and Positioning (ASP) assembly that scans the patient, deploys the X-rays, and subsequently detects the image (Fig. 4a, 4b). The ASP is made up of the Base Frame Unit (BFU), which is mounted on the floor of the trauma bay, and the Support Housing (SH), which forms the ambulatory portion. The BFU contains the linear motor magnets, which work to propel the X-ray tube. Within the SH is the C-arm, which contains the X-ray tube and detector on opposite arms.

The Statscan® technology is dependent on the mobility of the C-arm in order to produce high-quality images. To this end, the C-arm is able to rotate axially 90° around the patient, thereby producing anteroposterior (AP), oblique, and horizontal-beam lateral films. In addition, the C-arm travels along the table at 13.8 cm/second, such that a full body scan can be performed in approximately 13 seconds.

Unlike the traditional radiograph instrument, which dispenses X-rays in a scatter pattern, the Statscan® dispenses a focused X-ray beam that traverses the patient's body in 2 mm slices. Since the machine does not have to work with the negative effects of scatter, a large area scatter reduction grid is not required and lower doses of radiation can be used. This decrease is quite significant, amounting to




Fig. 4. The Lodox® Statscan® machine. (a) The various machine components are labeled. (b) The patient is loaded onto the carbon fiber bed as the C-arm scans the patient.

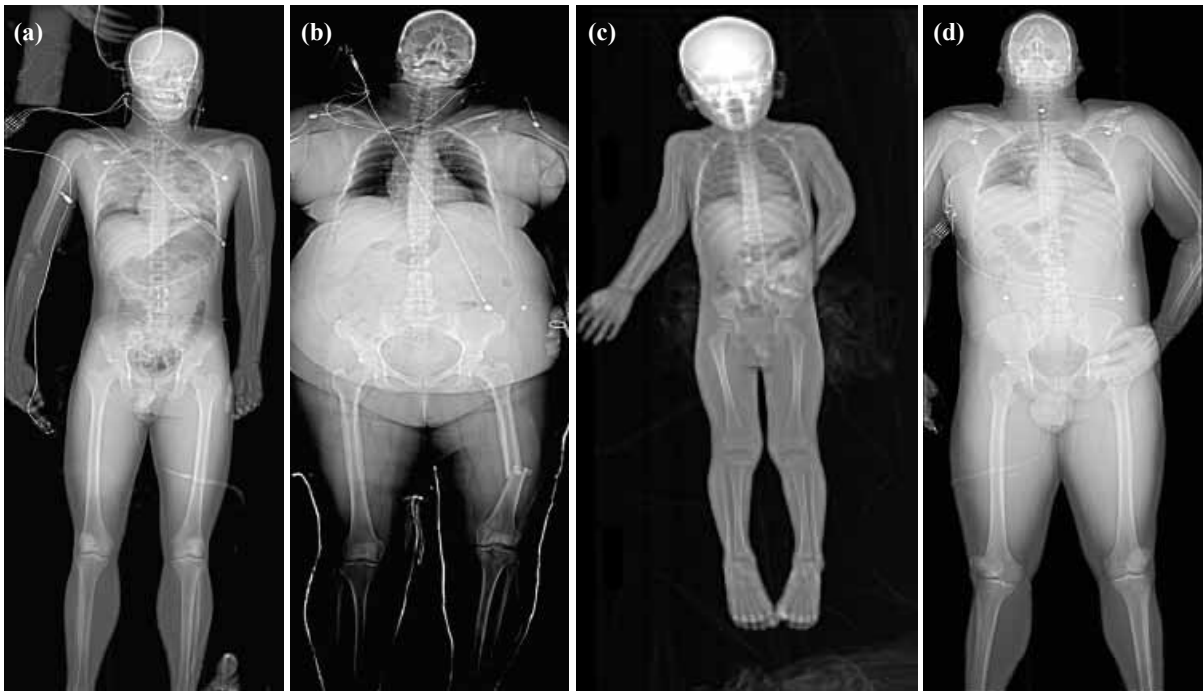


Fig. 5. (a) A 30-year-old male with blunt chest injury after a motor-vehicle accident. The full-body Lodox® Statscan® (LS) demonstrates lung contusion. The image quality for delineating acute lung injury is recognized here. (b) A 48-year-old male with a left femur fracture. The LS provides increased radiological opportunities for bariatric patients. The weight capacity of the carbon-fiber bed accommodates patients up to 450 pounds. In addition, via a specialized algorithm, the machine tailors the amount of X-ray exposure required to image obese patients. In this way, the soft tissue penetration and bony detail is superior to conventional films. (c) A left humeral fracture in a pediatric patient. The LS has been used effectively in the pediatric population to quickly identify multiple bony injuries while limiting radiation exposure. (d) A 50-year-old male with multiple gun-shot wounds (GSW). Bullet fragments are visualized in neck and the right lower quadrant of the abdomen. Full body scanning is helpful in patients with multiple GSWs where comparing anteroposterior and lateral views can identify the potential trajectory of each bullet.

approximately 75% less radiation than conventional machines.^[13] While the linear beam technology is similar to that of a CT scanner, the internal soft tissue is not as well visualized and axial sections are not produced. Clinically, this focused X-ray beam benefits bariatric patients, who are often difficult to image with conventional X-rays, and pediatric patients, owing to the low radiation dose. The Statscan® is useful in various cases of trauma (Fig. 5-8).

The Statscan® is also equipped with the added specificity of collimator knobs located on the C-arm. By visual confirmation with a low energy laser, which delineates the X-ray beam, the radiology technologist is able to control both the width and length of the beam. As such, the amount of X-ray exposure can be further tailored when dealing with patients at both ends of the Body Mass Index (BMI) spectrum. The collimators are also employed when using the Statscan® for standard films such as ankle, wrist, and femur films, where the amount of radiation exposure can be tightly controlled.

The preliminary Statscan® model was first used and researched at Groote Schuur Hospital Trauma Unit in Cape Town, South Africa. An initial study stated that image quality was inferior to that of conventional radiography in the detection of fine detail and penetration.^[14] Modifications in the hardware and software have since been performed and an additional study comparing the low-dose full-body digital X-ray machine with conventional radiography was conducted.^[13] In addition to evaluating diagnostic image quality, this study also looked at other variables including radiation dose, image turnaround time and clinical issues as expressed by the staff.

In terms of image quality, the study, using a seven-point scoring system, ranging from much inferior (-3) to much superior (+3), found the digital Statscan® to be equivalent to conventional imaging. The digital images had a mean equivalence score of -0.429 (SD = 0.77), with the best performance in the mediastinum (mean = 0.346, SD = 0.49) and the weakest in the bony detail (mean = -0.654, SD = 0.81).^[5]

In that study, the mean digital dose was 0.033 R (0.33 mGy) while the mean conventional dose was 0.573 R (5.73 mGy), demonstrating a 94% decrease in radiation received by the patient.^[13] Radiation dose, as compared to standard radiography, varied

based on the type of film desired. The largest radiation dose difference was in the pelvis, where the digital image required only 1.6% of the conventional radiation dose, while the smallest difference was in the chest, where digital imaging required 72% of the conventional dose.^[13]

In evaluating the relative radiation doses, the Statscan[®] was compared to standardized convention-

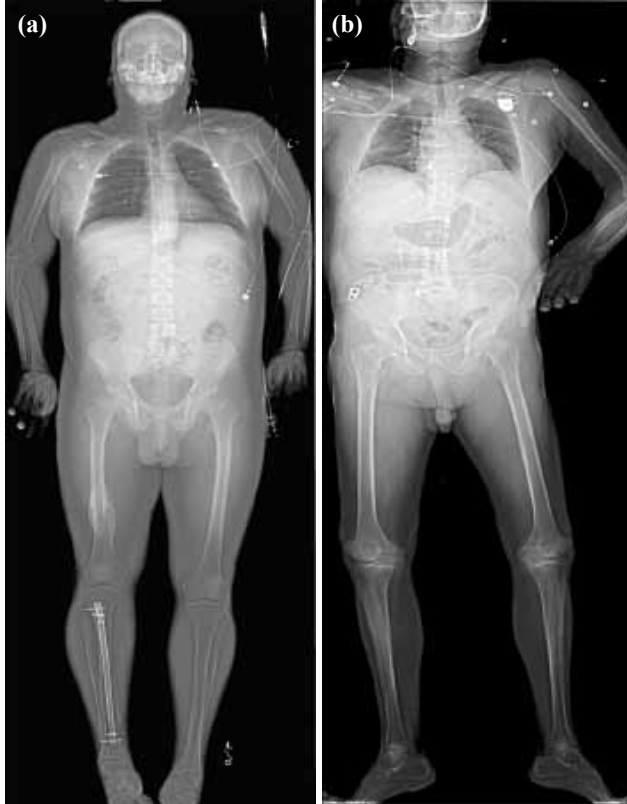

Fig. 6. Hardware incidentally found on Lodox[®] scanning. Two patients presented to the trauma bay following head injury. **(a)** A 43-year-old male who fell off his roof was found to have a right tibial orthopedic rod. **(b)** A 63-year-old female who fell in the shower was found to have a pacemaker. The identification of metallic hardware in unresponsive patients is important in directing the choice of further imaging studies (ex: computed tomography versus magnetic resonance imaging), revealing clues to medical history (ex: pacemaker, aneurysm clips), as well as guiding the need for further assessment. These cases demonstrate the advantage of screening all trauma patients with whole-body Statscan[®] imaging.

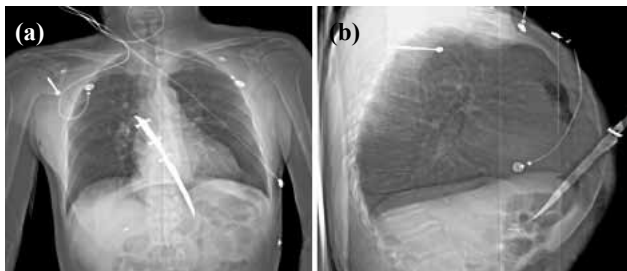


Fig. 7. A 34-year-old male with a stab wound to the chest. **(a)** Anteroposterior and **(b)** lateral Statscan[®] images reveal the location and path of the knife blade directing surgical intervention.

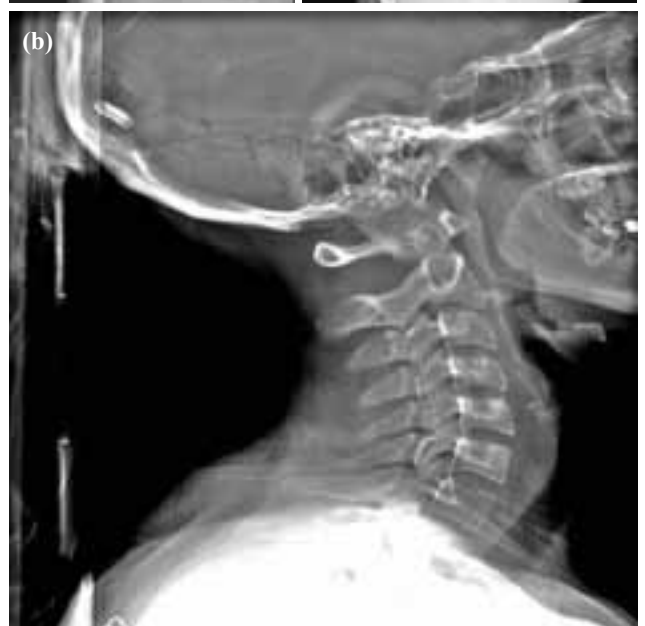
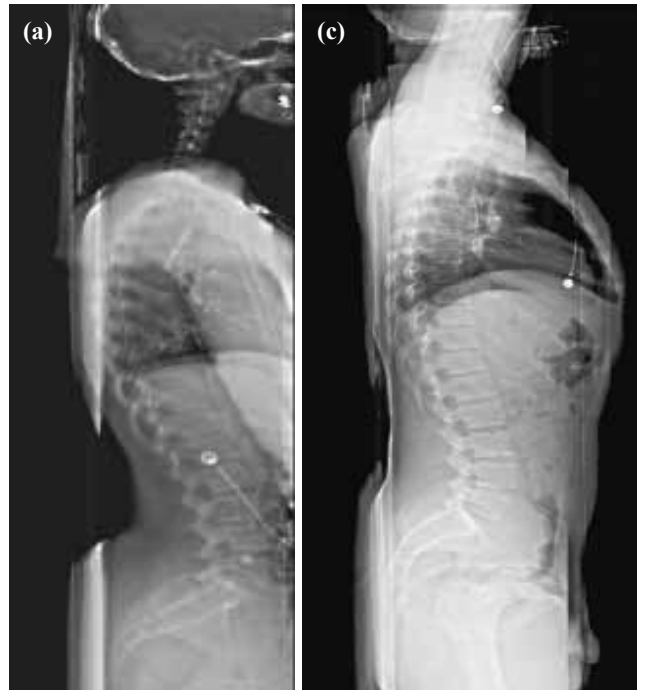
Fig. 8. Lateral scans of **(a)** the whole body spine, **(b)** the cervical spine, and **(c)** the thoracic and lumbar spine. The images are of good quality and comparable to those produced by conventional radiography.

al X-ray doses as determined in a 1993 study.^[15] In that study, the average doses were: AP abdomen 5.2 mGy, posteroanterior (PA) chest 0.27 mGy, AP lumbar spine 8.4 mGy, lateral skull 3.1 mGy, and AP thoracic spine 7.9 mGy.^[7] Average Statscan® doses were: AP abdomen 0.24 mGy, PA chest 0.26 mGy, AP lumbar spine 0.60 mGy, and lateral skull 0.51 mGy.^[13] These two distinct studies confirm the substantial decrease in radiation dose delivered to patients.

After the C-arm scans of the patient, the images are transmitted from the control panel to the diagnostic work station, where the radiology technologist views the preliminary radiographs. These images can then be transmitted to other viewing stations in approximately 5 seconds. At our hospital, these viewing stations are conveniently located in the trauma bay, the radiology reading room, and in the Emergency Department. This ease in availability and transmissibility of images is especially important in teaching institutions where the films can be read by both residents and attending physicians without having to wait for film development. In our experience, the immediate confirmation of injury by the radiologist and the ease in transmissibility have promoted more accurate and expeditious patient care during the initial hour.

At the viewing stations, the digital images can be manipulated and enhanced to demonstrate the desired structures more clearly. As such, regardless of film penetration, the physician is also able to adjust the image to better view the soft tissues or the bony structures. The zoom function can be used to increase the size of any desired area. In our experience, the image quality remained excellent, at times even better than conventional films.

Initially, there was concern that lateral films were not producing optimal images in that the anatomy of the thoracic and lumbar vertebrae was not clearly delineated. The company has since modified the speed of lateral scanning when used for thoracic and lumbar films with scanning speeds of ½ or ¼ of the normal, resulting in better image quality.

Although the well-experienced operator can obtain films rapidly, we found that the 13 seconds AP full body image, in reality, can be difficult to achieve. Most often, this is due to the technologist not having adequate experience with the machine. Updates to the Statscan® have minimized operator error by making the technologist work station user friendly and relatively easy to use. Before the scan starts, the

operator inputs some basic information about the patient that allows the machine to calculate the most effective kilovolt and milliamperage settings. The desired anatomical region is then selected from 16 pre-set visual images depicting the procedures. Thereafter, the Statscan® adjusts the optimum settings for the procedure, eliminating a degree of operator error. Operator discrepancies are thus substantially decreased and the ability of the technologist to take optimum films during the “golden hour” is improved.

In the trauma bay at Creighton, routine films ordered during primary, secondary, and tertiary surveys of a typical patient include C-spine series, AP chest, AP abdomen, AP pelvis, extremity films, and views of any additional areas that have suspected bony injuries. This becomes very time-consuming in the acute resuscitation situation, especially in the light of life-threatening injuries. The time spent on these conventional radiographs averaged 8-48 minutes, whereas equivalent digital radiographs averaged 5-6 minutes.^[13]

In life-threatening injuries, where patients need to be rushed to the OR or angiography suite for immediate intervention, the Lodox scanner has proven helpful in providing information on concomitant injuries otherwise missed on initial examination. Ideally, the use of a single full body scan can efficiently help physicians delineate acute concerns, such as a widened mediastinum, a tension pneumothorax, or various C-spine injuries, from non-acute problems. Additionally, a full body scan is helpful in the assessment of penetrating wounds, especially gunshot wounds, where the location and path of the missiles are unknown. Proper surgical planning can then follow.

In addition to decreasing total scan time, the Statscan® causes limited interference with patient resuscitation in the trauma bay. The patient is attended to while on the Lodox® table and care can continue while the scan is in progress. At Creighton, minimal radiological interruption in the resuscitation of the patient was viewed favorably.

In addition to becoming a valuable asset in the trauma bay, the Statscan® has potential for additional applications. At our institute, the Statscan® has also been used for general purpose digital radiographs such as wrist and ankle films for suspected fractures. A natural progression would be to evaluate the use of the full-body scanning system in skeletal surveys. An additional exciting application is the use of the Statscan® in digital angiography. Current studies are evaluating the utility of this technology in the trauma bay.

In conclusion, at Creighton University Medical Center, the Lodox®'s Statscan® has been beneficial in expediting the radiological processes in the 'golden hour' of trauma patients. This full-body digital radiography system has proven to be not only faster, but potentially safer, more user-friendly, and to have a greater ease of image transmissibility than conventional techniques. All of these factors show promise to reduce morbidity and mortality in trauma patients, encouraging further use at trauma centers worldwide. As with the introduction of any novel medical technology, new trauma protocols that spring from this system warrant detailed investigations in the future.

References

1. Cunningham P, Rutledge R, Baker CC, Clancy TV. A comparison of the association of helicopter and ground ambulance transport with the outcome of injury in trauma patients transported from the scene. *J Trauma* 1997;43:940-6.
2. Biewener A, Aschenbrenner U, Rammelt S, Grass R, Zwipp H. Impact of helicopter transport and hospital level on mortality of polytrauma patients. *J Trauma* 2004;56:94-8.
3. Nicholl JP, Brazier JE, Snooks HA. Effects of London helicopter emergency medical service on survival after trauma. *BMJ* 1995;311(6999):217-22.
4. Buntman AJ, Yeomans KA. The effect of air medical transport on survival after trauma in Johannesburg, South Africa. *S Afr Med J* 2002;92:807-11.
5. Eckstein M, Chan L, Schneir A, Palmer R. Effect of prehospital advanced life support on outcomes of major trauma patients. *J Trauma* 2000;48:643-8.
6. Liberman M, Mulder D, Sampalis J. Advanced or basic life support for trauma: meta-analysis and critical review of the literature. *J Trauma* 2000;49:584-99.
7. Liberman M, Mulder D, Lavoie A, Denis R, Sampalis JS. Multicenter Canadian study of prehospital trauma care. *Ann Surg* 2003;237:153-60.
8. Blow O, Magliore L, Claridge JA, Butler K, Young JS. The golden hour and the silver day: detection and correction of occult hypoperfusion within 24 hours improves outcome from major trauma. *J Trauma* 1999;47:964-9.
9. Kirkpatrick AW, Sirois M, Ball CG, Laupland KB, Goldstein L, Hameed M, et al. The hand-held ultrasound examination for penetrating abdominal trauma. *Am J Surg* 2004;187:660-5.
10. Kirkpatrick AW, Simons RK, Brown R, Nicolaou S, Dulchavsky S. The hand-held FAST: experience with hand-held trauma sonography in a level-I urban trauma center. *Injury* 2002;33:303-8.
11. Discan Homepage. April 16 2003. Lodox turns security detector into low-dose trauma scanner. (June 30, 2003). http://www.discan.com/db_area/archives/2003/041603/04160303.shtml.
12. University of Maryland Medicine Homepage. (June 11, 2003). Digital x-ray developed to detect diamond theft not helps to save lives at shock trauma center. (April 24, 2004). <http://www.umm.edu/news/releases/statscan.html>.
13. Beningfield S, Potgieter H, Nicol A, van As S, Bowie G, Hering E, et al. Report on a new type of trauma full-body digital X-ray machine. *Emerg Radiol* 2003;10:23-9.
14. Beningfield SJ, Potgieter JH, Bautz P, Shackleton M, Hering E, de Jager G, et al. Evaluation of a new type of direct digital radiography machine. *S Afr Med J* 1999;89:1182-8.
15. Havukainen R, Pirinen M. Patient dose and image quality in five standard x-ray examinations. *Med Phys* 1993;20:813-7.