

# The effects of long-term low-dose cyclosporin A treatment on muscles and tendons: an experimental study

Uzun süreli ve düşük doz siklosporin-A tedavisinin kas ve tendonlar üzerine etkileri: Deneysel çalışma

Ranan Gülhan AKTAŞ,<sup>1</sup> Şeref AKTAŞ,<sup>2</sup> Ömer YAZGAN,<sup>3</sup> Şemsi ALTANER<sup>4</sup>

## BACKGROUND

Limited studies report that patients receiving immunosuppressive therapy, including cyclosporin A (CsA), face muscle and/or tendon pathologies. The current study aimed (i) to investigate if CsA cause changes in the microscopic structure of striated muscle tissues and tendons after long-term low-dose therapy and (ii) to examine if the vehicle of CsA, Cremophor EL, or steroid administration might cause additional effects.

## METHODS

Twenty-four adult female Sprague-Dawley rats weighing 230-300 g were divided at random into four groups. Group 1 served as the control. Groups 2-4 received CsA intraperitoneally for 2.5 months: Group 2 received the oral form of CsA, Group 3 received the intravenous form of CsA, which contains Cremophor EL, and Group 4 received the intravenous form of CsA and prednisolone. Samples from the Achilles tendons and triceps surae muscles were examined at light microscope level.

## RESULTS

Focal necrotic areas, enlargement of connective tissue and increase in mononuclear cells were clear on muscles in the experimental groups. No morphologic effects were observed on tendons.

## CONCLUSION

Long-term low-dose CsA therapy causes focal microscopic changes in muscles but not in tendons. No additional effects were demonstrated with Cremophor EL or steroids. It should be noted that muscle tissue damage after trauma or surgeries in patients receiving CsA might be more dramatic due to the pathologic changes already caused by CsA, as supported by several case reports.

**Key Words:** Cyclosporin A; light microscope; muscle; tendon.

## AMAÇ

Az sayıdaki çalışmada, siklosporin-A (CsA) içeren immüno-supresif tedavi alan hastalarda kas ve/veya tendon patolojileri görüldüğü bildirilmiştir. Çalışmamızda, (i) CsA ile düşük doz ve uzun süreli tedavinin ardından mikroskopik düzeyde çizgili kas dokusu ve tendonlarda değişiklik olup olmadığı ve (ii) tedaviye CsA'nın çözücüsü Cremophor-EL ya da steroid eklenmesinin ek bir değişiklik oluşturup oluşturmadığı araştırıldı.

## GEREÇ VE YÖNTEM

230-300 gr ağırlığında, dişi ve erişkin 24 adet Sprague-Dawley cinsi sıçan, rastgele dört gruba ayrıldı. Grup 1 kontrol olarak ayrılırken, diğer üç gruba 2,5 ay süre ile CsA (4 mg/kg/gün) periton içine verildi. Grup 2'ye CsA'nın oral formu, Grup 3'e CsA'nın Cremophor-EL içeren intravenöz (İV) formu verildi. Grup 4'e ise CsA'nın İV formu ile birlikte prednizolon (1 mg/kg/gün) uygulandı. Aşil tendonları ve triseps kaslarından hazırlanan doku örnekleri ışık mikroskopunda incelendi.

## BULGULAR

Tüm deney gruplarında kaslarda lokal dejenerasyon, bağ dokusu artışı, mononükleer hücre sayısında artış gözlemlendi. Tendonlarda herhangi bir değişiklik yoktu.

## SONUÇ

Çalışma, uzun süreli ve düşük dozda CsA kullanımı sonucu kas dokusunda morfolojik değişiklikler olmuştur. Tendonlarda herhangi bir değişiklik gözlenmemiştir. Cremophor-EL veya steroidlere bağlı olabilecek ek bir değişiklik belirlenmemiştir. CsA nedeni ile oluşmuş bu değişikliklere, travma ya da cerrahi girişim sonrası kaslarda oluşabilecek hasarın eklenmesi ile çok daha dramatik bir tablo oluşabileceği göz ardı edilmemelidir. Bu sonucu destekleyen birkaç olgu sunumu vardır.

**Anahtar Sözcükler:** Siklosporin-A; ışık mikroskobu; kas; tendon.

<sup>1</sup>Department of ART, Zeynep Kamil Hospital, Istanbul; <sup>2</sup>Department of Orthopedics and Traumatology, Istanbul Bilim University Faculty of Medicine, Istanbul; <sup>3</sup>Department of Radiology, Düzce University Faculty of Medicine, Düzce; <sup>4</sup>Department of Pathology, Trakya University Faculty of Medicine, Edirne, Turkey.

<sup>1</sup>Zeynep Kamil Hastanesi, Üremeye Yardımcı Tedaviler Merkezi, İstanbul; <sup>2</sup>İstanbul Bilim Üniversitesi Tıp Fakültesi, Ortopedi ve Travmatoloji Anabilim Dalı, İstanbul; <sup>3</sup>Düzce Üniversitesi Tıp Fakültesi, Radyoloji Anabilim Dalı, Düzce; <sup>4</sup>Trakya Üniversitesi, Tıp Fakültesi, Patoloji Anabilim Dalı, Edirne.

Cyclosporin A (CsA) is a potent immunosuppressive agent that is widely used after organ transplantations and in the therapy of autoimmune diseases. Deleterious effects after long-term and low-dose use of CsA on different organs and tissues are still being investigated. There are limited studies reporting changes in muscles and tendons after immunosuppressive therapies. The effects of CsA on these tissues during this therapy are controversial.

The cellular target of CsA is calcineurin, a  $\text{Ca}^{2+}$ /calmodulin-dependent phosphatase. Calcineurin has been implicated in maintenance of muscle fiber size and in expression of the type I skeletal muscle phenotype. It is associated with muscle regeneration via NFATc1/GATA2-dependent pathways. CsA is a cyclophilin ligand and inhibits calcineurin. These effects raise the possibility that long-term CsA use might be harmful on the different types of muscle tissue.

Florio et al.<sup>[1]</sup> demonstrated that CsA increased intracellular calcium, and such effect was dose-dependent. Their study showed that CsA caused an increase in lipid peroxidation and inhibited nitrous oxide (NO) production in rat cardiomyocytes. They suggested that CsA toxicity is due to a calcium overload, which in turn induces lipid peroxidation and determines oxidative stress-induced cell injury. Koulmann et al.<sup>[2]</sup> showed that CsA administration fully prevented the hypoxia-induced increase in the expression of numerous hypoxia-responsive genes in parallel with changes in calcineurin activity, and they suggested that CsA prevents hypoxia-induced right ventricle muscle hypertrophy. Aoki et al.<sup>[3]</sup> showed that CsA administration did not maximize muscle mass loss induced by immobilization. They also indicated that CsA fails to block skeletal muscle regrowth after disuse. They suggested that calcineurin inhibition by CsA modulates muscle phenotype rather than muscle mass.

There are several other studies related with the effects of this drug on muscle at the molecular level: Arai et al.<sup>[4]</sup> found that CsA treatment significantly decreased the myosin heavy chain (MHC) I mRNA level. They analyzed the effects of this drug on the muscle mass as well as on the mRNA levels of MHCs [MHC I, IIa, IIc/x, IIb] in the rat masseter. They found upregulation of MHC IIa mRNA independently of calcineurin signaling pathways, but also the MHC mRNA transition from IIa to I and the muscle mass maintenance mainly of type IIb fiber through

the calcineurin signaling pathways. Koulmann et al.<sup>[2]</sup> studied the responsiveness of mature regenerated soleus muscles to CsA administration in rats. They found that CsA administration induced a similar significant increase in MHC-IIA mRNA levels in both intact and regenerated muscles. The study of Zbreski et al.<sup>[5]</sup> indicated an increase in type IIa MHC content and oxidative enzyme activities in the soleus muscle. They suggested that CsA treatment would cause muscle fiber atrophy.

Krauskopf et al.<sup>[6]</sup> showed that CsA generated superoxide in smooth muscle cells. The anti-proliferative effects of CsA on vascular smooth muscle cell proliferation were also demonstrated by Autieri.<sup>[7]</sup>

The toxic effects of CsA on microvasculature are well known. Unsal et al.<sup>[8]</sup> examined the effect of long-term CsA administration on cremaster flap microcirculation by using an intravital microscopy system. They suggested that systemic CsA administration seems to have minimal impact on the viability of the muscle flaps.

There are several clinical studies related with the locomotor complications, like avascular necrosis, spontaneous fractures, tendinitis and spontaneous tendon ruptures in transplant patients.<sup>[9-14]</sup> However, whether or not these complications are related with the side effects of CsA is still unclear.

Tendons are composed of connective tissue with low cell content, mainly fibroblasts (also referred to as tenocytes), with little vascularity, and are primarily composed of collagen fibers. Increased incidence of tendinitis and tendon ruptures is reported in kidney transplant recipients.<sup>[15]</sup> These complications might be related with either the clinical symptoms of the patient or the immunosuppressive therapy. There are only a few studies related with the effects of this immunosuppressive drug on tendons. The diminishing vascularity of the Achilles tendon with steroid use has been demonstrated.<sup>[16]</sup> The authors suggested that lung transplant recipients who receive ciprofloxacin are at significant risk of developing Achilles tendon disease. They also reported that the overall association of ciprofloxacin and Achilles tendon disease is not dose-related. Tendon rupture occurs at a lower total dose of ciprofloxacin than tendonitis, emphasizing idiosyncratic susceptibility to Achilles tendon disease.

Two cases of bilateral Achilles tendon rupture after minimal trauma are described in transplant

patients. Jorgensen et al.<sup>[17]</sup> proposed that tendon rupture might be due to a vascular phenomenon leading to ischemia. Steinmann et al.<sup>[18]</sup> demonstrated that CsA induced changes in collagen metabolism in an experimental study. Movin et al.<sup>[19]</sup> reported two patients with ciprofloxacin-associated Achilles tendon disease. Chhajed et al.<sup>[20]</sup> found that lung transplant recipients receiving ciprofloxacin are at significant risk of developing Achilles tendon disease. Merlini et al.<sup>[21]</sup> reported the results of an open pilot trial with CsA in five patients with collagen VI myopathies. They reported that the alterations could be normalized by treatment with CsA, which desensitizes the permeability transition pore independently of calcineurin inhibition.

These case reports and limited experimental studies related with the effects of CsA on the locomotor system led us to investigate its effects on skeletal muscles and tendons at the microscopic level after long-term low-dose treatments.

Some studies support the hypothesis that the vehicle of CsA, Cremophor EL, might also have toxic effects. Sanchez<sup>[22]</sup> evaluated the acute effect of CsA and its vehicle on maximal oxidative capacity (V<sub>max</sub>) of cardiac, soleus and gastrocnemius muscles of rats by an oxygraphic method. Their results suggested that the inhibition of oxidative capacity could be entirely attributed to the vehicle for all muscles. Sanchez et al.,<sup>[23]</sup> in another study, stated that CsA, without Cremophor EL, has no deleterious effects on muscle oxidative capacity but induces alterations in energy metabolism in accordance with the increased proportion of fast-twitch oxidative fibers on the rat soleus muscle.

These two studies led us to examine the morphologic effects of the vehicle, Cremophor EL, on either muscle or tendon structure using light microscopy.

In several therapeutic protocols, CsA is used in association with corticosteroids to obtain better therapeutic results. Florio et al.<sup>[11]</sup> stated that glucocorticoids might be effective in reducing CsA-induced toxicity on cardiac muscle at concentrations that were consistent with current therapeutic doses. Murison et al.<sup>[24]</sup> demonstrated that there was a significant correlation between symptoms of tendinitis and the cumulative steroid dose. We also aimed to examine if combined therapy of CsA with steroids might cause any differences on the microscopic structure of striated muscles and tendons.

Finding answers to the above-mentioned questions would be useful to clarify the role of CsA, its vehicle Cremophor EL, and the steroids on these tissues during immunosuppression. We also believe that the conclusions of this study would be helpful for the surgeon with patients undergoing therapy including CsA, since cure of the muscle or the tendon might be different after surgery or another type of trauma on these tissues.

## MATERIALS AND METHODS

The experimental protocols used in this study are in accordance with the ethical principles in animal research followed by Trakya University of Animal Experimentation and were approved by the Ethics Committee for Animals Research of Trakya University.

Twenty-four adult female Sprague-Dawley rats weighing 230-300 g were divided at random into four groups. They were kept in a room at constant temperature (25°C) with alternating 12-h periods of light and darkness and fed food and water ad libitum. Group 1 served as controls and received no treatment. Groups 2-4 received CsA intraperitoneally for 10 weeks at the dose of 4 mg/kg/day, which is the therapeutic dosage used in many protocols for long-term therapies. Group 2 received the oral form of CsA, which does not contain Cremophor EL, the vehicle. Group 3 received the intravenous form of CsA containing Cremophor EL. Group 4 received the intravenous form of CsA and prednisolone at therapeutic dosage (1 mg/kg/day).

The animals were killed with an overdose of ether at the end of the study. Samples from the Achilles tendons and triceps surae muscles were taken from each animal. They were fixed in Bouin solution. Routine histologic procedures were used for the preparation of specimens, and all specimens were finally embedded in paraffin. Sections from these blocks were stained with hematoxylin and eosin. Microscopic examination was done under the light microscope at 100X, 200X and 400X magnification.

## RESULTS

### Findings in Group 1 (Control)

Tendons and muscles showed normal microscopic features, i.e. the presence of fibers with peripheral nuclei and a polygonal shape and with no signs of lesion (Figs. 1a, b). Fibers were aligned linearly in

longitudinal sections. Striation was observed on muscle fibers.

Sections from Achilles tendons demonstrated normal structure of tendons with tenocytes in alignment with the linear pattern of collagen (Fig. 1b).

### Findings in Group 2 (CsA without Cremophor EL)

There were localized degenerative areas on muscles. Necrotic myofibers were characterized by densely eosinophilic stain. Some fibers had lost striations. Connective tissue between muscle fibers was increased. A mild increase in the number of mononuclear cells was also clear (Fig. 1c). Existence of internal pyknotic nuclei in some cells was evident.

Sections from Achilles tendons showed normal microscopic structure of flattened nuclei of tenocytes

between collagen fibers and aligned in rows (Fig. 1d).

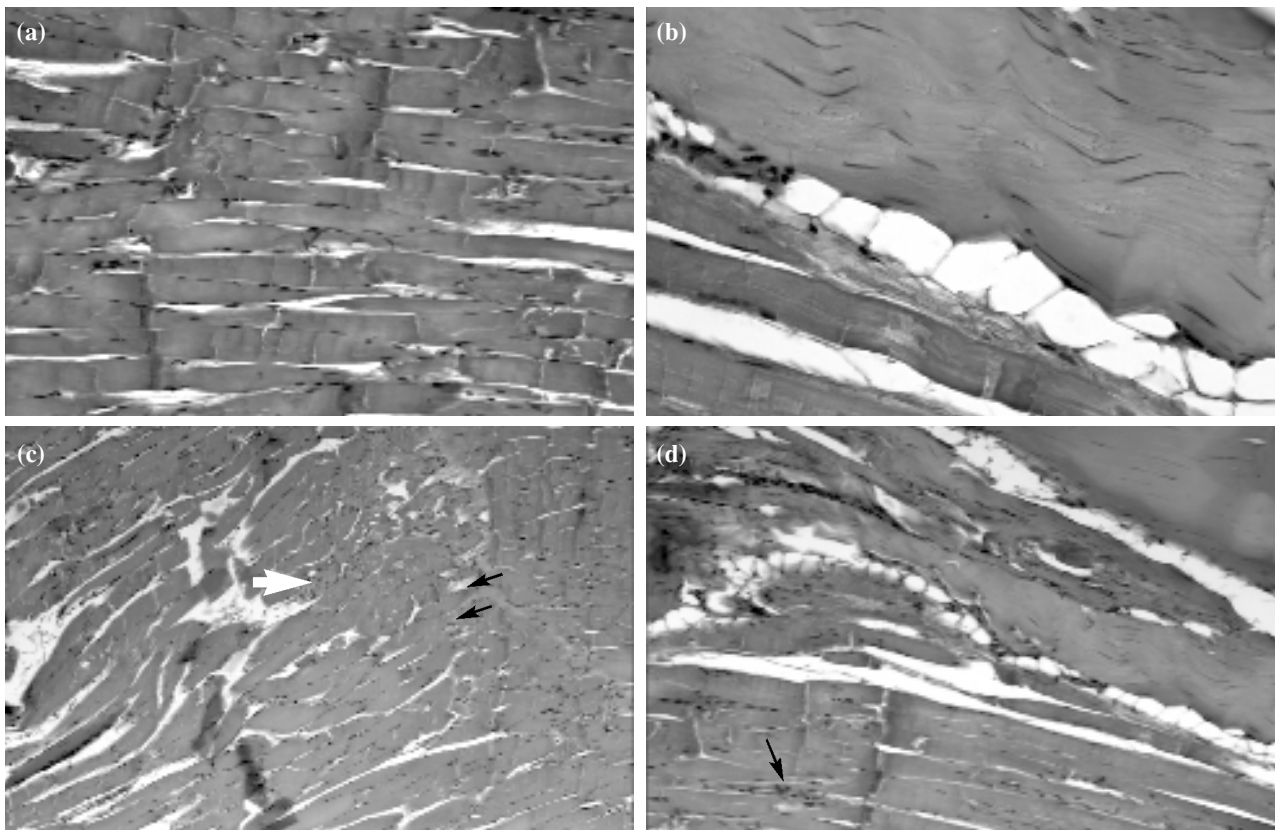
### Findings in Group 3 (CsA with Cremophor EL)

Focal degenerative changes on muscle fibers were clear. Connective tissue was increased. Mononuclear cellular infiltration was evident. Internal pyknotic nuclei of many cells were also noted (Fig. 2a).

Microscopic examination of specimens from the Achilles tendons of animals in this group revealed dense, fairly regular, collagenous tissue with mostly fibers and very few cells (Fig. 2b).

### Findings in Group 4 (CsA with Cremophor EL plus Prednisolone)

Mononuclear cell infiltration was significant. The endomysium was infiltrated by lymphocytes in some



**Fig. 1.** (a) A section from the triceps surae muscle of an animal from the control group. Myofibers demonstrate microscopic structure of normal striated muscle cells with multiple peripherally located nuclei around the branched cells (H-E x 200). (b) Section of myotendinous junction from an animal of the control group. Segment of dense epimysial connective tissue traverses the field. Myofibers on the left bottom side of the field and tendon, which covers most of the field, demonstrate normal morphology at the microscopic level. The tendon is composed of dense, fairly regular collagenous tissue with very few cells (H-E x 200). (c) Section from the muscle of an animal that received CsA without Cremophor EL. Note the increase in connective tissue between fibers (arrows) and cellular infiltration (white arrow) (H-E x 100). (d) Micrograph from the section of Achilles tendon (upper right) and triceps surae muscle (lower side of Figure) of an animal treated with CsA without Cremophor EL. Cellular infiltration between muscle cells is seen while there is no microscopic change in the tendon (H-E x 200).

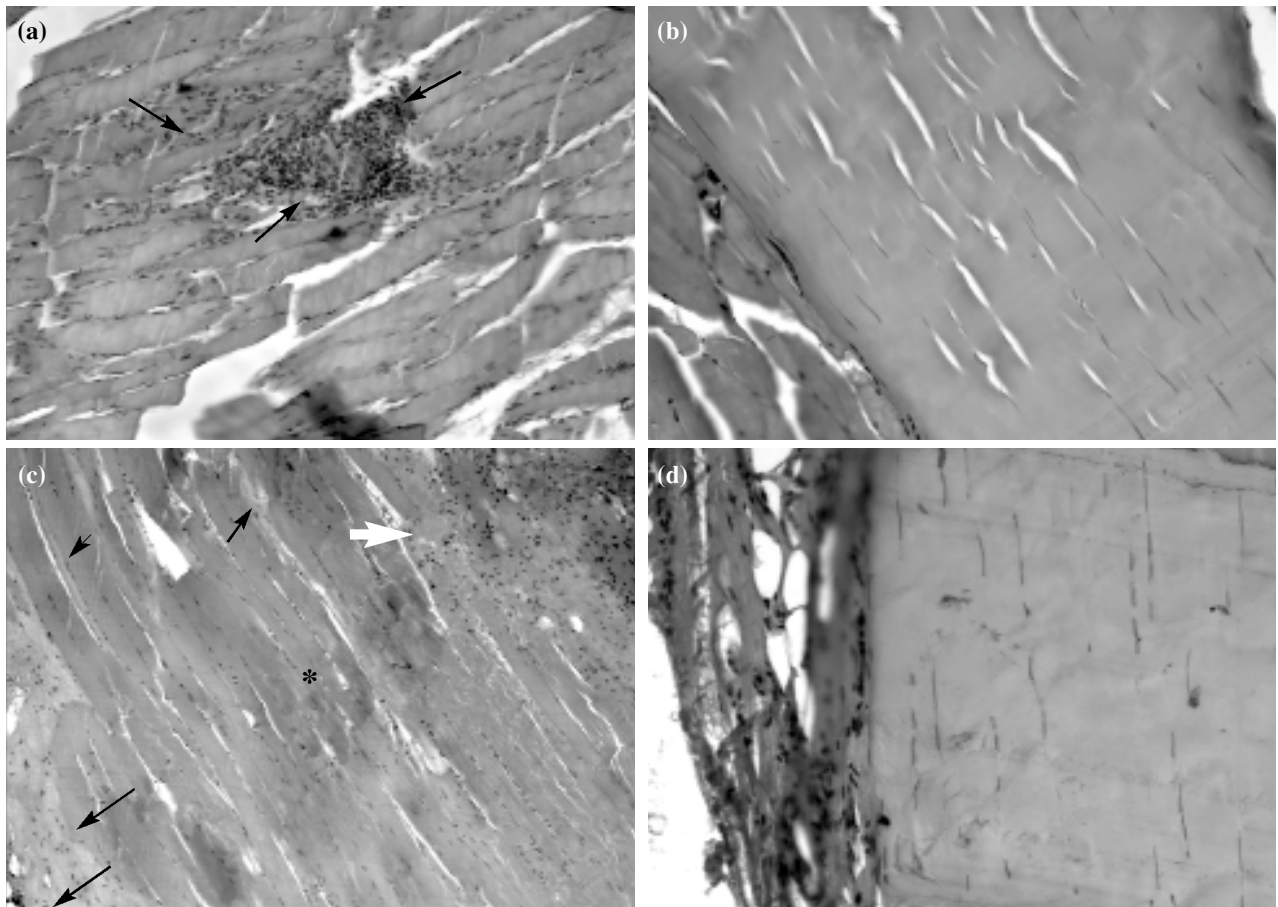
areas. Internal pyknotic nuclei in muscle fibers and increase in connective tissue between fibers were also observed (Fig. 2c).

Achilles tendon sections in this group demonstrated long parallel bundles of collagen fibers and fibroblasts in longitudinal rows and no pathologic findings (Fig. 2d).

## DISCUSSION

This study has demonstrated for the first time the effects of CsA on muscles and tendons at the microscopic level after long-term and low-dose therapy. The results show that CsA therapy, even at low dose, can cause some morphologic side effects in muscles. These include localized necrotic changes, increase in connective tissue between muscle cells and mononuclear cellular infiltration. Some changes at the

molecular level in muscle cells after CsA administration were shown in several previous studies as mentioned before.<sup>[1-6]</sup> There are controversial results related with the effects of CsA on muscles. Irintchev<sup>[25]</sup> showed a hyperplastic effect of CsA treatment on regenerating muscles. Sakuma et al.<sup>[26]</sup> observed that CsA treatment upregulates Id1 and Smad3 expression and delays skeletal muscle regeneration *in vivo*. In another study, Sakuma et al.<sup>[27]</sup> reported that the modulation of MEF2C by CsA treatment might inhibit the hypertrophic process in the soleus muscle after mechanical overloading. In the current study, long-term low-dose application of CsA did not cause hyperplasia or regenerative changes in muscles. However, localized necrotic changes were observed. Zbreski et al.<sup>[5]</sup> indicated an increase in type IIa MHC content and oxidative



**Fig. 2.** (a) Section of the muscle of an animal treated with CsA with Cremophor EL. Note the significant increase in mononuclear cellular infiltration (H-E x 200). (b) Achilles tendon of an animal treated with CsA with Cremophor EL. Tenocytes and collagen fibers between these cells demonstrate normal microscopic structure (H-E x 200). (c) Section of an animal treated with CsA with Cremophor EL and prednisolone. Note the increase in connective tissue (arrows) and mononuclear cellular infiltration (white arrow). Necrotic changes in some muscle fibers were also evident (\*) (H-E x 200). (d) A section from the Achilles tendon after treatment with CsA with Cremophor EL and prednisolone. Dense collagenous tissue with tenocytes shows normal microscopic structure (H-E x 200).

enzyme activities in the soleus muscle and suggested that CsA treatment would cause muscle fiber atrophy. This study supports our results. We also believe that the well-known toxic effects of CsA on microvasculature would cause defects in the microcirculation around muscles, perhaps causing necrotic changes.

Mononuclear cellular infiltration was another microscopic finding on the sections treated with CsA. Sakuma et al.<sup>[26]</sup> observed many mononuclear cells possessing both MEF2C and myogenin protein in mice treated with CsA, but not the placebo, after seven days. This result is consistent with our findings.

Another aim of this study was to examine the effects of this drug on tendons. Our study showed no detrimental morphologic effects on tendons after long-term low-dose use of CsA. Skovgaard et al.<sup>[28]</sup> reported that tendon ruptures are more frequent in individuals with kidney disease in dialysis or after transplantation compared with patients receiving other organ transplantations. Steinmann et al.<sup>[18]</sup> demonstrated that CsA induced changes in collagen metabolism in an experimental study. In the current study, no significant changes in either tenocytes or collagen structure were observed in all groups at the light microscope level. These results support the hypothesis that CsA, Cremophor EL and steroids may have no harmful effects on tendons that could cause tendinitis or tendon ruptures. It is therefore more likely that tendon ruptures are related to metabolic changes associated with kidney disease rather than with transplantation or with glucocorticoid treatment.

Another aim of this study was to examine whether or not Cremophor EL, the vehicle of CsA, had additional effects on either muscles or tendons. Cellular infiltration was clear, especially in Groups 3 and 4 in this study. We hypothesize that Cremophor EL stimulates this infiltration process since more cells were seen in the groups receiving this vehicle.

The last aim was to clarify the effects of steroids. Specimens from animals in Groups 3 and 4 demonstrated similar microscopic findings. Therefore, it is suggested that steroids do not have curative effects after their application with CsA.

We conclude that patients receiving long-term low-dose CsA therapy should be aware of possible

symptoms due to the changes in muscle structure. Local necrotic changes can be seen on striated muscle cells. It is well known that mild changes, as we have observed in this study, might be repaired by the tissue itself. However, they might also cause more harmful pathologic changes if there is another cause of damage like a trauma or surgery. Several case reports support this proposition. The results of this experimental study support the idea that tendons are not affected by long-term CsA therapy. Tendon ruptures and tendinitis, which were seen in the patients after the immunosuppressive therapy, are probably due to other causes. Surgeons can be more comfortable when they plan a surgery, like surgical suturing of an Achilles tendon rupture, in patients receiving CsA with glucocorticoids. However, it should be noted that muscle tissue damage after trauma or surgery in patients receiving CsA might be more dramatic due to the pathologic changes already caused by CsA, as supported by several case reports.

## REFERENCES

1. Florio S, Ciarcia R, Crispino L, Pagnini U, Ruocco A, Kumar C, et al. Hydrocortisone has a protective effect on CyclosporinA-induced cardiotoxicity. *J Cell Physiol* 2003;195:21-6.
2. Koulmann N, Novel-Chaté V, Peinnequin A, Chapot R, Serrurier B, Simler N, et al. Cyclosporin A inhibits hypoxia-induced pulmonary hypertension and right ventricle hypertrophy. *Am J Respir Crit Care Med* 2006;174:699-705.
3. Aoki MS, Miyabara EH, Soares AG, Salvini TF, Moriscot AS. Cyclosporin-A does not affect skeletal muscle mass during disuse and recovery. *Braz J Med Biol Res* 2006;39:243-51.
4. Arai C, Ohnuki Y, Umeki D, Hirashita A, Saeki Y. Effects of clenbuterol and cyclosporin A on the myosin heavy chain mRNA level and the muscle mass in rat masseter. *J Physiol Sci* 2006;56:205-9.
5. Zbreski MG, Helwig BG, Mitchell KE, Musch TI, Weiss ML, McAllister RM. Effects of cyclosporine-A on rat soleus muscle fiber size and phenotype. *Med Sci Sports Exerc* 2006;38:833-9.
6. Krauskopf A, Lhote P, Petermann O, Ruegg UT, Buetler TM. Cyclosporin A generates superoxide in smooth muscle cells. *Free Radic Res* 2005;39:913-9.
7. Autieri MV. Allograft-induced proliferation of vascular smooth muscle cells: potential targets for treating transplant vasculopathy. *Curr Vasc Pharmacol* 2003;1:1-9.
8. Unsal M, Gurunluoglu R, Babucco O, Camevale K, Siemionow M. Effect of long-term cyclosporine administration on muscle flap hemodynamics. *Ann Plast Surg* 2002;48:305-11.
9. Murison MS, Eardley I, Slapak M. Tendinitis-a common complication after renal transplantation. *Transplantation* 1989;48:587-9.
10. Agarwal S, Owen R. Tendinitis and tendon ruptures in suc-

- cessful renal transplant recipients. *Clin Orthop Relat Res* 1990;(252):270-5.
11. Skovgaard D, Feldt-Rasmussen BF, Nimb L, Hede A, Kjaer M. Bilateral Achilles tendon rupture in individuals with renal transplantation. [Article in Danish] *Ugeskr Laeger* 1996;159:57-8.
  12. Movin T, Gad A, Güntner P, Földhazy Z, Rolf C. Pathology of the Achilles tendon in association with ciprofloxacin treatment. *Foot Ankle Int* 1997;18:297-9.
  13. Chhajed PN, Plit ML, Hopkins PM, Malouf MA, Glanville AR. Achilles tendon disease in lung transplant recipients: association with ciprofloxacin. *Eur Respir J* 2002;19:469-71.
  14. Barge-Caballero E, Crespo-Leiro MG, Paniagua-Martín MJ, Muñiz J, Naya C, Bouzas-Mosquera A, et al. Quinolone-related Achilles tendinopathy in heart transplant patients: incidence and risk factors. *J Heart Lung Transplant* 2008;27:46-51.
  15. Le Huec JC, Schaeffer T, Chauveaux D, Rivel J, Dehais J, Le Rebeller A. Epicondylitis after treatment with fluoroquinolone antibiotics. *J Bone Joint Surg [Br]* 1995;77:293-5.
  16. Lund IM, Donde R, Knudsen EA. Persistent local cutaneous atrophy following corticosteroid injection for tendinitis. *Rheumatol Rehabil* 1979;18:91-3.
  17. Jorgensen C, Anaya JM, Didry C, Canovas F, Serre I, Baldet P, et al. Arthropathy with achilles tendon involvement induced by pefloxacin. Apropos of a case. *Rev Rhum Mal Osteoartic* 1991;58:623-5.
  18. Steinmann B, Bruckner P, Superti-Furga A. Cyclosporin A slows collagen triple-helix formation in vivo: indirect evidence for a physiologic role of peptidyl-prolyl cis-trans-isomerase. *J Biol Chem* 1991;266:1299-303.
  19. Movin T, Gad A, Güntner P, Földhazy Z, Rolf C. Pathology of the Achilles tendon in association with ciprofloxacin treatment. *Foot Ankle Int* 1997;18:297-9.
  20. Chhajed PN, Plit ML, Hopkins PM, Malouf MA, Glanville AR. Achilles tendon disease in lung transplant recipients: association with ciprofloxacin. *Eur Respir J* 2002;19:469-71.
  21. Merlini L, Angelin A, Tiepolo T, Braghetta P, Sabatelli P, Zamparelli A, et al. Cyclosporin A corrects mitochondrial dysfunction and muscle apoptosis in patients with collagen VI myopathies. *Proc Natl Acad Sci U S A* 2008;105:5225-9.
  22. Sanchez H, Zoll J, Bigard X, Veksler V, Mettauer B, Lampert E, et al. Effect of cyclosporin A and its vehicle on cardiac and skeletal muscle mitochondria: relationship to efficacy of the respiratory chain. *Br J Pharmacol* 2001;133:781-8.
  23. Sanchez H, N'Guessan B, Ribera F, Ventura-Clapier R, Bigard X. Cyclosporin A treatment increases rat soleus muscle oxidative capacities. *Muscle Nerve* 2003;28:324-9.
  24. Murison MS, Eardley I, Slapak M. Tendinitis-a common complication after renal transplantation. *Transplantation* 1989;48:587-9.
  25. Irintchev A, Zweyer M, Cooper RN, Butler-Browne GS, Wernig A. Contractile properties, structure and fiber phenotype of intact and regenerating slow-twitch muscles of mice treated with cyclosporin A. *Cell Tissue Res* 2002;308:143-56.
  26. Sakuma K, Akiho M, Nakashima H, Nakao R, Hirata M, Inashima S, et al. Cyclosporin A modulates cellular localization of MEF2C protein and blocks fiber hypertrophy in the overloaded soleus muscle of mice. *Acta Neuropathol* 2008;115:663-74.
  27. Sakuma K, Nakao R, Aoi W, Inashima S, Fujikawa T, Hirata M, et al. Cyclosporin A treatment upregulates Id1 and Smad3 expression and delays skeletal muscle regeneration. *Acta Neuropathol* 2005;110:269-80.
  28. Skovgaard D, Feldt-Rasmussen BF, Nimb L, Hede A, Kjaer M. Bilateral Achilles tendon rupture in individuals with renal transplantation. *Ugeskr Laeger* 1996;159:57-8.