

Subtotal ear amputation with a very narrow pedicle: a case report and review of the literature

Çok dar pediküllü bir subtotal kulak amputasyonu: Olgu sunumu ve literatür taraması

Derya ÖZÇELİK, Toygar ÜNVEREN, Gaye TOPLU

Total ear amputation is common, and management can necessitate different procedures, especially microsurgical anastomosis. Partial ear amputations supplied by narrow pedicles, however, have been reported rarely. In a subtotally amputated auricle, the chance of survival depends on the vascularization within the pedicle. In our case, the right ear of a 36-year-old male patient was subtotally amputated following a traffic accident, leaving only a 6-mm skin pedicle on the cranial side. The subtotally amputated segment was bleeding from the wound margins. The ear was reattached with primary suture without using microsurgical techniques after optimal debridement. Postoperatively, we administered dextran 40 for 5 days to improve the microcirculation and increase blood volume and antibiotic to control the infection. No signs of edema, venous congestion or arterial insufficiency were observed immediately after the operation or subsequently. The replanted auricle healed completely with 100% survival, resulting in an essentially normal contour and appearance. This successful result without microvascular anastomoses also points out the anatomical features of the auricular vascular networks.

Key Words: Amputation; auricle; ear; pedicle; replantation; vascular network.

Total kulak amputasyonu sıklıkla görülür. Tedavisi özellikle mikrocerrahi anastomozlar olmak üzere farklı yöntemler gerektirebilir. Ancak, dar bir pedikülden beslenen kısmi kulak amputasyonları nadiren bildirilmiştir. Subtotal ampute olan bir aurikulada, dokunun yaşaması pedikül içindeki damarlanmaya bağlıdır. Bizim olgumuzda, 36 yaşındaki erkek hastanın sağ kulağı trafik kazasını takiben, kraniyal kısımda sadece 6 mm'lik deri pedikülü kalacak biçimde subtotal olarak ampute olmuştur. Subtotal ampute olan segment yara kenarlarından kanıyordu. Kulak optimal debridmanı takiben, mikrocerrahi teknikler kullanmadan primer dikilerek yerine adapte edildi. Ameliyat sonrası mikrosirkülasyonu iyileştirmek ve kan hacmini artırmak için dekstran 40 ve enfeksiyon kontrolü için antibiyotik uygulandı. Ameliyattan hemen sonra ve takipte, ödem, venöz konjesyon veya arteriyel yetersizlik bulguları izlenmedi. Replante olmuş aurikula yüzde yüz yaşayarak tamamen iyileşti ve normal bir kontur ve görünümüne sahip oldu. Mikrovasküler anastomoz olmaksızın gerçekleşen bu başarılı sonuç, kulak bölgesindeki vasküler ağı anatomik özelliklerini vurgulaması açısından önem taşımaktadır.

Anahtar Sözcükler: Amputasyon; aurikula; kulak; pedikül; replantasyon; vasküler ağ.

Total ear amputation is common, and management can necessitate different procedures, especially microsurgical anastomosis. Partial ear amputations supplied by narrow pedicles, however, have been reported rarely.^[1-7]

In a subtotally amputated auricle, the chance of survival depends on the vascularization within the pedicle. A thin pedicle can contain artery and vein

and can supply a large segment of the auricle.

In our case, a large segment of the auricle was supplied by a narrow superior pedicle and primary repair was performed. In the literature, three very similar cases have been reported.^[1-3] We think that these four cases are very important in highlighting the anatomical features of the auricular vascular networks.

CASE REPORT

A 36-year-old non-smoker male presented with an almost totally amputated auricle. Following a traffic accident, the right ear of the patient was subtotally amputated, leaving only a 6-mm skin pedicle on the cranial side. On examination, the subtotally amputated auricle consisted of a 25 x 60 mm segment of the helix and antihelix. Concha and lobule were partially intact. Only a 6-mm wide skin strip connected the helical crus with the temporal region (Fig. 1). The skin of the posterior aspect of the auricle and the cartilage of the helix and antihelix had been completely severed (Fig. 1). It was an avulsion injury. Subtotally the amputated segment was bleeding from the wound margins. The cranial half of the segment had normal color and the distal end was slightly bluish and had minimal congestion at the margins. He was not injured elsewhere.

Operation was performed under general anesthesia, about three hours after the injury. First, the wound margin was debrided for about 2 mm on the auricular and temporal sides until favorable normal bleeding was confirmed, except for the remaining skin attachment. The cartilage and skin were sutured in layers. The ear was reattached without using microsurgical techniques. A bandage with slight compression was used. No signs of edema, venous congestion or arterial insufficiency were observed immediately after the operation or subsequently. Postoperatively, we administrated dextran 40 for 5 days to improve the microcirculation and increase

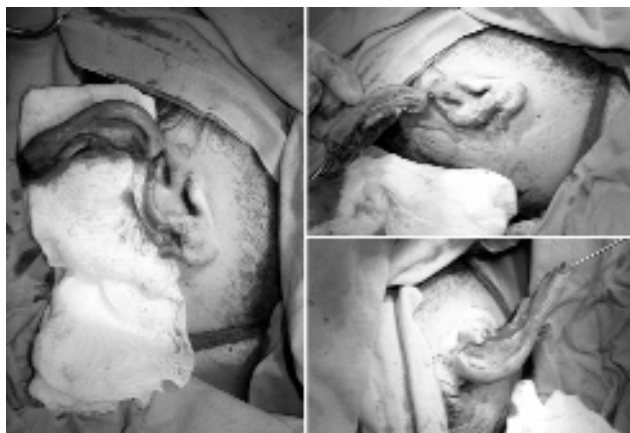

Fig. 1. Preoperative views of a subtotally amputated right ear. Only a strip of skin 6-mm wide connected the helical rim to the temporal region. Posterior skin and cartilage of the helix and antihelix were completely amputated. Good tissue perfusion and bleeding from the wound edges can be seen.

blood volume and antibiotic to control the infection, but no other drugs such as prostaglandin preparations or heparin were given. The replanted auricle healed completely with 100% survival, resulting in an essentially normal appearance (Fig. 2). After six months, the ear regained normal touch and two-point sensibility and there was no difference in perception between the left and right sides.

DISCUSSION

Subtotally amputated ear segment management requires either microsurgical replantation or primary reattachment if perfusion of the segment is good or salvage procedures such as banking the ear cartilage for future use or using it as a composite graft. In the literature, report of subtotal ear amputations supplied by narrow pedicles is very rare. Subtotal ear amputations supplied by narrow superior pedicles have been reported in only three patients previously.^[1-3] These three patients had almost the same type thin superior pedicle and the same type of severing of the auricle, with good perfusion of the severed segment. Pedicle sizes of two cases were reported as 1 cm and 3 mm and the ear lobules were also involved.^[1,2] In the third case, the ear lobule was intact.^[3] Herein, we report a fourth case of a very similar injury with almost totally amputated auricle supplied by a 6-mm superior pedicle. In the four cases, including ours, subtotal ear amputations were salvaged with only primary reattachment.

In four patients, the superficial temporal arterio-venous system was preserved apparently because the skin attachment was located at the anterior aspect of the helical crus. Good blood flow seemed to be maintained by the triangular fossa-scapa network,

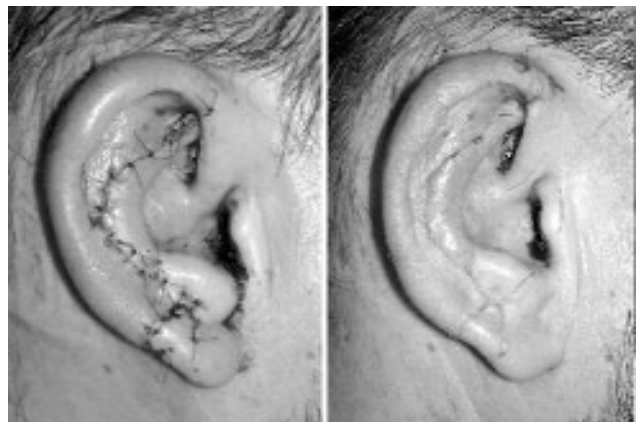


Fig. 2. Three days and two weeks postoperatively: natural appearance of the ear after primary reattachment without a vascular anastomosis.

as proposed by Park et al.^[8,9] Şafak et al.^[1] and Yotsuyanagi et al.^[2] described congestion at the lobule, because the caudal side of the lobule is primarily supplied only by the lower branch of the superficial temporal artery and is not linked to a major network. In both cases, the ear lobule was resected due to congestion. In our case, the ear lobule was intact.

These four cases provide a thorough understanding of the anatomical features of the vasculature, which is crucial when selecting the procedure for reconstruction, and confirm that most of the auricle survives if an apparently intact upper branch of the superficial temporal vessels is present to maintain blood flow. Additionally, they also demonstrate the distribution of the superficial temporal vessels within the helical skin.

A search of the literature for reports of other subtotally amputated auricles supplied by pedicles other than the superior pedicle revealed an unexpectedly small number of cases.^[4-7] Tomono and Hirose^[7] reported two patients, in the first of whom the skin attachment to the lobule measured 1.5 x 3 cm. After debridement of the wound margin, the auricle was sutured; heparin and nicotinic acid preparations were given postoperatively. The patient developed pronounced edema, and the sutured region and part of the skin and cartilage of the concha necrosed; however, the take was good at other sites. In the other patient, a skin attachment about 1 cm wide remained at the lobule. This patient was treated similarly to the first, and the suture line necrosed, but the take was otherwise good. Komuro and Kawanabe^[5] described a patient in whom the lobule remained attached by a strip of skin about 1 cm wide. As the cranial half of the auricle was dark red and there was no bleeding, the postauricular artery was anastomosed. The take was good with no congestion, which supports the use of a postauricular arterial anastomosis. Clodius^[4] described two patients. The first had a skin pedicle about 3.5 cm wide at the postero-inferior aspect of the auricle. The other patient had an attachment measuring about 3 cm wide at the postero-superior aspect of the auricle. They also used cooling treatment and both patients recovered completely. Nahai et al.^[6] reported a patient in whom two-thirds of the cranial side of the auricle had been avulsed; a 1.5-cm strip of skin remained attached to the anterior aspect of the helical crus. Two arteries were anastomosed, and recovery was complete.

A factor influencing treatment is the mechanism

of the injury—for example, whether the auricle was amputated with a sharp instrument or if it was avulsed, because of its relation to the degree of crush injury. Major determinants of whether the auricle should be sutured directly or whether a vascular anastomosis is required are the relation of the remaining attachment to the vasculature, the degree of auricular congestion, and the amount of bleeding from the stump.^[2]

Park et al.^[8,9] demonstrated the detailed anatomy of the arterial supply of the posterior and anterior aspects of the auricle in fresh cadavers. Two arterial networks originating mainly from the superficial temporal artery and posterior auricular artery were shown to share enormous communicating branches between them. Either of these two overlapping axial systems can clinically support extended local flaps or replantations. The postauricular artery has the greatest impact on auricular blood flow, and consequently, a better chance of survival is expected provided that the postauricular arteriovenous system is preserved at the posterior aspect of the auricle. Additionally, the auricle is unique in that it contains a large piece of cartilage that lacks internal circulation. The subcutaneous tissue mass is also relatively thin, so the metabolic demand of the auricle is low. Therefore, it has low oxygen consumption, which increases the survival rate of subtotal amputations with narrow pedicles.

Since local anesthesia could increase edema at the pedicle and this can further decrease the limited tissue perfusion or damage the vessels directly at time of injections, we preferred general anesthesia. The amputated part was reattached to its anatomic position in a manner that decreases tension on the pedicle. Grasping or pulling the pedicle or applying tension during suturing can result in failure.

The pedicle can contain either artery or vein or both. To provide neovascularization, good debridement should be performed. Akyürek et al.^[10] described a case of microvascular ear replantation with repair of the artery only and medicinal leech therapy that resulted in survival for 14 days but ultimately failed as a result of the absence of development of venous channels between the replant and the recipient bed. Since no suitable veins could be found, leech therapy and systemic heparinization had been used for venous drainage. In retrospect, the authors surmised that inadequate debridement of nonvital tissues may have led to the failure of devel-

opment of venous channels between the replant and the recipient bed, as manifested by the frequent requirement of leeching to relieve venous congestion long after revascularization. They concluded that the importance of thorough debridement cannot be overemphasized in microsurgical ear replantation with no vein anastomosis.

The optimal extent of the debridement remains controversial. We think that the margins of crush wounds should be debrided whenever possible. This is an important factor in maintaining appropriate, rapid blood flow after suturing to ensure normal wound healing. The pedicle region must of course be treated conservatively. Next, the congested sites should be resected, taking care not to damage the overall shape of the auricle. In patients such as ours in whom good blood flow through the vascular networks is anticipated, arterial anastomosis is unnecessary. In patients with severe crush injuries with considerable congestion, complete debridement can alter the shape of the auricle. Such patients should undergo loose suture only and should then be observed, without any overzealous attempt to suppress venous bleeding. After a short period, the patient's condition should be re-evaluated and further action taken if required. If congestion affects the entire auricle, the case should be handled as if it was a complete amputation, and preparations should be made for a vascular anastomosis or other procedures.^[2] At this point, for a successful vascular anastomosis, the period of the warm ischemia becomes important.

Pollock et al.^[11] investigated the cellular injury produced by reperfusion of ischemic tissue with oxygen-rich blood in the rabbit ear and compared four and six hours of ischemia to document the evidence of impaired capillary perfusion after resumption of blood flow (reperfusion injury) using vital capillaroscopy (VC) and laser Doppler flowmetry (LDF). One ear from each of five rabbits underwent warm ischemia for four hours. VC showed no deficits in capillary perfusion in these ears after reperfusion; LDF measurements in both ears also demonstrated no significant difference between control and reperfusion blood flow. One ear from each of eight additional rabbits underwent six hours of warm ischemia. LDF values were significantly reduced in the ischemic ear after reperfusion as compared with baseline measurements for that ear and as compared with the control ear. VC showed arrested

perfusion and static plasma gaps within three to five capillaries per high-power field in the ischemic ear and good perfusion of all vessels in the contralateral control ear. As a result, for a successful vascular anastomosis of an ear, the period of the warm ischemia should be less than 4-5 hours.

If there is vascular compromise to the ear, other techniques can be used. Reattachment as a composite graft of the amputated ear is one of the techniques but it is reported as unreliable.^[12] Other authors have removed the skin from the cartilage and have buried the cartilage alone, either in the postauricular area or at a distance, and have attempted, in staged fashion, to reconstruct the ear.^[13]

The cartilage denuded of its dermal covering becomes distorted as a result of the scarring in the surrounding bed. Consequently, the end result after multiple procedures is an ear that has lost most of its definition.^[14] Coverage of the denuded ear cartilage framework with a temporoparietal fascial flap does not protect it from distortion, since scarring still forms at the interface.^[15-17] The thin, pliable ear cartilage becomes easily distorted compared with the thick, rigid carved costal cartilage framework that has been popularized by Brent and Byrd,^[18] Tanzer,^[13] and others.

Other authors have proposed more complex, multistaged techniques where part of the skin from the amputated ear is initially excised to improve the inset and enhance the "take" of the composite ear amputation.

In 1972, Baudet et al.^[19] salvaged an amputated ear by excising the posterior skin and making several large fenestrations in the cartilage to allow exposure of the underside of the anterior skin to the underlying vascular bed. The anterior skin was sutured to the amputated stump of the ear and the helical rim of the postauricular flap. They thusly provided a larger area of inset and, with the cartilage fenestration, greater surface area of contact with vascular tissue to enhance composite graft "take." The anterior skin survived. The ear was then elevated in a second operation and the postauricular area skin grafted.

More recently, Destro and Speranzini^[20] described a similar technique in which they removed all the skin from the amputated ear except over the concha. They then made multiple small perforations in the cartilage and covered the denuded cartilage with a

postauricular flap. The ear survived, and three months later it was elevated and the retroauricular area skin grafted.

To enhance survival of a reattached ear segment, Mladick et al.^[14,21] advocated use of the retroauricular pocket principle. This technique involves de-epithelialization of the amputated part, followed by anatomic reattachment to the amputation stump and then burial in a retroauricular pocket for 14 to 21 days. This simple technique increases the surface area of the avulsed segment in contact with surrounding nutrients, maximizing the probability of "take". The relationship between the dermis and cartilage is preserved, thus minimizing the deformity from cartilage warping. The undisturbed dermis on the involved segment can reepithelialize spontaneously, negating the need for a skin graft.

In conclusion, we recommend primary repair of the subtotally amputated ear segment if the wound has favorable tissue condition and wound margins bleed, even if the skin pedicle is narrow.

REFERENCES

1. Safak T, Kayikcioglu A. A traumatic ear amputation attached with a narrow pedicle. *Ann Plast Surg* 1998;40:106-7.
2. Yotsuyanagi T, Yamashita K, Watanabe Y, Urushidate S, Yokoi K, Sawada Y. Reconstruction of a subtotally amputated auricle: a case report. *Scand J Plast Reconstr Surg Hand Surg* 2001;35:425-8.
3. Brent B. Reconstruction of the auricle. In: McCarthy JG, editor. *Plastic surgery*. Vol 3, Philadelphia: W.B. Saunders; 1990. p. 2094-152.
4. Clodius L. Local hypothermia for the avulsed external ear. *Br J Plast Surg* 1968;21:250-2.
5. Komuro Y, Kawanabe T. The microsurgical reconstruction of an incompletely amputated ear: a case report. *Jpn J Plast Reconstr Surg* 1995;38:935-9.
6. Nahai F, Hayhurst JW, Salibian AH. Microvascular surgery in avulsive trauma to the external ear. *Clin Plast Surg* 1978;5:423-6.
7. Tomono T, Hirose T. Treatment of the subtotally amputated auricle. *Jpn J Plast Reconstr Surg* 1980;23:41-6.
8. Park C, Lineaweaver WC, Rumly TO, Buncke HJ. Arterial supply of the anterior ear. *Plast Reconstr Surg* 1992;90:38-44.
9. Park C, Shin KS, Kang HS, Lee YH, Lew JD. A new arterial flap from the postauricular surface: its anatomic basis and clinical application. *Plast Reconstr Surg* 1988;82:498-505.
10. Akyürek M, Safak T, Keçik A. Microsurgical ear replantation without venous repair: failure of development of venous channels despite patency of arterial anastomosis for 14 days. *Ann Plast Surg* 2001;46:439-42; discussion 442-3.
11. Pollock FE Jr, Smith TL, Koman LA, Holden MB, Smith BP. Decreased microvascular perfusion in the rabbit ear after six hours of ischemia. *J Orthop Res* 1994;12:48-57.
12. Musgrave RH, Garrett WS Jr. Management of avulsion injuries of the external ear. *Plast Reconstr Surg* 1967;40:534-9.
13. Tanzer RC. The reconstruction of acquired defects of the ear. *Plast Reconstr Surg* 1965;35:355-65.
14. Mladick RA, Carraway JH. Ear reattachment by the modified pocket principle. Case report. *Plast Reconstr Surg* 1973;51:584-7.
15. Sucur D, Ninkovic M, Markovic S, Babovic S. Reconstruction of an avulsed ear by constructing a composite free flap. *Br J Plast Surg* 1991;44:153-4.
16. Tolhurst DE, Carstens MH, Greco RJ, Hurwitz DJ. The surgical anatomy of the scalp. *Plast Reconstr Surg* 1991;87:603-12; discussion 613-4.
17. Carstens MH, Greco RJ, Hurwitz DJ, Tolhurst DE. Clinical applications of the subgaleal fascia. *Plast Reconstr Surg* 1991;87:615-26.
18. Brent B, Byrd HS. Secondary ear reconstruction with cartilage grafts covered by axial, random, and free flaps of temporoparietal fascia. *Plast Reconstr Surg* 1983;72:141-52.
19. Baudet J, Tramond P, Goumain A. A new technic for the reimplantation of a completely severed auricle. [Article in French] *Ann Chir Plast* 1972;17:67-72. [Abstract]
20. Destro MW, Speranzini MB. Total reconstruction of the auricle after traumatic amputation. *Plast Reconstr Surg* 1994;94:859-64.
21. Mladick RA, Horton CE, Adamson JE, Cohen BI. The pocket principle: a new technique for the reattachment of a severed ear part. *Plast Reconstr Surg* 1971;48:219-23.