

Management algorithm for intestinal obstruction due to ascariasis: a case report and review of the literature

Askariasise baęlı intestinal tıkanma için tedavi algoritması: Olgu sunumu ve literatür taraması

Ashraf F HEFNY,¹ Yousif A SAADELDIN,² Fikri M ABU-ZIDAN³

Ascaris lumbricoides is the largest and most prevalent of the human helminths. Ascariasis causes a unique type of intestinal obstruction with specific problems, having high morbidity and mortality. There is no management algorithm available in the literature to treat such cases. We aimed in this study to develop an algorithm for the management of intestinal obstruction due to ascariasis. A medline search of the English literature on the management of intestinal obstruction due to ascariasis was performed. Management of one of our patients with intestinal obstruction due to ascariasis is presented herein as an example of such cases. Intestinal obstruction due to ascariasis is a serious disease with a high morbidity and mortality, especially postoperatively. A management algorithm for the treatment was developed. The management of intestinal obstruction due to ascariasis was challenging and required difficult decisions. We think that this algorithm will be of great assistance in facilitating a rapid and successful treatment. This algorithm may prove to be of a great value for physicians treating such cases.

Key Words: Algorithm; ascariasis; intestinal obstruction; management.

Ascaris lumbricoides en büyük ve en yaygın insan helmintidir. Ascariasis yüksek morbidite ve mortaliteye sahip, kendine has sorunlarla birlikte olan intestinal tıkanmanın özgün bir tipine neden olur. Literatürde böyle olguları tedavi için algoritma bulunmamaktadır. Bu çalışmada, askariasise baęlı intestinal tıkanmanın tedavisine yönelik bir algoritmayı geliştirmeyi amaçladık. Askariasise baęlı baęırsak tıkanıklığıyla ilgili olarak İngilizce literatürde bir medline taraması yapıldı. Askariasise baęlı intestinal tıkanmalı hastalarımızın birinin tedavisi, bu tip olguların bir örneęi olarak sunuldu. Askariasise baęlı intestinal tıkanma, özellikle postoperatif dönemde, yüksek bir morbidite ve mortaliteye sahip ciddi bir hastalıktır. Tedavi için bir algoritma geliştirildi. Askariasise baęlı intestinal tıkanmanın tedavisi güçtür ve zor kararların alınması gereklidir. Biz, bu algoritmanın hızlı ve başarılı bir tedavi için büyük yarar sağlayacağını düşünüyoruz. Bu algoritma böyle olguları tedavi eden klinisyenler için çok değerli olabilir.

Anahtar Sözcükler: Algoritma, ascariasis, intestinal tıkanma, yönetim.

Ascaris lumbricoides is the largest and most prevalent of the human helminths. It is more prevalent in tropical and subtropical climates. Infection occurs by ingestion of the embryonated eggs. The released larvae from the eggs in the intestine go into a pulmonary migration phase. The larvae attain sexual maturity within three months after reaching the small intestine.^[1,2]

Ascariasis can cause serious intra-abdominal complications such as intestinal obstruction, biliary obstruction, cholangiohepatitis, liver abscess, pan-

creatitis, acute appendicitis, intestinal perforation, and granulomatous peritonitis. Intestinal obstruction is the most common complication.^[3-5] Diagnosis and management of intestinal obstruction caused by ascariasis differ from other types of intestinal obstruction. It has a high morbidity and mortality, especially following surgical intervention.^[6,7] The physicians treating patients with ascariasis should be aware of the abdominal complications, since a delay in its management may have a fatal outcome.^[8,9] We recently treated a patient with intestinal obstruction

Departments of ¹Surgery and ²Radiology, Al-Ain Hospital, Al-Ain;

³Department of Surgery, United Arab Emirates University Faculty of Medicine and Health Sciences, Al-Ain, United Arab Emirates.

Al-Ain Hastanesi ¹Cerrahi Klinięi, ²Radyoloji Bölümü, Al-Ain;

³Birleşik Arap Emirlikleri Üniversitesi Tıp Fakültesi ve Sağlık Bilimleri Cerrahi Bölümü, Al-Ain, Birleşik Arap Emirlikleri.

due to ascariasis. The management was challenging, and difficult decisions had to be made quickly. To the best of our knowledge, there is no management algorithm available in the literature to assist in these decisions. We have reviewed the literature to develop such an algorithm, which we think will be of great assistance in managing intestinal obstruction due to ascariasis.

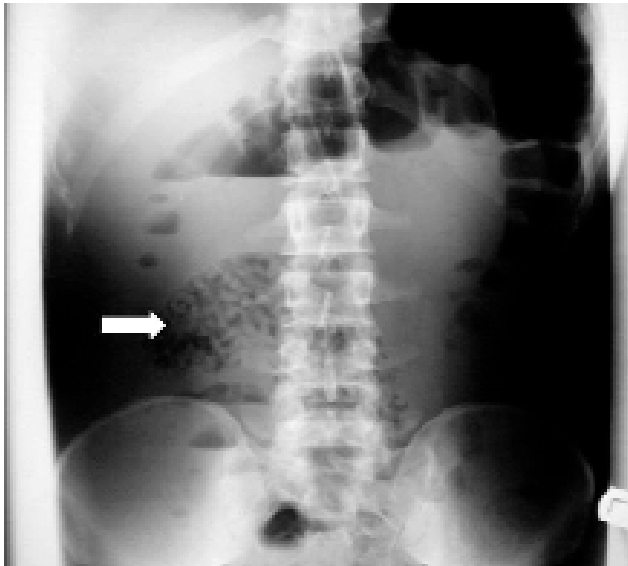


Fig. 1. Erect plain abdominal X-ray showing multiple fluid air levels and a classical ball of round worms (white arrow).

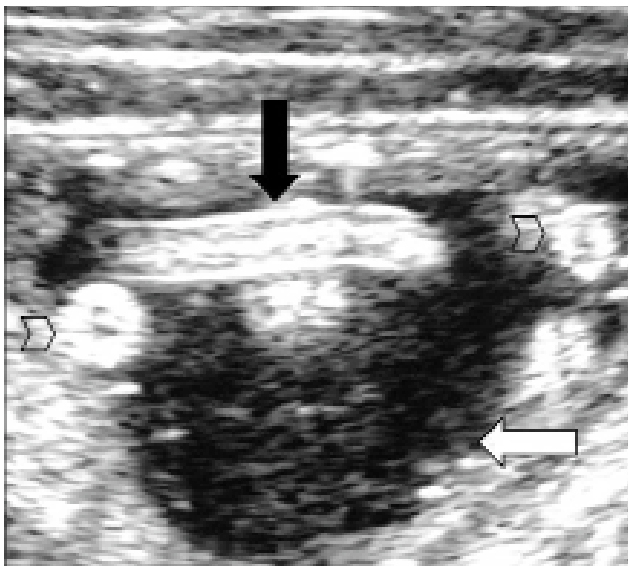


Fig. 2. Abdominal ultrasound using a linear probe showing multiple Ascaris worms with bull's eye (cross-section of worms, arrow heads) and railway appearance (longitudinal section of worms, black arrow) within the lumen of the small bowel (white arrow).

CASE REPORT

A 32-year-old Bangladeshi male had recently returned from vacation in his home country. He was admitted to Al-Ain hospital complaining of abdominal pain, vomiting and constipation for three days. On examination, he was in great discomfort. His temperature was 37.8°C, blood pressure 120/70 mmHg, and pulse 80 beats per minute. The abdomen was soft and not distended with mild diffuse tenderness. Rectal examination demonstrated *Ascaris* worms. Laboratory investigations including complete blood analysis, glucose, serum amylase, liver function and electrolytes were all normal. Abdominal X-ray showed dilated small intestine, multiple air fluid levels, and a ball of round worms (Fig. 1). Abdominal ultrasound confirmed the presence of a mass of multiple *Ascaris* worms with bull's eyes and railway appearance (Fig. 2). Gastrografin follow-through study showed the dilated small intestine, which was full of *Ascaris* worms. The passage of the contrast into the rectum showed incomplete intestinal obstruction (Fig. 3). Abdominal computerized tomography (CT) scan revealed the bolus of *Ascaris* worms in the small bowel and no free air or

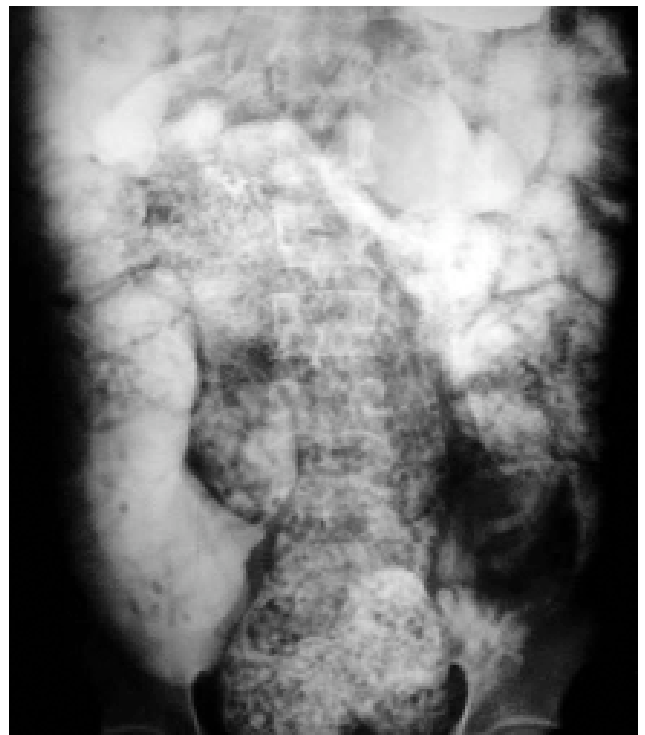

Fig. 3. Gastrografin follow-through study showing the dye reaching the right colon. The small bowel is loaded with *Ascaris* worms while there are fewer worms in the right colon.

fluid in the peritoneal cavity (Fig. 4). Conservative management for 24 hours was applied. The patient was treated with intravenous fluid, nasogastric tube suction, and antibiotics in the form of metronidazole and piperacillin tazobactam.

Since there was no clinical improvement, a decision for laparotomy was made. Intraoperative reactionary fluid with multiple enlarged mesenteric lymph nodes was seen. The ileum was dilated and full of worms with two necrotic patches. The bowel was not perforated. A longitudinal enterotomy was performed after isolating the terminal ileum from the peritoneal cavity using wet abdominal towels. All worms in the ileum and ascending colon were meticulously extracted by sponge-holding forceps and then manually (Fig. 5). Two containers, 2 liters each, were full of *Ascaris* worms. Resection of 30 cm of the ileum with end to end anastomosis 20 cm proximal to the ileocecal junction was performed in two layers. The peritoneal cavity was thoroughly washed with warm normal saline. The postoperative period was uneventful. The patient received one dose of albendazole (400 mg) on the fifth postoperative day, which was repeated six weeks later. Histopathological examination of the small intestine showed varying degrees of hemorrhagic necrotic ulceration and many *Ascaris* ova. The lymph nodes showed reactive changes.

DISCUSSION

Although most patients with *Ascaris* can be managed medically, serious acute complications that require urgent surgical intervention may develop in some patients. Intestinal obstruction is the commonest surgical complication of ascariasis, especially in children.^[10,11] Obstruction commonly occurs at the terminal ileum although large numbers of worms may exist in the jejunum.^[6] The diagnosis of infection by *Ascaris* is not difficult in endemic areas, but recognition of its complications may not be easy.^[12] The delay in the management of the intestinal obstruction can lead to bowel perforation with spillage of the worms and eggs into the peritoneal cavity.^[3]

Intestinal obstruction may be attributed to: 1) obstruction of the lumen of the small bowel by an entangled bolus of worms, 2) spasmodic contraction of the small bowel on to a mass of worms with effectual obstruction at the ileocecal valve, 3) inflammation and matting of loops of the bowel at the site

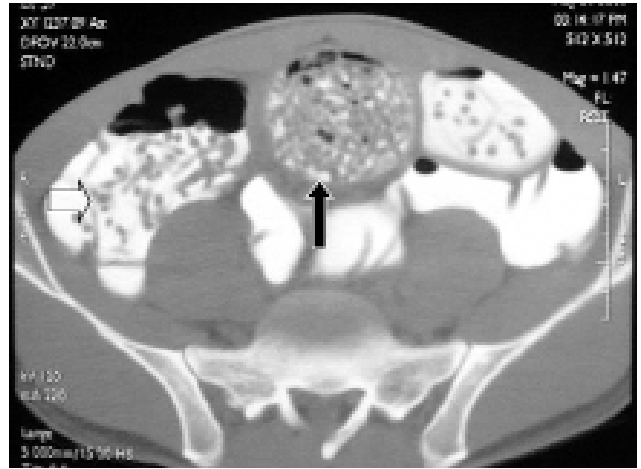


Fig. 4. Abdominal CT scan following the gastrografin study showing the small bowel loaded with *Ascaris* worms (black arrow), while there were fewer worms in the right colon (open arrow). There was no free air in the peritoneal cavity.

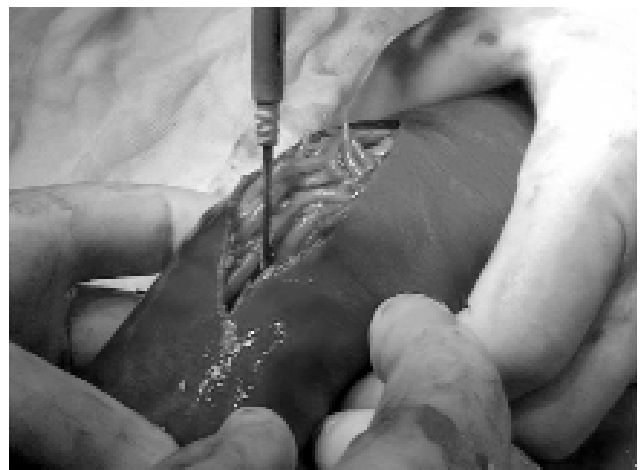

Fig. 5. Longitudinal incision of the ileum after protecting the peritoneal cavity with wet abdominal towels to extract the worms.

occupied by worms, and 4) associated volvulus or intussusceptions.^[13-16]

Patients who present early with a low grade or no fever, slight abdominal distension, and mild diffuse tenderness can be managed conservatively. If patients present late, most of them will look seriously ill and dehydrated, and usually have a high fever. Abdominal examination may reveal signs of peritonitis. Those patients will need urgent laparotomy.^[10]

Hematological and biochemical investigations have no diagnostic significance although they provide a baseline for the perioperative management.^[12]

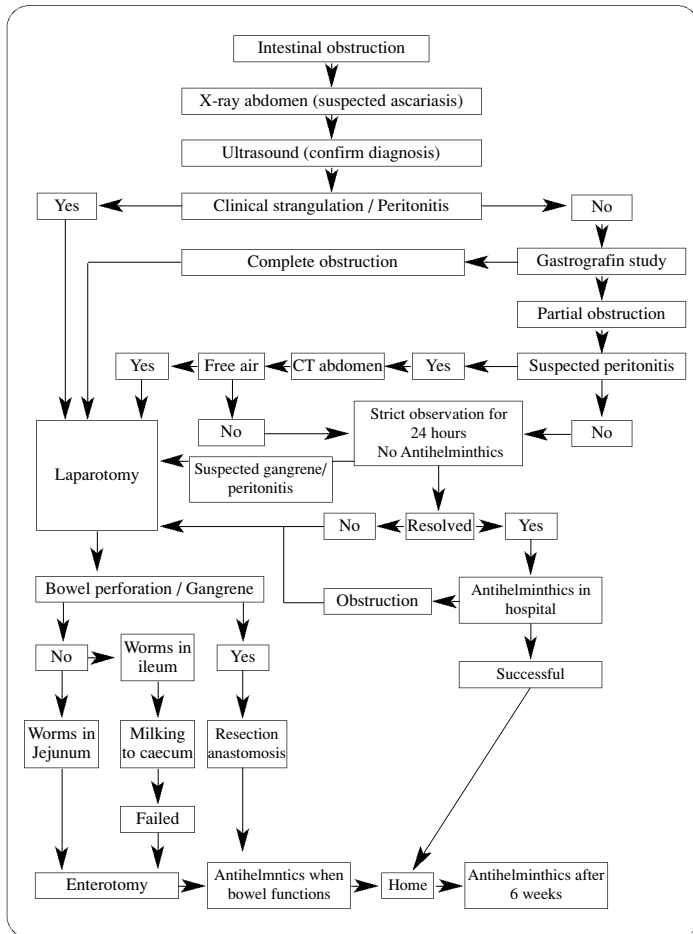


Fig. 6. Management algorithm for intestinal obstruction due to ascariasis.

Plain abdominal radiographs can reveal several loops of moderately distended small bowel loops, evidence of multiple air-fluid levels, and shadows of round worms. Ultrasound confirms the diagnosis by the presence of the typical signs of ascariasis (bull's eyes in transverse section and railway appearance in longitudinal sections).^[17,18] Ultrasound scan is an important diagnostic tool in adult pregnant female patients who are more susceptible to heavy worm load, especially in patients with pica.^[19]

Gastrografin is used to diagnose complete intestinal obstruction as well as to relieve the partial obstruction caused by ascariasis. Being a hyperosmolar agent, it drags fluid to the intestinal lumen. This excess fluid in the vicinity around the worms probably separates them from each other. It also makes the worms more slippery, enabling them to pass beyond the region of obstruction, and it may also be swallowed by the worms, causing their dehydration and shrinkage.^[20-22] In suspected cases of

bowel perforation, abdomen CT scan detects free intraperitoneal air. We adopted the conservative management for 24 hours in our patient, who had partial intestinal obstruction with no intraperitoneal free air.

Figure 6 shows the management algorithm that summarizes the literature. Close monitoring and observation of the patient for the development of complications are essential. The conservative management includes: resuscitation with adequate fluid and electrolyte replacement to overcome the dehydration, nasogastric aspiration for decompression and to relieve distension or vomiting, and antibiotic coverage with analgesics.^[23] No antihelminthic should be given at this stage, as it may worsen the obstruction by increasing the size of the worm's bolus. Hypertonic saline enema has been recommended by some authors.^[24]

Most of the patients will respond to the conservative management. In such patients, antihelminthic drug should be given in the hospital. If it is successful with no more obstruction, the patient can be safely discharged home. The dose of antihelminthic drug has to be repeated six weeks later to eradicate any worms that might have been in the larva phase at the time of admission.^[22]

Some authors advise reevaluating patients undergoing conservative management radiographically after 12 hours in an attempt to recognize the pre-ischemic volvulus or intussusception that may develop during this period.^[12]

Surgical intervention should be considered in: 1) intestinal obstruction showing signs of strangulation, perforation, or peritonitis, 2) complete intestinal obstruction as shown in gastrografin follow-through study, 3) presence of intraperitoneal free air detected by abdominal CT scan, 4) suspected peritonitis or bowel gangrene during the period of observation, 5) unresolved partial intestinal obstruction after 24 hours of conservative management, and 6) complete intestinal obstruction developing after administration of antihelminthic drugs.

The type of surgery elected depends on the findings on laparotomy. If the bowel was found to be viable and the obstruction was at the level of the ileum, milking of worms to the cecum can be attempted carefully without causing trauma to the

bowel wall.^[14] If this was not possible or the obstruction was at the level of the jejunum, enterotomy can be carried out through a longitudinal incision with removal of the worms by sponge-holding forceps. The incision should be closed transversally with great care to avoid contamination of the peritoneal cavity by the worms or eggs.^[22,25]

In cases presenting with bowel gangrene, perforation, or intussusception with compromised bowel, resection with primary anastomosis may be needed. It is rarely necessary to need stomas.

After surgical treatment, the antihelminthic drugs can be given 3-5 days postoperatively after initiation of bowel movement and should be repeated after six weeks.^[6]

In conclusion, intestinal obstruction due to ascariasis is a serious disease with a high morbidity and mortality, especially postoperatively. A clear management algorithm to manage this disease was developed and presented in this report. This algorithm may prove to be of a great value for physicians who treat such cases.

REFERENCES

1. Steinberg R, Davies J, Millar AJ, Brown RA, Rode H. Unusual intestinal sequelae after operations for *Ascaris lumbricoides* infestation. *Pediatr Surg Int* 2003;19:85-7.
2. Ochoa B. Surgical complications of ascariasis. *World J Surg* 1991;15:222-7.
3. Mokoena T, Luvuno FM. Conservative management of intestinal obstruction due to *Ascaris* worms in adult patients: a preliminary report. *J R Coll Surg Edinb* 1988;33:318-21.
4. Thein-Hlaing. A profile of ascariasis morbidity in Rangoon Children's Hospital, Burma. *J Trop Med Hyg* 1987;90:165-9.
5. Ghawss MI, Willan PL. Subacute non-bolus intestinal obstruction caused by *Ascaris lumbricoides*. *Br J Clin Pract* 1990;44:243-4.
6. Louw JH. Abdominal complications of *Ascaris lumbricoides* infestation in children. *Br J Surg* 1966;53:510-21.
7. de Silva NR, Guyatt HL, Bundy DA. Morbidity and mortality due to *Ascaris*-induced intestinal obstruction. *Trans R Soc Trop Med Hyg* 1997;91:31-6.
8. Adesunkanmi AR, Agbakwuru EA. Changing pattern of acute intestinal obstruction in a tropical African population. *East Afr Med J* 1996;73:727-31.
9. Wasadikar PP, Kulkarni AB. Intestinal obstruction due to ascariasis. *Br J Surg* 1997;84:410-2.
10. Coşkun A, Özcan N, Durak AC, Tolu I, Güleç M, Turan C. Intestinal ascariasis as a cause of bowel obstruction in two patients: sonographic diagnosis. *J Clin Ultrasound* 1996;24:326-8.
11. Villamizar E, Méndez M, Bonilla E, Varon H, de Onatra S. *Ascaris lumbricoides* infestation as a cause of intestinal obstruction in children: experience with 87 cases. *J Pediatr Surg* 1996;31:201-4; discussion 204-5.
12. Archibong AE, Ndoma-Egba R, Asindi AA. Intestinal obstruction in southeastern Nigerian children. *East Afr Med J* 1994;71:286-9.
13. Wynne JM, Ellman BA. Bolus obstruction by *Ascaris lumbricoides*. *S Afr Med J* 1983;63:644-6.
14. Khuroo MS. Ascariasis. *Gastroenterol Clin North Am* 1996;25:553-77.
15. Akgun Y. Intestinal obstruction caused by *Ascaris lumbricoides*. *Dis Colon Rectum* 1996;39:1159-63.
16. Warren KS, Mahmoud AA. Algorithms in the diagnosis and management of exotic diseases. xxii. ascariasis and toxocarasis. *J Infect Dis* 1977;135:868-72.
17. Chawla A, Patwardhan V, Maheshwari M, Wasnik A. Primary ascariidial perforation of the small intestine: sonographic diagnosis. *J Clin Ultrasound* 2003;31:211-3.
18. Thein-Hlaing, Myat-Lay-Kyin, Hlaing-Mya, Maung-Maung. Role of ascariasis in surgical abdominal emergencies in the Rangoon Children's Hospital, Burma. *Ann Trop Paediatr* 1990;10:53-60.
19. Mukhopadhyay B, Saha S, Maiti S, Mitra D, Banerjee TJ, Jha M, et al. Clinical appraisal of *Ascaris lumbricoides*, with special reference to surgical complications. *Pediatr Surg Int* 2001;17:403-5.
20. Katz Y, Varsano D, Siegal B, Bar-Yochai A. Intestinal obstruction due to *Ascaris lumbricoides* mimicking intussusception. *Dis Colon Rectum* 1985;28:267-9.
21. Abbas SM, Bissett IP, Parry BR. Meta-analysis of oral water-soluble contrast agent in the management of adhesive small bowel obstruction. *Br J Surg* 2007;94:404-11.
22. Mahmood T, Mansoor N, Quraishy S, Ilyas M, Hussain S. Ultrasonographic appearance of *Ascaris lumbricoides* in the small bowel. *J Ultrasound Med* 2001;20:269-74.
23. Bar-Maor JA, de Carvalho JL, Chappell J. Gastrografin treatment of intestinal obstruction due to *Ascaris lumbricoides*. *J Pediatr Surg* 1984;19:174-6.
24. Wiersma R, Hadley GP. Small bowel volvulus complicating intestinal ascariasis in children. *Br J Surg* 1988;75:86-7.
25. Soomro MA, Akhtar J. Non-operative management of intestinal obstruction due to *ascaris lumbricoides*. *J Coll Physicians Surg Pak* 2003;13:86-9.