

# Acute tracheobronchial injuries: early and late term outcomes

## Akut trakeobronşiyal yaralanmalar: Erken ve geç dönem sonuçlar

Levent DERTSİZ,<sup>1</sup> Gülbin ARICI,<sup>2</sup> Gökhan ARSLAN,<sup>3</sup> Abid DEMİRCAN<sup>1</sup>

### BACKGROUND

To evaluate the early and long-term outcomes of acute tracheobronchial injuries (TBI).

### METHODS

Twelve patients (10 males, 2 females; mean age 28; range 10 to 65 years) diagnosed as tracheobronchial injury and managed during between December 1997 and December 2004 were evaluated retrospectively. Clinical presentation, diagnostic evaluation, associated traumas, surgical management and outcome were reviewed. Follow-up ranged from 1 to 7 years.

### RESULTS

All patients underwent surgical debridement and primary repair (anastomosis). There were three tracheal, eight bronchial and one laryngotracheal injury. Accompanying simultaneous traumas were treated at the same session in all cases. One case was discharged from the hospital with permanent tracheostomy. Control bronchoscopies were performed one week and one month after the surgical repair. Bronchiectasia developed in one case after five years and left lower lobectomy was performed. One case died 23rd day after the primary repair. In the remaining ten cases no complication was determined.

### CONCLUSION

In all cases with a suspicion of TBI, bronchoscopy should be performed immediately by specialist physicians. Early recognition of tracheobronchial injury and expedient institution of appropriate surgical intervention are lifesaving in these potentially lethal injuries. Concomitant injuries are the most important mortality factor.

**Key Words:** Bronchi/injuries/surgery; bronchoscopy; trachea/injuries/surgery.

### AMAÇ

Akut trakeobronşiyal yaralanmaların erken ve geç dönem sonuçları değerlendirmektir.

### GEREÇ VE YÖNTEM

Aralık 1997 ve Aralık 2004 tarihleri arasındaki yedi yıllık sürede akut trakeobronşiyal yaralanma tanısını alan ve tedavi edilen 12 hasta (10 erkek, 2 kadın; ort. yaş 28; dağılım 10-65 yaş) geriye dönük olarak incelendi. Klinik değerlendirme, tanı, eş zamanlı travmalar, cerrahi tedavi ve sonuçlar 1 ile 7 yıllık sürede değerlendirildi.

### BULGULAR

Hastaların tamamına cerrahi debridman ve primer anastomoz uygulandı. Lezyonlar olguların birinde larengotrakeal, üçünde trakeal ve sekizinde bronşiyal sistemde idi. Eş zamanlı travmalar aynı seansta tedavi edildi. Kontrol bronkoskopileri ameliyattan sonra bir hafta ile bir ay sonra yapıldı. Bir olgu kalıcı trakeostomi ile taburcu edildi. Beş yıl sonra sol alt akciğer lobunda bronşektazi saptanan olguya lobektomi yapıldı. Bir olgu yapılan primer tamirden sonraki 23. gün kaybedildi. Diğer 10 olguda herhangi bir sorun saptanmadı.

### SONUÇ

Trakeobronşiyal yaralanma şüphesi olan tüm olgularda uzman hekimler tarafından vakit geçirilmeden bronkoskopi yapılmalıdır. Erken tanı ve uygun cerrahi yolla onarım potansiyel olarak ölümcül olan bu olgularda hayat kurtarıcıdır. Eş zamanlı yaralanmalar mortaliteyi etkileyen en önemli faktördür.

**Anahtar Sözcükler:** Bronş/yaralanmalar/cerrahi; bronkoskopi; trakea/yaralanmalar/cerrahi.

Departments of <sup>1</sup>Thoracic Surgery, <sup>2</sup>Anesthesiology and Reanimation, <sup>3</sup>Radiology, Medicine Faculty of Akdeniz University, Antalya, Turkey.

Akdeniz Üniversitesi Tıp Fakültesi <sup>1</sup>Göğüs Cerrahisi Anabilim Dalı, <sup>2</sup>Anesteziyoloji ve Reanimasyon Anabilim Dalı, <sup>3</sup>Radyoloji Anabilim Dalı, Antalya.

Tracheobronchial injuries (TBI) are relatively uncommon serious and fatal traumas. Few data are available on the long-term effects of their treatment. Twenty-five percent of all blunt traumas are thoracic traumas.<sup>[1]</sup> The vast majority of the patients die before they reach to the hospital and thereby the actual incidence of TBI is not precisely determined.<sup>[2]</sup> TBI necessitates early diagnosis and immediate treatment. Unfortunately, the diagnosis can not be made in some instances within weeks, months or even years which may end up with many complicated cases accompanied with scars and fibrotic surroundings around the original wound. Additionally, some problems can also be faced after treatment (stenosis, bronchiectasia, etc).<sup>[3]</sup> Therefore, TBI present a challenge to the surgeon not only preoperatively but also postoperatively because of its etiologic differences, wound locations, surgical and technical variations, tissue responses and healing issues.

In the present study, we aimed to survey our experience in such cases with different etiologies along with different approaches for the various wound types and discuss the outcomes in correlation with management types.

## PATIENTS AND METHODS

A total of 1.456 patients were admitted to our institution with a trauma diagnosis between December 1997 and December 2004. We retrospectively evaluated the medical charts of twelve patients (10 males, 2 females; mean age 28; range 10 to 65 years), who were diagnosed and managed in our department during a seven-year period, (between December 1997 and December 2004). Nine patients had blunt trauma (75%) and three patients had penetrating thoracic trauma (25%). Etiologic factors were traffic accident in seven cases, penetrating knife wounds in three cases, falling down in one case and traction injury in one case. All cases reached the hospital alive and underwent surgical debridement and primary repair. Since no autopsy carried out routinely in our country we did not include TBI patients who died in the emergency room or before they reached to emergency room due to serious trauma. A bronchoscopically detected rupture of the trachea or bronchus was the main indication for surgery, as well as observing massive and permanent air leaks from the tube or injury site and acute respiratory distress after the trauma indicating airway rupture.

Rigid bronchoscopy was used for diagnosis in all cases. All cases were evaluated by flexible bronchoscopy at the postoperative 7th day and one month later. All bronchoscopies were performed by specialist physicians at the operating room. Diagnostic methods, treatment modalities, outcomes along with preoperative, perioperative and postoperative findings of the patients were reviewed and discussed in the guidance of a literature survey.

## RESULTS

Main symptoms were dyspnea (100%), chest pain (75%), hemoptysis (83%), sternal tenderness (83%), Hamman's sign (66%), and subcutaneous emphysema (83%) (Table 1). Moreover, persistent pneumothorax (75%), rib fracture (75%), pneumomediastinum (83%), pulmonary contusion (58%), hemothorax (50%), and clavicle fracture (25%) were the most frequently encountered findings in radiological examination (Table 1). Additionally, all cases had associated traumas (Table 2) but no cervical spine trauma was detected. All of the right main bronchial injuries were complete rupture in the chest X-ray and an appearance of 'drop lung' was present (Fig. 1a, b). There was incomplete rupture at the cartilage section in the other cases. Locations of TBI were detected and if required double lumen endotracheal tube (DLET) was placed under one lung anesthesia at the same session. Diagnoses were made with bronchoscopy in nine cases and with physical examination in three. Cervical approach and posterolateral thoracotomy (PLT) was performed in four cases and eight cases, respectively. Injury localization sites were trachea in three cases, laryngotracheal region in one case, right main bronchus in five cases and left main bronchus in three cases (Table 2). Cervical approach and PLT were performed in four and eight patients respectively. Bronchial ends were debrided and end-to-end anastomoses were performed by using telescoping or interrupted stitches technique with absorbable suture materials. Polyglactin 2:0 and 3:0 (Vicryl, Ethicon Ltd, UK) were used for trachea and bronchus, retrospectively (Fig. 2). Anastomosis was tested for air leakage, with airway pressures up to 40 cm H<sub>2</sub>O. A pleural pedicle was harvested and wrapped around the main bronchial anastomosis. DLET was replaced with one lumen endotracheal tube just before the transfer of the patient to intensive care unit. Associated traumas were also treated

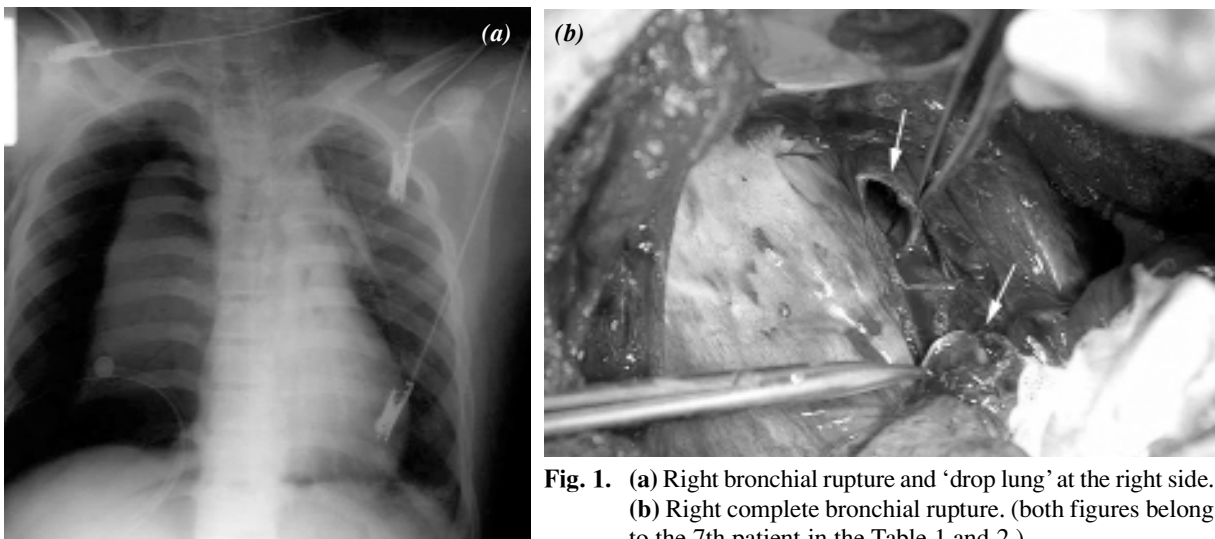
**Table 1.** Percentage of initial symptoms and chest X-ray findings in 12 patients

No	1	2	3	4	5	6	7	8	9	10	11	12
Initial symptoms												
Dyspnea	+	+	+	+	+	+	+	+	+	+	+	+
Chest pain	+	+	+	+	-	-	+	+	+	-	+	+
Sternal tenderness	+	+	+	+	+	+	+	-	+	-	+	+
Hemoptysis	-	+	+	+	-	+	+	+	+	+	+	+
Hamman's sign	+	-	+	+	+	-	+	+	-	-	+	+
Subcutaneous emphysema	+	-	+	+	-	+	+	+	+	+	+	+
Chest X-ray findings												
Pneumothorax	+	+	+	+	-	-	+	+	+	-	+	+
Rib fracture(s)	+	+	+	+	-	-	+	+	+	-	+	+
Clavicle fracture	-	-	-	-	-	-	+	+	-	-	-	+
Pneumomediastinum	-	-	+	+	+	+	+	+	+	+	+	+
Hemothorax	-	+	-	+	-	-	+	+	+	-	+	-
Pulmonary contusion	-	+	+	+	-	-	+	+	-	-	+	+

simultaneously (Table 2). External fixation was used for pelvic and humerus fractures in the 1st and 8th cases, respectively. Thyroid, gastric fundus (by laparotomy), and right radial artery were repaired in the 6th case. We extubated the patients whenever the patients' haemodynamic parameters were appropriate.

Control bronchoscopies (flexible) were performed under general anesthesia one week and one month after the first operation. Total hospital stay ranged from 8 to 23 days (average 14 days) (Table

2). The endotracheal tube was used as an airway support for 1 to 4 days (average 1.4 day) (Table 2). Intensive care unit stay ranged from 3 to 12 days (average 3.7 days) (Table 2). In the control bronchoscopy, the minimal anastomotic stenosis was detected in the first case. Moreover, left lower lobe bronchiectasia was detected at the repair side of this case five years postoperatively and left lower lobectomy was performed (Fig. 3). That case is still in follow up uneventfully. The fifth case, who had laryngotracheoplasty for laryngotracheal rupture due to traction injury previously underwent permanent tra-



**Fig. 1.** (a) Right bronchial rupture and 'drop lung' at the right side. (b) Right complete bronchial rupture. (both figures belong to the 7th patient in the Table 1 and 2.)

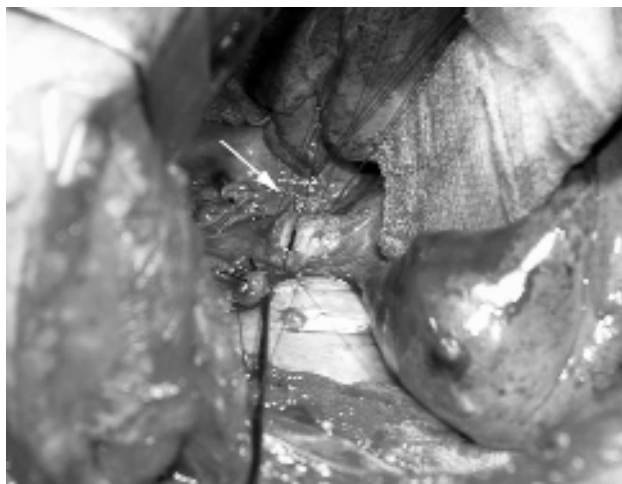**Table 2.** Patient characteristics of tracheobronchial injuries

No	Age/Sex	Etiology	Injury localization	Concomitant traumas	TBTO (hour)	Surgical intervention	Intubation time (days)	Intensive care unit time (days)	Hospital stay (days)	Outcomes
1	18/F	Blunt	LMB	Pelvic and RF, PC	36	PR	1	2	15	BS+BE (LLL)
2	40/F	Blunt	IB	PC, RF	40	PR	1	2	16	Good
3	41/M	Penetrating	T	PC, RF	5	PR	3	12	23	Good
4	22/M	Blunt	RMB	PC, RF	2	SR+PR	1	3	11	Good
5	10/M	Blunt	L, T	Laryngeal injury	6	PR	4	4	21	LS (TR)
6	65/M	Penetrating	T	Thyroid, gastric and radial artery injury	3	PR	1	5	8	Good
7	15/M	Blunt	RMB	RF, PC, CL clavicle fracture	3	SR+PR	1	3	12	Good
8	25/M	Blunt	LMB	Rib fractures, Humerus fracture	3	SR+PR	1	2	9	Good
9	23/M	Blunt	RMB	Pelvic and RF	4	SR+PR	1	2	10	Good
10	25/M	Penetrating	T	Thyroid injury	2	PR	1	1	8	Good
11	20/M	Blunt	RMB	RF and CL clavicle fracture	4	SR+PR	1	2	11	Good
12	32/M	Blunt	LMB	RF, liver injury	72	SR+PR	1	5	23	Exitus

M: Male; F: Female; LMB: Left main bronchus; IB: Intermediate bronchus; T: Trachea; RMB: Right main bronchus; L: Larynx; CL: Contralateral; SR: Stump revision; PR: Primary repair; TBTO: Time between trauma and operation; BS: Bronchostenosis; BE: Bronchiectasia; LLL: Left lower lobectomy; LS: Laryngostenosis; TR: Tracheostomy.

cheostomy two weeks after the first operation because of bilateral vocal cords paralysis diagnosis using laryngobronchoscopy. In that case laryngeal granulation tissues were detected in subsequent bronchoscopies. That case is also in follow up uneventfully.

The 12th case was diagnosed as having blunt thorax trauma in the left side and abdominal trauma because of traffic accident in another medical center and was operated for primary suturing of the liver

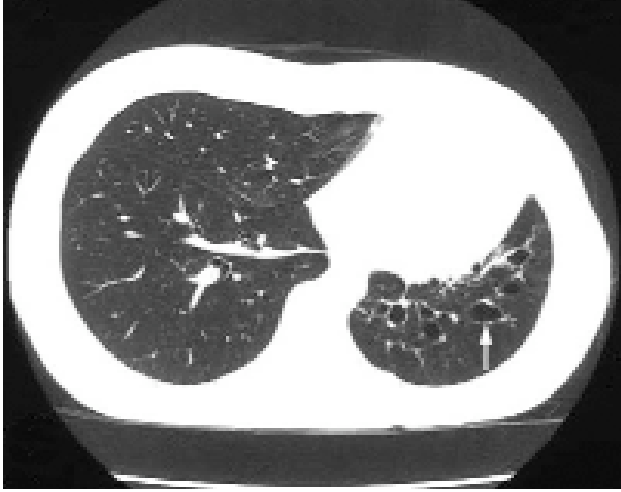

**Fig. 2.** Bronchial anastomosis were made with absorbable suture material. (7th patient)

due to liver laceration and was treated for chest tube drainage of left hemithorax in the same center. However, this case had been transferred to our center on the 3rd day because of a persistent massive air leak and worsening of haemodynamic parameters. The case was diagnosed as having incomplete rupture in the cartilaginous section of left main bronchus using bronchoscopy (Fig. 4) and operated for stump revision with PLT and for end-to-end bronchus anastomoses. Persistent air leak and empyema were detected in this case on the postoperative 4th day and died on the postoperative 23rd day due to multi-organ failure. The results of the patients diagnosed and operated earlier are better than the 1st and 12th patients who had delayed diagnosis and operation (Table 2). All cases are under follow-up between one to seven years uneventfully (Table 2). Thus, pleasing improvements in the bronchoscopic findings were observed in the cases diagnosed and operated earlier during postoperative period. No steroid was used in the cases during either preoperative or postoperative period due to the side effects of this agent on anastomotic healing.

## DISCUSSION

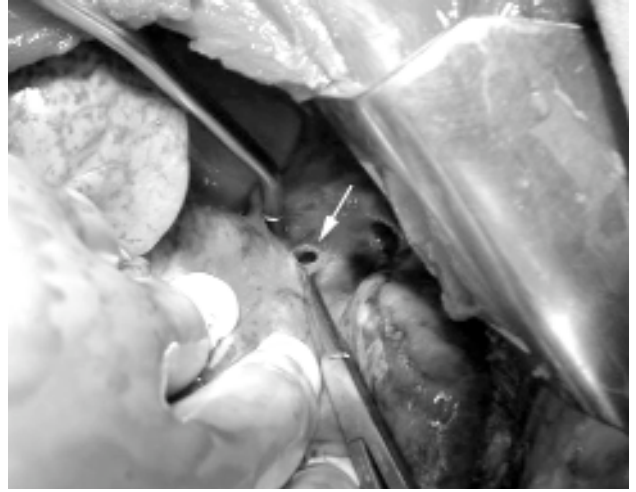
TBI cases are rare but potentially fatal traumas. Since some patients die before reaching to the hospital, the actual incidence of TBI could not be well-determined.<sup>[2]</sup> In a postmortem study of 1.178 trauma



**Fig. 3.** CT scan of the 1st patient five years later (left lower lobe bronchiectasia).

patients, Bertelsen et al.<sup>[4]</sup> reported only 33 patients with TBI and they described that 27 of these patients died immediately. Although most of the cases present a dramatic life threatening clinic course, some cases may run a much more benign course with minimal symptoms.<sup>[5]</sup> In our series the 1st, 5th and 12th cases were admitted to the emergency room in critical conditions; the remaining cases were generally in a better condition on admission.

The pathogenesis of blunt tracheobronchial rupture can be divided into three mechanisms. First, a decrease in the anteroposterior diameter of the thorax occurs with widening of the transverse diameter. The lungs remain in contact with the chest wall and thus are pulled apart, creating traction at the carina. If this force exceeds the elasticity of the tracheobronchial tree, TBI occurs. Secondly, when the trachea and major bronchi are crushed between the sternum and vertebral column with the closing of the glottis a sudden increase is produced in intraabdominal pressure. The sudden increase in pressure is greatest in the larger bronchi and rupture may occur. Thirdly, rapid deceleration may result in shearing forces at the areas of fixation, namely the carina and cricoid cartilage.<sup>[6]</sup> Rupture is generally a single and transverse lesion and it is more frequently located in the right main bronchus since it is less flexible.<sup>[7,8]</sup> In addition, the left bronchus is better protected by the adjacent structures. In our series all cases had a single rupture and the rupture was in right side in five and left in three cases.



**Fig. 4.** Left partial bronchial rupture. Three days later after the trauma. (12th patient)

The first successful primary repair of a bronchial rupture caused by blunt trauma was reported in 1947 by Kinsella and Johnsrud.<sup>[9]</sup> Hood et al.,<sup>[10]</sup> reported significantly better results with prompt primary repair of these injuries. Since then, several series have demonstrated that early diagnosis and primary repair of these injuries lead to fewer complications and best long-term results.<sup>[2,6,11-14]</sup> In the present study, clinical findings were pleasing except for 1st and 12th cases that were diagnosed late and 5th case that was diagnosed with laryngotracheal rupture. TBI may present as a partial or complete rupture. In complete ruptures, healing of the proximal and distal re-epithelization can occur with the development of granulation tissue within 3-7 days.<sup>[15,16]</sup> Thus, this finding suggests that bronchoscopy should be performed for all suspicious trauma cases. Other kinds of rupture are longitudinal and complex rupture and the presence of additional pulmonary and vascular injuries.<sup>[17]</sup> All ruptures in our cases were transverse without any vascular injuries.

Symptoms and signs resulting from rupture commonly include dyspnea, subcutaneous emphysema, mild hemoptysis and pneumothorax or hemothorax. Placement of a chest tube may lead to worsening of the dyspnea secondary to siphoning of the inspired air through the rupture and the chest tubes. Pneumomediastinum and cervical emphysema are the most sensitive chest X-ray markers for airway rupture.<sup>[17-19]</sup> These findings (in our series, 83% and 83%, retrospectively) without pneumotho-

rax are more commonly associated with a tracheal rupture (for example in the 3rd and 6th patients). Whereas a bronchial rupture is usually accompanied by an ipsilateral pneumothorax in addition to the pneumomediastinum. Complete rupture of the main bronchus may be associated with a drop in the affected lung relative to the hilum.<sup>[18]</sup> In our series, all of right main bronchial injuries were complete rupture and an appearance of 'drop lung' was present in the chest X-ray studies (Fig. 1a).

Tracheobronchial ruptures can be repaired by using conventional surgical techniques. Repair of rupture of the cervical trachea is performed through a transverse cervical incision. A thoracic tracheal or right bronchial rupture is managed through the right thoracotomy (fourth intercostal space) and a left bronchial injury is managed through a left thoracotomy.<sup>[20]</sup> After the anastomosis, a pleural pedicle, muscle, pericardial or omental flap may be used to bolster the repair. We wrapped the pleural pedicle around the main bronchial anastomosis. Therefore, these results suggest to place a pleural pedicle around the anastomosis to obtain better improvement.

Anesthetic management of the ruptured airway can be difficult and hazardous. Bronchoscopy remains the gold standard of diagnosis and should be done in all instances of suspected rupture of the airways to prevent the mortality and morbidity associated with these injuries. The bronchoscopy should be done in the operating room fully equipped to carry out the repair of the injury, as necessary.<sup>[20]</sup> In our series only the 1st and 2nd cases were diagnosed in the second day and 12th case in third day (Table 2). Third, 6th and 10th cases were diagnosed with physical examination and the other patients who had strong evidence of TBI were diagnosed by using bronchoscopy in the operating room. Although flexible bronchoscopy has a wide display area and can provide more detailed examination, we postulate that in these cases it is more suitable to perform rigid bronchoscopy by specialist doctors. This method has two advantages. The first one is that the lumen of flexible endoscope might be occluded frequently by hemorrhage and dense secretions and the examination can be difficult to perform. Secondly, if a TBI is detected a DLET tube can directly insert without any exchange of the instruments. Additionally, occurrence of air leak through injured bronchus can be

prevented. However, the method has two disadvantages. The first one is that rigid bronchoscopy is not always indicated in TBI and also the procedure is not available in all emergency services. It requires skilled and trained and experienced physicians; otherwise the risk of additional damage to the injured airway may increase. Secondly, DLET should be inserted by an experienced anesthesiologist. In most cases of TBI, different strategies for airway management must be employed and tailored according to the individual patient. Airway management during the repair of TBI is extremely crucial so that it constitutes a fundamental part of the treatment. The bronchoscope should not be advanced to the defect. Regarding this issue, Balci et al.<sup>[21]</sup> reported 32 cases with TBI and all cases were diagnosed by using rigid bronchoscopy. The mortality rate was reported as ranging 4-30% previously.<sup>[21-25]</sup> In our study, the mortality rate was found to be 8%. Although the patient number was limited to 12, the rate was consistent with the literature findings. On the other hand, several reasons are likely to change this mortality rate such as major vascular injury and especially esophagus injury that effect negatively postoperative period. Besides, it is very important to have experience in such cases for the thoracic surgeons.

Albeit we did not need to perform CT bronchography, we may also suggest that performing CT bronchography in selected patients (either acutely or in follow up) may play a significant role for the surgeons' decision, especially for the inexperienced surgeons. Airway management during the repair of TBI is so crucial that it constitutes a fundamental part of the treatment. More than ten years we have preferred to use DLET in our department if required with no complications. Moreover, it is strongly suggested that the patients should be extubated immediately after haemodynamic parameters and physiological conditions of the patient are suitable since longer the tube is in greater is the chance of inflammation etc. at the repair site. Previous studies have shown that the use of non-absorbable sutures may result in suture granuloma.<sup>[26]</sup> None of the cases showed suture granuloma since absorbable sutures were used.

In conclusion, TBI is frequently lethal, but when diagnosed early, presents an opportunity for prompt and definitive life-saving treatment. In all suspicious cases with TBI, bronchoscopy has to be performed

by a well-trained specialist physician and if TBI is detected primary repair with appropriate approach should be done urgently. The majority of airway ruptures can be successfully repaired using certain principles of anesthesia and airway saving including DLET tube assistance, immediate surgical intervention and control of associated injuries. Delay in the diagnosis and treatment causes postoperative complications. Primary repair is usually achievable.

## REFERENCES

- Baumgartner F, Sheppard B, de Virgilio C, Esrig B, Harrier D, Nelson RJ, et al. Tracheal and main bronchial disruptions after blunt chest trauma: presentation and management. *Ann Thorac Surg* 1990;50:569-74.
- Ecker RR, Libertini RV, Rea WJ, Sugg WL, Webb WR. Injuries of the trachea and bronchi. *Ann Thorac Surg* 1971;11:289-98.
- Kiser AC, O'Brien SM, Detterbeck FC. Blunt tracheobronchial injuries: treatment and outcomes. *Ann Thorac Surg* 2001;71:2059-65.
- Bertelsen S, Howitz P. Injuries of the trachea and bronchi. *Thorax* 1972;27:188-94.
- Swan KG Jr, Swan BC, Swan KG. Decelerational thoracic injury. *J Trauma* 2001;51:970-4.
- Kirsh MM, Orringer MB, Behrendt DM, Sloan H. Management of tracheobronchial disruption secondary to nonpenetrating trauma. *Ann Thorac Surg* 1976;22:93-101.
- Garay SM, Kamelhar DL. Pathophysiology of trauma-associated respiratory failure (Ch 14). In: Hood RM, Boyd AD, Culliford AT, editors. *Thoracic trauma*. Philadelphia: W.B. Saunders; 1989. p. 323-41.
- Battisella F, Benfield JR. Blunt and penetrating injury of chest wall, pleura and lungs (Ch 64). In: Shields TW, editor. *General thoracic surgery*. Malvern: Williams and Wilkins; 1994. p. 767-83.
- Kinsella TJ, Johnsrud LW. Traumatic rupture of the bronchus. *J Thorac Cardiovasc Surg* 1947;16:571-83.
- Hood RM, Sloan HE. Injuries of the trachea and major bronchi. *J Thorac Cardiovasc Surg* 1959;38:458-80.
- Mills SA, Johnston FR, Hudspeth AS, Breyer RH, Myers RT, Cordell AR. Clinical spectrum of blunt tracheobronchial disruption illustrated by seven cases. *J Thorac Cardiovasc Surg* 1982;84:49-58.
- Jones WS, Mavroudis C, Richardson JD, Gray LA Jr, Howe WR. Management of tracheobronchial disruption resulting from blunt trauma. *Surgery* 1984;95:319-23.
- Grover FL, Ellestad C, Arom KV, Root HD, Cruz AB, Trinkle JK. Diagnosis and management of major tracheobronchial injuries. *Ann Thorac Surg* 1979;28:384-91.
- Burke JF. Early diagnosis of traumatic rupture of the bronchus. *JAMA* 1962;181:682-6.
- Hood MR. Injury to the trachea and major bronchi. In: Hood Mr, Artur BD, Culliford AT, editors. *Thoracic trauma*. Philadelphia: W.B. Saunders Company; 1989. p. 245.
- Lee RB. Traumatic injury of the cervicothoracic trachea and major bronchi. *Chest Surg Clin N Am* 1997;7:285-304.
- Deslauriers J, Beaulieu M, Archambault G, LaForge J, Bernier R. Diagnosis and long-term follow-up of major bronchial disruptions due to nonpenetrating trauma. *Ann Thorac Surg* 1982;33:32-9.
- Roxburgh JC. Rupture of the tracheobronchial tree. *Thorax* 1987;42:681-8.
- Taskinen SO, Salo JA, Halttunen PE, Sovijarvi AR. Tracheobronchial rupture due to blunt chest trauma: a follow-up study. *Ann Thorac Surg* 1989;48:846-9.
- Symbas PN, Justicz AG, Ricketts RR. Rupture of the airways from blunt trauma: treatment of complex injuries. *Ann Thorac Surg* 1992;54:177-83.
- Balci AE, Eren N, Eren S, Ulku R. Surgical treatment of post-traumatic tracheobronchial injuries: 14-year experience. *Eur J Cardiothorac Surg* 2002;22:984-9.
- Ramzy AI, Rodriguez A, Turney SZ. Management of major tracheobronchial ruptures in patients with multiple system trauma. *J Trauma* 1988;28:1353-7.
- Sulek M, Miller RH, Mattox KL. The management of gunshot and stab injuries of the trachea. *Arch Otolaryngol* 1983;109:56-9.
- Sheely CH 2nd, Mattox KL, Beall AC Jr. Management of acute cervical tracheal trauma. *Am J Surg* 1974;128:805-8.
- Flynn AE, Thomas AN, Schecter WP. Acute tracheobronchial injury. *J Trauma* 1989;29:1326-30.
- Gibbons JA, Peniston RL, Raflo CP, Diamond SS, Aaron BL. A comparison of synthetic absorbable suture with synthetic nonabsorbable suture for construction of tracheal anastomoses. *Chest* 1981;79:340-2.