

Secondary intestinal obstruction due to low-grade mucinous cystadenocarcinoma of the appendix

Apandiksin düşük dereceli musinöz kistadenokarsinomuna bağlı gelişen intestinal obstrüksiyon

Orhan BAYRAM, M.D.,¹ Osman KURUKAHVECIOĞLU, M.D.,² Bülent SALMAN, M.D.¹

Appendiceal mucoceles are a group of lesions in which the appendiceal lumen becomes distended with mucus. They may be associated with an unusual form of gelatinous ascites termed pseudomyxoma peritonei. We report herein a 77-year-old male patient with appendiceal mucinous cystadenocarcinoma and pseudomyxoma peritonei, whose initial symptoms were abdominal pain and distension and intestinal obstruction. He had a history of explorative laparotomy for an abdominal mass and ascites 14 months ago at another center. He was suffering from abdominal pain and intestinal obstruction on admission to the emergency service. We performed right colectomy and total resection of the mass which originated from the appendix. Pathologic examination of the specimen showed low-grade mucinous cystadenocarcinoma and pseudomyxoma peritonei. The postoperative period was uneventful.

Key Words: Adenocarcinoma; appendiceal neoplasms; appendix; cystadenocarcinoma; mucocele; pseudomyxoma peritonei.

Apandiks lümeninin mukusla dolması sonucu oluşan lezyona mukosel denir. Bu mukoseller nadiren psödomiksoma peritonei adı verilen jelatinöz bir asitle ilişkili olabilir. Bu yazıda, abdominal ağrı ve distansiyon ve intestinal obstrüksiyon semptomlarıyla başvuran ve musinöz kistadenokarsinom ve psödomiksoma peritonei tanısı konan 77 yaşındaki erkek hasta sunuldu. Hastaya 14 ay önce, abdominal kitle ve asit nedeniyle başka bir merkezde eksploratif laparotomi yapıldığı öğrenildi. Acil servise başvurduğunda hastanın abdominal ağrı ve intestinal obstrüksiyona bağlı şikayetleri vardı. Hastaya sağ kolektomi ve apandiksten kaynaklanan kitle için total eksizyon yapıldı. Cerrahi örneğinin patolojik incelemesi sonucunda musinöz kistadenokarsinom ve psödomiksoma peritonei tanısı kondu. Hasta ameliyat sonrası dönemi sorunsuz geçirdi.

Anahtar Sözcükler: Adenokarsinom; apandiks neoplazmları; apandiks; kistadenokarsinom; mukosel; psödomiksoma peritonei.

Appendiceal mucocele refers to gross enlargement of the appendix due to accumulation of mucoid substance within the lumen. It is a rare lesion, accounting for only 0.2 to 0.3 per cent of 43,000 appendectomies reviewed.^[1,2] Four histological subtypes have been described including retention cyst, mucosal hyperplasia, cystadenoma, and cystadenocarcinoma, with incidences of 18, 20, 52 and 10 per cent, respectively.^[1] The course of the

disease and the prognosis are closely related to these subtypes.

CASE REPORT

A seventy-seven-year-old man presented with diffuse abdominal pain and distension. He had had no bowel movements for the past ten days. His food intake was considerably decreased because of nausea and vomiting after oral feeding. Physical

¹Department of General Surgery, Medicine Faculty of Gazi University;
²Department of General Surgery, Oncology Hospital, both in Ankara, Turkey.

¹Gazi Üniversitesi Tıp Fakültesi Genel Cerrahi Anabilim Dalı;
²Ankara Onkoloji Hastanesi 4. Genel Cerrahi Kliniği, Ankara.

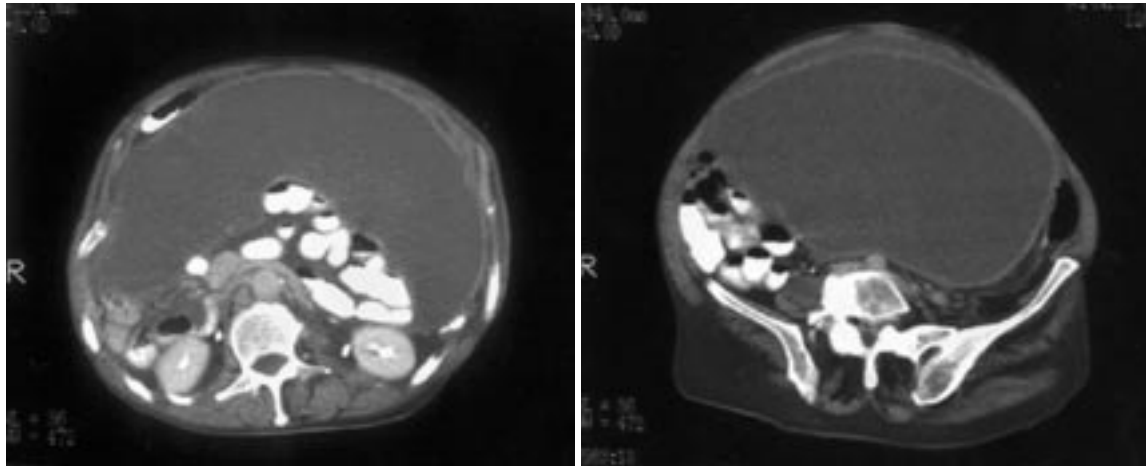


Fig. 1. Abdominopelvic computed tomography scans showing a cystic-colloid lesion. It is thin-walled and the hole is left-sided due to mass effect.

examination findings were as follows: body temperature 37.2 °C, heart rate 88/min, and blood pressure 130/70 mmHg. His abdomen was extremely distended and there were no bowel sounds, both of which suggested an intestinal obstruction. Laboratory parameters were hemoglobin 11.1 g/dl, white blood cell count 9300/mm³, SGOT 16 I/U, SGPT 15 I/U, and CEA 176 ng/ml (0-10 ng/ml). On abdominal X-ray, there was no abnormality such as air-fluid levels. Abdominal computed tomography revealed a thin-walled cystic-colloid lesion measuring 24x19x20 cm. It seemed to cause a secondary intestinal obstruction due to its mass effect (Fig. 1).

The patient had a history of an abdominal operation performed 14 months ago at another center, during which an abdominal mass of unknown origin and ascites were found. However, resection of the mass could not be performed and it was thought

to be peritoneal carcinomatosis. Thereafter, a diagnosis of pseudomyxoma peritonei was made depending on the pathologic examination of the ascites and peritoneal biopsy samples.

The patient underwent laparotomy for intestinal obstruction. During surgery, it was realized that the tumoral mass, about 20 cm in diameter, originated from the appendix (Fig. 2a and 2b). Total *en block* resection with right colectomy and end-to-end ileocolic anastomosis were performed. Pathologic examination of the specimen showed low-grade mucinous cystadenocarcinoma and pseudomyxoma peritonei. The postoperative period was uneventful and the patient was discharged 10 days after surgery without any complaints.

DISCUSSION

The overproduction of mucus and the resulting distension of the appendix may be caused in two

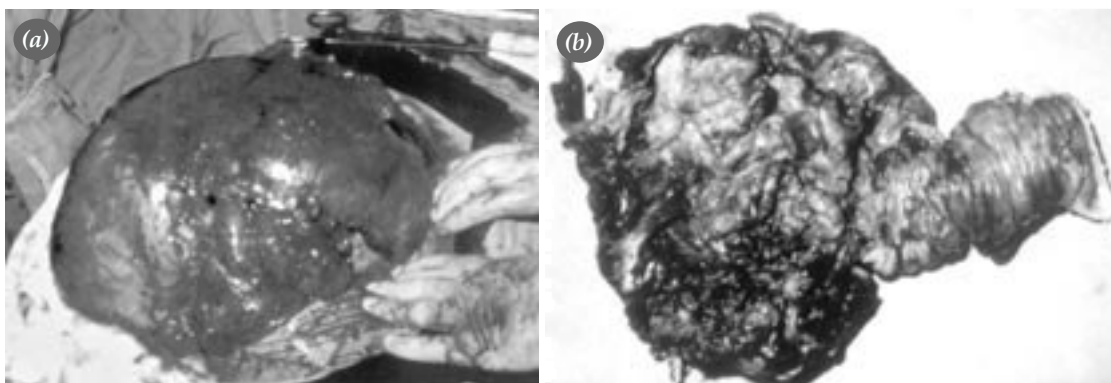


Fig. 2. Intraoperative appearance (a) of the thin-walled cystic-colloid lesion and (b) of the cecal mass originating from the appendix.

ways.^[3] The first and less common mechanism is through luminal obstruction from postinflammatory scarring, leading to the formation of mucoceles that are rarely large and have flattened, atrophic epithelial lining. The latter is due to an epithelial proliferation varying from hyperplasia to cystadenoma or cystadenocarcinoma. This type of mucocele is more common and larger in size.

Pathologically, mucoceles of the appendix can be divided into three groups: simple or retention cysts with normal appendiceal mucosa; cystadenoma with neoplastic epithelium similar to that seen either in adenomatous polyps or in adenocarcinoma of the colon.^[1-4]

Mucinous cystadenomas of the appendix are usually associated with symptoms caused by the distension of the appendix or symptoms related to rupture and subsequent pseudomyxoma peritonei. Pseudomyxoma peritonei is an enigmatic and often fatal intraabdominal disease characterized by dissecting gelatinous ascites and multifocal peritoneal epithelial implants secreting copious globules of extracellular mucin.^[2]

The presentation of appendiceal mucocele is quite variable. In a quarter of patients, it is asymptomatic and discovered incidentally at surgery or during imaging for other symptoms.^[2] When symptomatic, the most common presenting sign is right lower quadrant pain in 64%.^[2] Appendiceal mucoceles may present as acute appendicitis or as an abdominal mass.^[5] Other rare presentations include intestinal intussusception,^[3,6] torsion,^[7] ureteral obstruction, or hematuria.^[8] In our case, the patient presented with intestinal obstruction and the differential diagnosis at presentation included colonic tumor.

In six percent of cases, appendiceal mucoceles may be associated with an unusual form of gelatinous ascites termed pseudomyxoma peritonei. This phenomenon is limited to ascites, containing either isolated or clustered epithelial cells, and excludes acellular ascites, which sometimes accompanies appendiceal mucoceles.^[2] Pseudomyxoma peritonei is a slow, insidious, and often recurring disease. It represents a distinct form of tumoral spread typical of appendiceal cystadenocarcinoma that characteristically do not disseminate through blood or lymphatic vessels.

An accurate diagnosis is important, because some of these lesions are malignant and early iden-

tification may reduce the incidence of pseudomyxoma peritonei.^[3]

Cystadenomas of the appendix are treated by appendectomy that provides a resection line at the base of the appendix, free of tumor. Pseudomyxoma peritonei accompanying a cystadenoma virtually always resolves after surgery.^[3] It is worth noting that there exists a strong association between appendiceal cystadenoma and synchronous and metachronous colorectal adenomas and carcinomas.^[4] Appendectomy is adequate for appendiceal cystadenocarcinomas developing in the distal two-thirds of the appendix, because these tumors never spread to adjacent lymph nodes. However, right colectomy is indicated when the tumor involves the proximal one-third of the appendix or in the presence of adhesions to the terminal part of the ileum or cecum.^[9] Bilateral oophorectomy and resection of the greater omentum should be added in the presence of ovarian involvement. Ovarian cystadenocarcinoma behaves in a similar manner to cystadenocarcinoma of the appendix and is responsible for more than 50 per cent of pseudomyxoma peritonei.^[9] By most authors, associated ovarian cystadenocarcinoma is considered the primary disease, with the appendiceal lesion being a secondary deposit.^[2]

Pseudomyxoma peritonei is characterized by mucinous ascites and mucinous tumor disseminated on peritoneal surfaces; the disease almost always originates from a perforated appendiceal epithelial tumor. It significantly decreases survival of patients with appendiceal cystadenocarcinoma, the reported five-year survival rate being about 25 per cent.^[9] Recently, special treatment modalities such as cytoreductive surgery with peritonectomy procedures combined with perioperative intraperitoneal chemotherapy have resulted in improved long-term survival. These aggressive local regional treatments may be of particular use in pseudomyxoma peritonei.^[10] However, these procedures are associated with a morbidity rate of 27% and mortality rate of 2.7%. Five-year survival rates of complete and incomplete cytoreductive surgery are about 50% and 20%, respectively.^[11] Nevertheless, cytoreductive surgery with perioperative intraperitoneal chemotherapy is the standard treatment for selected patients with appendiceal primary tumors involving peritoneal surfaces.^[10-12]

In conclusion, treatment of pseudomyxoma peritonei remains controversial and difficult. Cytoreductive surgery with intraperitoneal chemotherapy is the treatment of choice for selected patients in several surgery units. In the future, it may prove to be the most appropriate treatment for pseudomyxoma peritonei.

REFERENCES

- Higa E, Rosai J, Pizzimbono CA, Wise L. Mucosal hyperplasia, mucinous cystadenoma, and mucinous cystadenocarcinoma of the appendix. A re-evaluation of appendiceal "mucocele". *Cancer* 1973;32:1525-41.
- Aho AJ, Heinonen R, Lauren P. Benign and malignant mucocele of the appendix. Histological types and prognosis. *Acta Chir Scand* 1973;139:392-400.
- Chetty R, Daniel WJ. Mucinous cystadenoma of the appendix: an unusual cause of recurrent intussusception in an adult. *Aust N Z J Surg* 1992;62:670-1.
- Wolff M, Ahmed N. Epithelial neoplasms of the vermiform appendix (exclusive of carcinoid). II. Cystadenomas, papillary adenomas, and adenomatous polyps of the appendix. *Cancer* 1976;37:2511-22.
- Carr NJ, McCarthy WF, Sobin LH. Epithelial noncarcinoid tumors and tumor-like lesions of the appendix. A clinicopathologic study of 184 patients with a multivariate analysis of prognostic factors. *Cancer* 1995;75:757-68.
- Jones CD, Eller DJ, Coates TL. Mucinous cystadenoma of the appendix causing intussusception in an adult. *Am J Gastroenterol* 1997;92:898-9.
- Abu Zidan FM, al-Hilaly MA, al-Atrabi N. Torsion of a mucocele of the appendix in a pregnant woman. *Acta Obstet Gynecol Scand* 1992;71:140-2.
- Baskin LS, Stoller ML. Unusual appendiceal pathology presenting as urologic disease. *Urology* 1991;38:432-6.
- Landen S, Bertrand C, Maddern GJ, Herman D, Pourbaix A, de Neve A, et al. Appendiceal mucoceles and pseudomyxoma peritonei. *Surg Gynecol Obstet* 1992;175:401-4.
- Ronnett BM, Yan H, Kurman RJ, Shmookler BM, Wu L, Sugarbaker PH. Patients with pseudomyxoma peritonei associated with disseminated peritoneal adenomucinosis have a significantly more favorable prognosis than patients with peritoneal mucinous carcinomatosis. *Cancer* 2001;92:85-91.
- Sugarbaker PH. Cytoreductive surgery and peri-operative intraperitoneal chemotherapy as a curative approach to pseudomyxoma peritonei syndrome. *Eur J Surg Oncol* 2001;27:239-43.
- Yan H, Pestieau SR, Shmookler BM, Sugarbaker PH. Histopathologic analysis in 46 patients with pseudomyxoma peritonei syndrome: failure versus success with a second-look operation. *Mod Pathol* 2001;14:164-71.